

# Manual small incision cataract surgery (MSICS) under topical anesthesia

Bhalchandra S Joshi<sup>1</sup>, V H Karambelkar<sup>2</sup>, Vikrant A Narwade<sup>3\*</sup>

<sup>1</sup>Associate professor, <sup>2</sup>Professor, <sup>3</sup>Resident, Department of Ophthalmology, Krishna Institute Of Medical Sciences, Karad

Email: [drvikrant.narwade@gmail.com](mailto:drvikrant.narwade@gmail.com)

## Abstract

**Introduction:** Manual small incision cataract surgery under topical anesthesia with 0.5% proparacaine hydrochloride and 1% preservative free intracameral lignocaine is a reasonably well tolerated procedure and is absolutely safer alternative to surgery under peribulbar or retrobulbar anesthesia with excellent outcome. **Aim:** To evaluate the patient's and surgeon's experience in MSICS using topical anesthesia with 0.5% proparacaine hydrochloride eye drops and preservative free intracameral 1% lignocaine in terms of pain, surgical complications and outcome.

**Keywords:** Topical anesthesia, 0.5% proparacaine hydrochloride eye drops, 1% preservative free intracameral lignocaine, small incision cataract surgery, pain evaluation.

## \*Address for Correspondence:

Dr. Vikrant A Narwade, Resident, Department of Ophthalmology, Krishna Institute Of Medical Sciences, Karad, Maharashtra, INDIA.

Email: [drvikrant.narwade@gmail.com](mailto:drvikrant.narwade@gmail.com)

Received Date: 22/05/2016 Revised Date: 04/06/2016 Accepted Date: 10/07/2016

## Access this article online

Quick Response Code:



Website:

[www.statperson.com](http://www.statperson.com)

DOI: 09 August  
2016

## INTRODUCTION

Cataract is the main and biggest cause of curable blindness in India and worldwide. In India 3.8 million people developed blinding cataract every year against 2.7 million cataract surgeries done every year, so huge backlog is created<sup>1,2</sup>. Cataract extraction is one of the most cost-effective surgical intervention<sup>3,4</sup>. The only treatment option for cataract is surgical removal of opaque lens and implantation of artificial intraocular lens. Manual small incision cataract surgery (MSICS) has been conventionally performed under peribulbar or retrobulbar anaesthesia. Now there are some reports of procedure being performed under subtenon and subconjunctival anesthesia too<sup>5</sup>. We here describe a topical anesthesia approach for performing manual small incision cataract surgery (MSICS).

## MATERIALS AND METHODS

Inclusion criteria for surgery were 1. impaired visual function with BCVA < 6/18 2. unacceptable glare 3. reduced quality of vision attributed to cataract. patients fulfilling these criteria and willing for cataract surgery were included in the study Clinical records of 60 eyes operated for topical MSICS in last 2 years were retrospectively evaluated. Total 60 eyes were operated (32 males and 28 female) having cataract Grade II – Grade IV including mature cataract. The age range was 40 to 75 years. Preoperatively evaluation were included physician fitness report for surgery, sac syringing and intraocular tension measurement with shiotz tonometry. Diabetic patients were included after control of blood sugar level. **Preoperative medications:** T. ofloxacin 200 mg BD 3 days before surgery and 0.5% moxifloxacin eye drops 4 times per day were started On the day of surgery, pupils were dilated with combination of tropicamide 0.8 % and phenylephrine 5% eye drops and flurbiprofen 0.3% eye drops every 15 minutes. Informed consent was taken. 15 min before surgery 0.5% proparacaine hydrochloride eye drops instilled every 5 min in the eye to be operated. Patients were instructed to look in the center of light of microscope while being on operation table. 5% providone iodine eye drops were instilled in the eye 3-4 minutes before starting the of surgery. At the start of surgery, the patients were instructed to hold the hand of the paramedical staff and to squeeze the hand whenever they felt pain, surgical scale

during which patients felt pain which was recorded accordingly. Pain scores were allocated as follows: 0- no pain, 2- mild annoying pain, 4- moderate, uncomfortable troublesome pain, 6- distressing miserable pain, 8- intense, dreadful, horrible pain and 10- worst possible, unbearable, excruciating pain<sup>6,7</sup>. Following protocol was followed during surgery:

- Painting was done with 5% providine iodine and draping was done with disposable surgical drape
- Self retaining Speculum with screw adjustment was applied
- 6mm Conjunctivalperitomy was done temporally
- Scleral incision of 5.5mm size was taken 1.5 mm away from limbus on temporal side with 1.5mm side cuts on the sclera.
- Sclerocorneal tunnel was made with crescent knife
- Side port entry was made using side port entry blade
- Anterior chamber was filled with 1% preservative free lignocaine.
- Anterior capsular staining was done by 0.6% trypan blue.
- Continuous curvilinear capsulorhexis of 6mm was done
- Hydrodissection followed by rotation of the nucleus in the bag was done. One pole of nucleus was prolapsed in the anterior chamber.
- Anterior chamber was filled with viscoelastic material (2% HPMC). The nucleus was expressed with visco expression
- Remaining cortical matter aspirated using Simcoe cannula with chilled normal saline
- Rigid PMMA 6mm IOL was placed in the capsular bag

Pain score was marked by the patient on a 10 – point Visual analog scale (VAS) pain score after surgery to assess each patient's overall severity of pain. All patients were observed for pain score, intraoperative complications, post operative visual recovery and complications

## OBSERVATIONS

3 (5%) patients had moderate pain score, 20(33%) patients had mild pain, rest all other patients were comfortable.

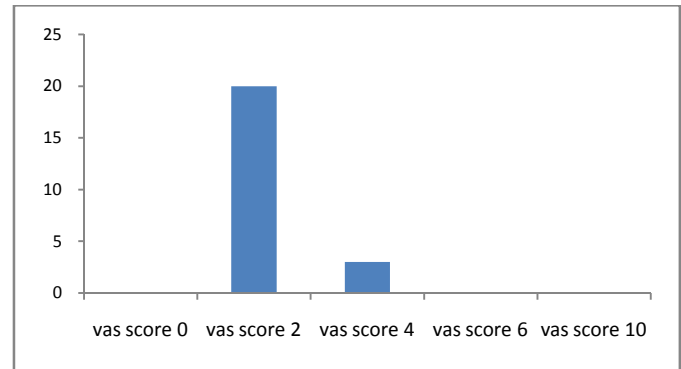


Figure 1: Visual Analogue Scale

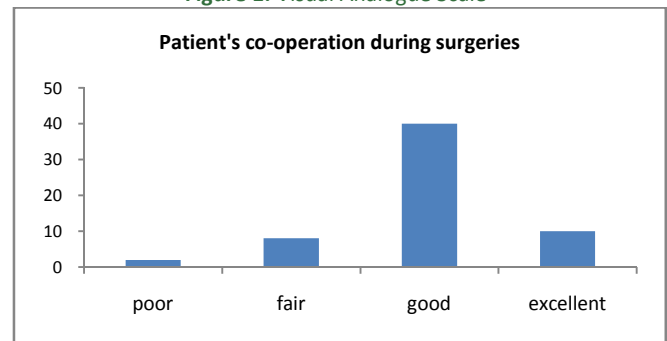


Figure 2: Patient's co-operation during surgeries

**Complications:** 2 patients had premature entry and minimal iris prolapse, 12 patients had mild corneal oedema, 12 patients had conjunctival hematoma and 5 patients had chemosis.

## RESULTS

The surgeries were performed on 60 eyes of 32 males (53.33%) and 28 females (46.66%) from the age group 40 to 75 years (mean age of 55.5 yr with SD +/- 3.37). Using the VAS (Visual analogue scale), with a range of 0-10, 20 patients (33.3%) had a VAS score of 2 representing mild pain, and 3 patients had a VAS score of 4 representing moderate pain. Complications like mild corneal oedema occurred in 12 patients (20%), premature entry in 2 patients (3.33%), minimal iris prolapse in 2 patients (3.33%), post-operative conjunctival hematoma in 12 patients (20%) and chemosis in 5 patients (8.33%).

Table 1:

| Complications            | Number of patients | Percentage |
|--------------------------|--------------------|------------|
| Lid squeezing            | 0                  | 0          |
| Inadvertent eye movement | 2                  | 3.33%      |
| Premature entry          | 2                  | 3.33%      |
| Iris prolapsed           | 2                  | 3.33%      |
| Corneal oedema           | 12                 | 20%        |
| Conjunctival hematoma    | 12                 | 20%        |
| Chemosis                 | 5                  | 8.33%      |

Unaided Visual recovery after one and half month of surgery ranged between 6/6 to 6/12. 50% patients had 6/9

or better, 30% had 6/9-6/12 and remaining patients had 6/12-6/18. Best corrected visual acuity of 54 (90%) patients was 6/6. 4 patients had 6/9 vision and 2 patients had 6/12 vision. Causes of subnormal visual acuity after surgery : 5 patients had age related macular degeneration and 1 patient had diabetic macular oedema which resulted in subnormal visual acuity after surgery as discussed above.

## DISCUSSION

The use of topical anesthesia has been described with the supplemented subconjunctival anesthesia for standard extracapsular cataract extraction with implantation of IOL by Smith way back in 1990<sup>8</sup>. Topical anaesthesia saves the patient from risk of globe perforation, optic nerve injury, possibility of life threatening respiratory arrest. Topical anesthesia has additional benefits like immediate visual recovery, absence of pain due to injection, unlimited ocular motility and absence of an increase in orbital volume. Irrespective of minimal iris prolapse, topical 0.5% proparacaine hydrochloride instillation intraoperatively probably made the procedure well tolerable for the patient. Topically applied 0.5% proparacaine hydrochloride eye drops acts directly on the corneal epithelium and stroma and the portion of drug penetrating into anterior chamber suppresses pain arising from iris and ciliary body. The duration of effect of topically applied anesthetics depends upon the properties of the drug used. Usually, it lasts up to 15-20 min for the commonly used agents, but eye drop instillation or intracameral irrigation can be repeated at intervals during surgery if needed. The advantages of topical anesthesia over periocular injections include are higher safety level and avoidance of pain due to injection before surgery. Better consistency of analgesia can be maintained during surgery by topical and intracameral anaesthetic agents. The procedure offers a safer alternative to MSICS under peribulbar or retrobulbar anesthesia and may be adopted as standard procedure for cataract surgery. Similar findings was observed in Gupta *et al's* series, the use of

intracameral preservative free lignocaine enhanced the anesthesia of intraocular anterior chamber structure<sup>9</sup>. Fichman (1996) has investigated the blood pressure, pulse rate and respiratory rate of patients during surgery under topical anesthesia and found no major changes in these parameters<sup>10</sup>. There is no significant change in plasma cortisol levels during surgery under topical anesthesia, indicating that the procedure is well tolerated and does not pose stress to the patient<sup>11</sup>.

## REFERENCES

1. Minasian DC, Mehera V. 3.8 Million blinded by cataract each year: projection of the first epidemiological study of incidence of cataract blindness in India. *Br J Ophthalmol*. 1990;74:31-3
2. Jose R. National programme for the control of blindness. *Indian J Comm Health*. 1997;3:5-9
3. Marseille E Cost-effectiveness of cataract surgery in public health eye care programme in Nepal. *World Health Organ Bull OMS*. 1996;74:319-24
4. Porter R. Global initiative: The economic case. *Commen Eye Health*. 1998;24:44-5
5. Parkar T, Gogate P, Deshpande M, Adenwala A, Maske A, Verappa K, Comparison of subtenon anesthesia with peribulbar anesthesia for manual small incision cataract surgery. *Indian J Ophthalmol*. 2005;53:255-9
6. Collins SL, Moore RA, McQuary HJ. The visual analogue pain intensity scale: What is moderate pain in millimetres? *Pain*. 1990;72:95-7
7. Lee J, Stiell I, Hobden E, Wells G. Clinically meaningful value of the visual analogue scale of pain severity. *Acad Emerg Med*. 2007;7:550
8. Smith R. Cataract extraction without retrobulbar anesthetic injection. *Br J Ophthalmol*. 1990;74:205-7
9. Gupta SK, Kumar A, Kumar D, Agrawal S, Manual small incision cataract surgery under topical anesthesia with intracameral lignocaine: Study on pain evaluation and surgical outcome. *Indian J Ophthalmology* 2009;57:3-7
10. Fichman RA. Use of topical anesthesia alone in cataract surgery. *J Cataract Refract Surg*. 1996;22:612-4
11. Gozum N, Altan-Yaycioglu R, Gucukoglu A, Arsian O. Does topical anesthesia increase patient's serum cortisol level? *Int J Ophthalmol Visual Sci*. 2003;2:2

Source of Support: None Declared  
Conflict of Interest: None Declared