

# 23 Gauge Transconjunctival Vitrectomy-Short Term Visual Outcomes and Complications

Biju John C.<sup>1</sup>, Apuca Susan Mathew<sup>2</sup>

<sup>1</sup>Associate Professor, Regional Institute of Ophthalmology, Trivandrum 35, Kerala, INDIA.

<sup>2</sup>Professor SMCSI Medical College, Karakonam, Kerala, INDIA.

Corresponding Addresses:

<sup>1</sup>[bijujc@gmail.com](mailto:bijujc@gmail.com), <sup>2</sup>[apucasusan@gmail.com](mailto:apucasusan@gmail.com)

## Research Article

**Abstract: Purpose:** To report the initial experience, complications and short term visual outcomes of patients undergoing 23 Gauge Transconjunctival Pars Plana Vitrectomy. **Methods:** This was a Retrospective non comparative case series evaluating the first 50 consecutive cases of 23 Gauge Transconjunctival Pars Plana Vitrectomy done by a single surgeon in a Tertiary Eye Care centre. The outcome measures included best corrected visual acuity at 6 weeks compared to the Pre Operative Visual acuity, Intraoperative complications and difficulties and Post Operative complications. The relevant information was retrieved from the case records and follow up records of these patients. **Results:** Out of the 50 eyes studied, Visual Acuity at 6 weeks improved in 39 (78%); remained unchanged in 8 (16%) and worsened in 3 (6%). Suturing of at least one of the ports was done in 18 eyes (36%). Intraoperative Retinal breaks occurred in 2 eyes. The Post operative complications noted in the post operative period up to 6 wks were vitreous hemorrhage (8%), cataract formation (6%), post operative uveitis (6%) and retinal redetachment (2%). 1 case had to be converted into a 20 Gauge vitrectomy due to the development of choroidal effusion. **Conclusion:** 23 Gauge Transconjunctival Vitrectomy is an effective surgical technique for a variety of Vitreoretinal surgical indications. The safety and efficacy compared well with that in the published literature.

**Keywords:** 23 gauge; vitrectomy, Transconjunctival, Minimally invasive, pars plana, trocar, cannula, vitreous hemorrhage, retinal detachment, wound leak, retinal breaks, vitreoretinal

## Introduction

Minimally Invasive Transconjunctival Vitrectomy was a quantum leap in the history of Pars Plana Vitrectomy. The 25 gauge systems introduced initially in 2002 by Eugene de Juan, Los Angeles set the ball rolling<sup>(7)</sup>. But the real game changer was the introduction of the 23 Gauge Transconjunctival Trocar Cannula system and the concept of tangential valvular entry of these across the ocular coats into the vitreous cavity by Claus Eckardt in 2004<sup>(7)</sup>. The need for suturing was also obviated in most of the cases especially with the introduction of better and better Trocar Cannula systems. In addition to the considerable decrease in the operating time the other advantages were faster wound healing, diminished conjunctival scarring, improved patient comfort and decreased postoperative inflammation. The trocars also made it easier to find the entry ports during vitrectomy. It

was only natural that in the short span of time since its inception the procedure has evolved quickly and the 23 Gauge Transconjunctival Vitrectomy, also referred to as the Minimally Invasive Vitrectomy Surgery (MIVS) has become the new standard procedure of vitrectomy. There were some problems especially in the learning stage – wound leakage and consequent hypotony, increased risk of choroidal detachment to list a few. In this study we describe our initial experiences with the 23 Gauge Transconjunctival Vitrectomy system focusing mainly on the intraoperative and post operative problems and short term visual outcomes.

## Aims of Study

1. To report the initial experience of 50 consecutive cases of 23 Gauge Transconjunctival Vitrectomy done for various indications in a tertiary Care Centre.
2. To report the complications encountered during the procedure and during the immediate post operative period
3. To report the short term visual outcomes of the surgery.

## Materials and Methods

This was a retrospective non comparative case review of 50 consecutive cases of 23 Gauge Transconjunctival Vitrectomy done by a single surgeon in a tertiary care centre in Kerala. All cases were done in the period from Jan 2013 to May 2013. Information was collected from the case records and the follow up records of the patients after getting the necessary clearance from the Institutional committee. Follow up data collected included that at the 1<sup>st</sup> week and 6 weeks follow up. Detailed work up including Visual Acuity evaluation, Slit lamp examination, Indirect Ophthalmoscopy, Tonometry by applanation, and OCT and FFA when needed were done in the pre operative work up. The chief outcome measure was change in Visual acuity at 6 weeks. Others were complications which included intraoperative complications like Suprachoroidal effusion, Retinal breaks, Hemorrhage and immediate and late post op complications like Hypotony (defined as IOP less than 6

mm HG<sup>(3,4)</sup> ; Uveitis; Corneal Edema; Endophthalmitis; Retinal detachment; Vitreous hemorrhage etc. Immediate wound leak necessitating suture closure of sclerotomies was also noted.

Surgery was routinely performed under peri bulbar anesthesia. The anesthetist monitored all cases with systemic problems. The Accurus vitrectomy machine from Alcon Laboratories along with the 23 gauge Transconjunctival Non Valved Vitrectomy system from the same manufacturer was used for all cases. After preparation, draping, and insertion of a speculum the single step preloaded trocar cannulas were used to create the self-sealing sclerotomies. The conjunctiva was displaced initially with the help of a conjunctival forceps or cotton swab and the sclera was penetrated 3.5 or 4 mm behind the limbus based on whether the patient is phakic or not. The trocar blade with the cannula was advanced tangential to the limbus (about 15 degree from the surface) and parallel to the limbus. This is advanced till the sleeve of the trocar is reached. At this point the trocar is rotated 90 degree so that it is perpendicular to the surface of globe and is inserted into the vitreous cavity fully aiming towards the mid vitreous cavity. Once inserted, the cuff of the cannula was held with a Lim’s forceps and the trocar blade was withdrawn from the eye. The Inferotemporal cannula was first placed like this and the infusion cannula was placed through the same. After making sure that the tip of the cannula is seen in the

vitreous cavity, the same is opened so as to allow balanced salt solution to flow into the vitreous cavity. Following this the other trocar cannulas were inserted in the superonasal and superotemporal quadrants. Core vitrectomy followed by PVD induction and other intravitreal maneuvers as needed as per the indication was done. 23 gauge instruments were used for all other intraocular maneuvers like ILM peeling, membrane removal, membrane dissection, fluid gas exchange, active extrusion, IOL removal, endocautery and endolaser. At the end of the surgery the 2 superior cannulas were removed first. An endoilluminator was placed through the cannula to be removed and the same along with the cannula was removed by reversing the direction of insertion. After removal of each cannula the site was massaged with a cotton bud for some time. The opening was then closely checked for any leakage and in the event of the leakage continuing, a transconjunctival single 6 0 Vicryl suture was used to close the sclerotomy .The infusion cannula is clamped and removed last. Topical antibiotics were applied and the eye patched.

Snellen’s visual acuity was converted into logarithm of the minimum angle of resolution (Logmar) using Jack Holladay’s table<sup>(1)</sup> .When reporting the corresponding Snellen equivalent of the calculated mean logmar visual acuities were found out using the formula  
 Decimal Acuity = Antilog(-Logmar) <sup>(1)</sup>.

**Results**

50 eyes of 50 patients who underwent 23 Gauge Vitrectomy were taken for the study. The age of the patients ranged from 20 to 85 with a mean age of 55 yrs. There were 36 males (72%) and 14 females (28%). Indications for vitrectomy were as follows

**Table 1: Vitrectomy Indications**

Indication group	No: of Cases
Endophthalmitis	3
ERM	1
Mac Hole	3
Nucleus Drop	2
Posteriorly Dislocated IOL	5
PDR vitrectomy	16
RRD	11
Trauma Related	2
Non Resolving Vitreous Hemorrhage due to IPCV	4
Non Resolving Vitreous Hemorrhage due to BRVO	3
<b>Total</b>	<b>50</b>




Chart 1: Vitrectomy Indications

**Visual Outcome Results**

Pre Op Visual Acuity ranged from PL to 6/18 (0.48 logmar). The mean pre op visual acuity was 2.13 log mar units (20/2697<sup>#</sup>). This improved to 0.98 log mar (20/190<sup>#</sup>) 6 wks after vitrectomy. This improvement was found to be statistically significant by the paired t test as is given in Table 2. Two cases were excluded from the calculation as they had pre op vision of only PL which could not be converted to Logmar.<sup>1</sup>

Table 2: Effectiveness of treatment on Mean VA (logmar)

	GM <sup>\$</sup>	SD <sup>+</sup>	N	Mean Difference	Paired t	p
Pre OP	2.13	0.78	48	1.16	8.70**	0.000
Post Op at 3 month	0.98	0.80	48			

\*\* : - Significant at 0.01 level (i.e. P<0.01)

The change in mean visual acuity between pre op and 6wks post op vision for different indications of vitrectomy are given in Table 3 and illustrated in Chart 2. In all these calculations the geometric mean of best corrected visual acuities were taken and not the arithmetic mean since the modern visual acuity charts are all designed in such a way that the letter sizes follow a geometric progression.<sup>(1)</sup> Also all the visual acuities are the best corrected visual acuity.

Table 3: Effectiveness of treatment on VA (logmar) based on Indication group

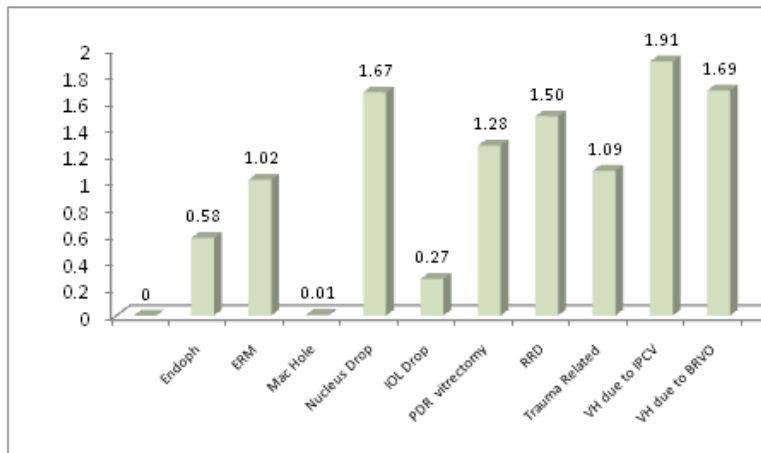
Indication group	Total No: of Cases	Pre Op VA		Post Op VA		Mean Difference	Paired "t"	P value
		Mean Logmar	Snellen Equivalent	Mean Logmar	Snellen Equivalent			
Endophthalmitis	3	2.21	20/3243	1.63	20/853	-0.58	0.14	0.905
ERM	1	1.80	20/1261	0.78	20/120	-1.02	-	-
Mac Hole	3	1.59	20/778	1.58	20/760	-0.01	0.38	0.742
Nucleus Drop	2	2.45	20/5636	0.77	20/117	-1.67	2.43	0.249
<b>Posteriorly Dislocated IOL</b>	<b>5</b>	<b>0.76</b>	<b>20/115</b>	<b>0.48</b>	<b>20/60</b>	<b>-0.27</b>	<b>4.18*</b>	<b>0.014</b>
<b>PDR vitrectomy</b>	<b>16</b>	<b>2.71</b>	<b>20/10257</b>	<b>1.43</b>	<b>20/538</b>	<b>-1.28</b>	<b>5.57**</b>	<b>0.000</b>
<b>RRD</b>	<b>11</b>	<b>2.63</b>	<b>20/8531</b>	<b>1.13</b>	<b>20/270</b>	<b>-1.50</b>	<b>5.99**</b>	<b>0.000</b>
Trauma Related	2	1.41	20/514	0.33	20/43	-1.09	3.83	0.163
<b>Non Resolving Vitreous Hemorrhage due to IPCV</b>	<b>4</b>	<b>2.45</b>	<b>20/5636</b>	<b>0.54</b>	<b>20/69</b>	<b>-1.91</b>	<b>6.46**</b>	<b>0.008</b>
<b>Non Resolving Vitreous Hemorrhage due to BRVO</b>	<b>3</b>	<b>2.29</b>	<b>20/3899</b>	<b>0.60</b>	<b>20/80</b>	<b>-1.69</b>	<b>5.2*</b>	<b>0.035</b>

# Calculated Snellen Equivalent

\$ Geometric Mean

+ Standard Deviation

\*\*:- Significant at 0.01 level (P<0.01); \* Significant at 0.05 level (P <0.05)



**Chart 2:** Absolute Value of Change in Mean Visual Acuity

1 line difference in Snellen Visual Acuity chart is equivalent to 0.1 Logmar Units <sup>(1)</sup>. Thus for all indications except Macular Hole the visual acuity improved by more than 2 Snellen lines. The highest improvement in mean visual acuity was for non resolving vitreous hemorrhage due to non diabetic causes like IPCV and Branch Retinal Vein Occlusion. In the former the change was from 2.45 logmar (20/5636<sup>#</sup>) to 0.54 logmar (20/69<sup>#</sup>) and in the latter it was from 2.29 logmar (20/3899<sup>#</sup>) to 0.60 logmar (20/80<sup>#</sup>). The difference was found to be statistically significant for non resolving vitreous hemorrhage due to BRVO and IPCV, RRD, PDR vitrectomy and Posteriorly Dislocated IOL.

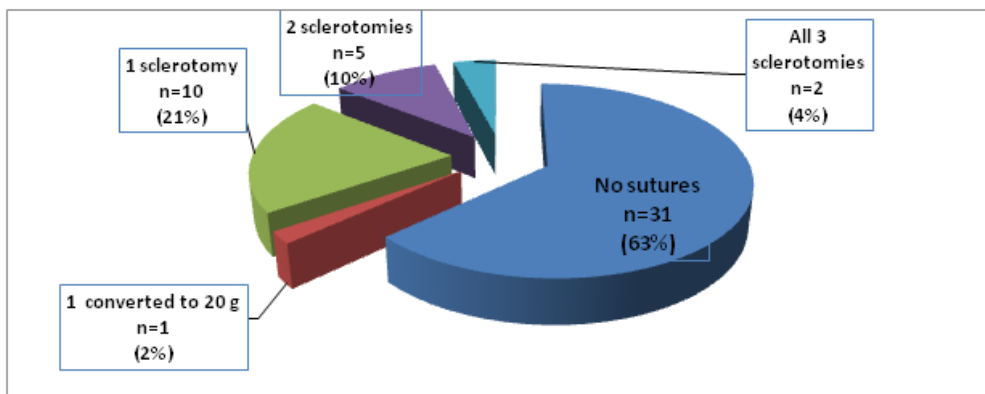
Overall, vision improved in 39 (78%) eyes, remained same in 8 eyes (16%) and worsened in 3 eyes (6%).

**Intraoperative Complications**

**1. Retinal Breaks:** 2 patients (4%) developed intraoperative retinal breaks. Both occurred in Proliferative Diabetic Retinopathy cases with extensive fibro vascular proliferation while trying to dissect the same.

**2. Choroidal Effusion:** 1 case developed choroidal effusion due to sub retinal cannula. This was a patient with longstanding Retinal detachment with choroidal detachment. The 23 G cannulas were removed and the surgery converted to a 20 g vitrectomy.

**3. Wound Leak requiring suturing of sclerotomies (Chart 3) :** 18 cases (36 %) required suturing of at least one sclerotomy due to suspicion of leak after removal of the cannulas and massaging . 10 cases (20%) needed suturing of only 1 sclerotomy while 2 cases(4%) required suturing of all 3 sclerotomies. One case required removal of 1 trocar cannula and enlargement so as to retrieve a foreign body and hence required suturing.



**Chart 3:** No. of Cases Needing Suturing of Sclerotomies

<sup>#</sup> Calculated Snellen Equivalent

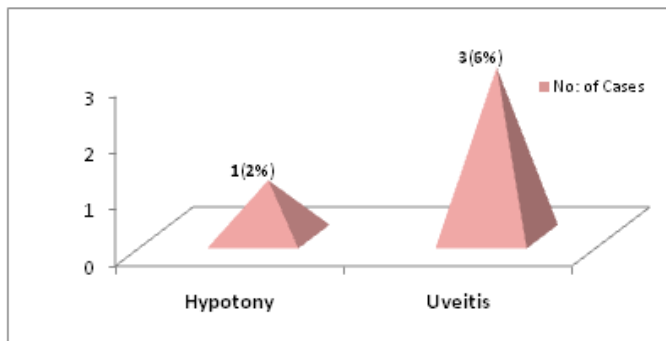
On doing subgroup analysis it was found that the majority of the cases which needed closure of sclerotomies with suture were those in which a silicone oil tamponade was used i.e. 10 out of 17 cases (58.8%). Among the eyes in which gas air mixture was used for tamponade only 1 out of 6 cases needed closure with a suture (16.7%). These results are outlined in Table 4.

**Table 4:** Type of Tamponade and Suturing

	Total No: of cases(n)	Sutured No:	%age of Cases Sutured
Silicone Oil Tamponade	17	10	58.8%
C3F8Gas Tamponade	6	1	16.7%
Air	8	2	25.0%
Fluid	19	6	31.6%

**4. Early Post Op Complications (Chart 4)**

1 case (2%) had hypotony from the first post op day , but recovered without any intervention in 5 days .3 cases(6%) developed post operative uveitis which cleared in 4-5 days on hiking up the steroids . 1 patient was also given Posterior Subtenons injection of Triamcinalone.



**Chart 4:** Early Post Operative Complications(%age)

**Late Post Operative Complications**

These were the complications reported or identified after the 1 st post op visit at 1 week. See [Table 5](#)

**Table 5:** Late Post Op Complications

	No Of Cases	% age
Vitreous Hemorrhage	4	8%
Cataract	3	6%
Retinal Redetachment	1	2%
SO in AC	1	2%

All the vitreous hemorrhage occurred in cases operated for non resolving vitreous hemorrhage where only air was used for tamponade. 1 was a case of PDR , 2 cases were BRVO Vitreous hemorrhage and 1 case was a Vitreous Hemorrhage due to IPCV. No cases needed revitrectomy as the hemorrhage cleared spontaneously over a period of 1-2 months.

Among the 3 cases which developed cataract at 6 wks, 2 were cases who had undergone vitrectomy for Retinal Detachment and 1 was a case of PDR Vitreous Hemorrhage. Silicone Oil tamponade was used in all 3 cases. Of this there was a suspicion of lens injury during the surgery itself in one case.

1 case of Retinal detachment developed redetachment at 6 wks. This was subsequently operated again.

**Discussion**

This study was designed to retrospectively analyze the initial 50 consecutive cases of 23 Gauge Transconjunctival Vitrectomy done by a single surgeon in a tertiary eye care centre so as to review the safety profile by analyzing the various intraoperative and post operative complications encountered as well as the need for suture placement and conversion to 20 gauge instrumentation. The effectiveness of the procedure was evaluated by comparing visual acuity results preoperatively and postoperatively. Conversion of the visual acuities to Logmar units allowed quantification of the visual improvement and reasonably accurate statistical analysis <sup>(1)</sup>.

The number of cases which required suturing of at least 1 sclerotomy due to suspected wound leak was 36% i.e. 18 cases. This was relatively high when compared to other

similar studies in the literature. In Eckardt's original series of 41 cases none were sutured<sup>(2)</sup>. In Fine and associates<sup>(3)</sup> series of 77 cases intraoperative suturing was required in only 1 case (1.3%). However our results were similar to that of Janet J Chieh et al<sup>(4)</sup> who reported suturing in 38 % patients. The variation could be due to the low tolerance to possible leaks. It was also seen that most of the patients where suture closure was required had silicone oil as the tamponade. Those with gas –air mixture or air sealed better and only less than 1/4<sup>th</sup> of those patients required suturing of at least 1 sclerotomy. A learning curve also might be there as our comfort level in leaving sutures increased after the first 25 cases. However only 1 case (2%) had hypotony in the immediate post operative period in our series, which also recovered by the 5<sup>th</sup> day without any intervention. This is lower than some of the other series like 10% in Lott et al<sup>(5)</sup> and 6.5 % in Gupta et al<sup>(6)</sup> The incidence of other Intraoperative and Post Operative complications like Retinal breaks (4%), Choroidal effusion (2%), Vitreous Hemorrhage (8%), Cataract (6%), Retinal Redetachment (2%), and Silicone oil in anterior chamber (2%) were all low and were in line with what is reported by other similar studies. Fine & Associates<sup>(3)</sup> reported 13 % Retinal redetachment (but occurred later than 6 wks), 1.3% early cataract due to lens injury and 1 case of severe intraocular inflammation which was presumed to be endophthalmitis (1.3 % ). Gupta et al<sup>(6)</sup> reported 2.2% Intraoperative Retinal Breaks, Post operative retinal tear in 1.1%, and Retinal redetachment in 1.1%. Over all our results were in line with the low complications rate reported by the other similar studies<sup>(2,3,4,5,6)</sup> and reiterates the safety of the procedure. The visual outcomes in our study were also reasonable and as expected .They were

comparable to other studies. Overall visual improvement results were found to be of high statistical significance.

### Conclusions

23 Gauge Transconjunctival Vitrectomy is an effective surgical technique for a variety of Vitreoretinal surgical indications. The safety and efficacy compared well with that in the published literature. Further Studies with head to head comparison of 20 gauge , 23 gauge and 25 gauge systems covering all vitreoretinal indications are necessary to bring out the potential advantages and disadvantages of each system.

### References

1. Holladay JT. Proper method for calculating average visual acuity. *JRefract Surg.* 1997;13:388–391.
2. Eckardt C. Transconjunctival sutureless 23-gauge vitrectomy. *Retina* 2005;25:208–211.
3. Fine HF, Iranmanesh R, Iturralde D, Spaide RF. Outcomes of 77 consecutive cases of 23-gauge transconjunctival vitrectomy surgery for posterior segment disease. *Ophthalmology* 2007;114:1197–2000.
4. Janet J. Chieh, Adam H. Rogers, Torsten W. Wiegand, Caroline R. Bauman, Elias Reichel, Jay S. Duker. Short-term safety of 23-gauge single-step transconjunctival vitrectomy surgery. *Retina* 2009;29:1486–1490.
5. Lott MN, Manning MH, Singh J, Zhang H, Singh H, Marcus DM. 23-Gauge vitrectomy in 100 eyes: short-term visual outcomes and complications. *Retina* 2008;28:1193–1200.
6. Omesh P. Gupta, Allen C. Ho, Peter K. Kaiser, Carl D. Regillo, Sanford Chen, David S. Dyer, Pravin U. Dugel, Sunil Gupta, And John S. Pollack *Am J Ophthalmol* 2008;146:193–197.
7. Spandau Ulrich & Heimann Heinrich. *Practical Handbook for Small-Gauge Vitrectomy: A Step-by-Step Introduction to Surgical Techniques* :Springer-Verlag Berlin and Heidelberg GmbH & Co. K, Berlin, 2012.