

A Classical Case of Turner Syndrome

Chandrashekhar T.¹, Veena D.^{2*}

¹Associate professor, ²Junior Resident

Department of Obstetrics and Gynecology, Vijayanagara Institute of Medical Sciences, Bellary, Karnataka, INDIA.

*Corresponding Address:

veena2087@gmail.com

Case Report

Abstract: Turner's syndrome is the most common karyotypic abnormality causing gonadal failure and primary amenorrhea. We present here 14 year old girl with primary amenorrhea who had classical features of Turner's syndrome. The Karyotype analysis was consistent with the diagnosis.

Keywords: Turner's syndrome, karyotype, primary amenorrhoea

Introduction

Turner syndrome (TS) is an X chromosomal disorder with variable karyotypic abnormalities and protean clinical manifestations. It was first described as a distinct entity in 1938, by Turner. Amenorrhea is the result of accelerated atresia of follicles. The manifestations being

short stature, webbed neck, shield chest, cubitus valgus, low hairline, high arched palate, short fourth metacarpals, renal and cardiovascular anomalies, etc. In 1959, it was recognized that Turner's syndrome resulted from the loss of an X chromosome or essential parts of it. Turner Syndrome is characterized by sexual infantilism, webbed neck, short stature, peripheral edema, lymphedema, renal and cardiovascular anomalies, gonadal dysplasia, some learning disability etc. (1). We present here 14 year old girl with primary amenorrhea who had classical features of Turner's syndrome.

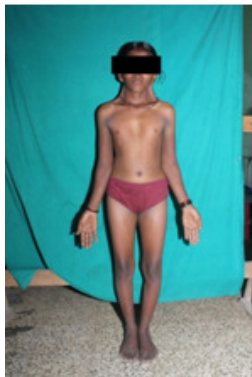

Figure 1: Short stature, webbed neck, shield chest and cubitus valgus

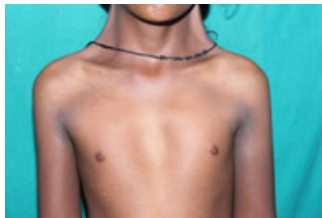

Figure 2: Webbed neck, shield chest and cubitus valgus

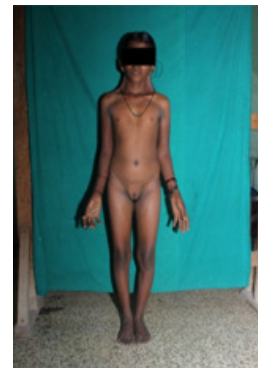

Figure 3: Tanner stage 1 of breast and Pubic hair

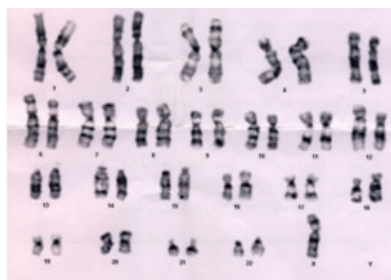


Figure 4: Karyotyping 45XO

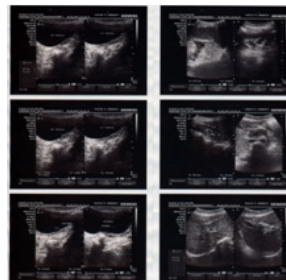


Figure 5: Bilateral Streak ovaries and hypoplastic uterus on USG abdomen and pelvis

Case Report

A 14 year old girl was admitted to Dept of OBG, Vijayanagar Institute of Medical Sciences, Bellary with complains of primary amenorrhoea and recurrent ear infections. On physical examination, patient was short stature and had webbed neck with a low hair line, low set ears, shield chest, cubitus valgus, high arched palate, short fourth metacarpals, Tanner stage of breast and pubic hair development was stage I representing pre-pubertal stage; features consistent with Turner's syndrome. Investigations revealed High FSH(131.05mIU/ml), low estradiol values(<9pg/ml), LH(27.90mIU/ml), normal thyroid function tests and normal testosterone (0.16ng/ml), ultrasound showed horse-shoe kidney, bilateral streak ovaries measuring 11×3mm on right side and 10×5mm on left. side and hypoplastic uterus measuring 34× 12 × 5mm. Echocardiography was normal. She was subjected for Karyotyping, consistent with Turner syndrome 45X0. In view of clinical details and laboratory finding the diagnosis of Turner Syndrome was made. The patient was managed symptomatically and followed.

Discussion

Turner's syndrome is the most common sex chromosome abnormality in females, affecting an estimated 3% of all females conceived.[2] The frequency among live-borne females is 1 in 2000 to 1 in 3000.[3] Approximately 98–99% of Turner's syndrome fetuses are spontaneously aborted, and about 20% of all spontaneously aborted fetuses have Turner's syndrome.[4] Turner's syndrome is associated with a constellation of potential abnormalities involving many organ systems, making it a challenging disorder for health care providers and families. The chromosomal basis of Turner syndrome was first recognized by Ford *et al.*(5). Every effort must be made to rule out the presence of the Y chromosome in patients with TS. In most of the patients with Turner's syndrome, the condition is diagnosed either in adolescence or in adulthood. The case reported in this study had almost all the described features

of Turner syndrome. In the absence of a functional second X chromosome the oocytes degenerate more rapidly than normal, so that at the time of birth there are few, if any, left and the ovarian tissue resembles fibrotic streaks(6). One fourth to one-third patients have renal malformation on ultrasonographic examination. The more serious defects include pelvic kidney, horse shoe kidney, double collecting system, complete absence of one of the kidney and ureteropelvic junction obstruction. Recurrent bilateral otitis media develops in about 75% of patients. Sensorineural hearing deficits are common and the frequency increases with age. The most common skeletal abnormalities are shortening of the 4th metatarsal and metacarpal bones, epiphyseal dysgenesis in the joints of the knees and elbows, madelung deformity, scoliosis. A multidisciplinary team should oversee management of girls with Turner syndrome from diagnosis through to adult life. Recombinant human growth hormone replacement therapy with estrogen and psychosocial support are the treatment modalities In general, oestrogen should be commenced around age 12-13, but generally no later than age 14. Gonadotrophin levels should be determined prior to introduction of oestrogens in order to confirm gonadal failure (elevated FSH).

References

1. Barbara RM, Carolyn AB, Karen RR. 3 perspectives on Turner's syndrome. *Endocr News*. 2007;8:12–9.
2. Zinn AR, Page DC, Fisher EMC. Turner Syndrome: The Case of the missing X chromosome. *Trends Genet* 1993 ; 9 : 90.
3. Hassan S, Ali M. Congenital esophageal stenosis in a patient with Turner's syndrome: A case report. *Govaresh*. 2003;8:184–6.
4. Calof OM, Davidson MB. Turner's syndrome: Diagnosis and management in 2005 (Part1)*Endotrends*. 2005;12:1–5.
5. Ford CE, Jones KW, Polani PE. A sex chromosomal anomaly in a case of gonadal dysgenesis (Turner's syndrome).*Lancet* 1959,1: 711-713.
6. Lippe BM. Primary ovarian failure. In: *clinical Pediatric Endocrinology*. Ed Kaplan SA. Philadelphia, W.B. Saunders Company, 1990, pp 325-366.