

# A Rare Case of Massive Ovarian Mucinous Cystadenoma with Vesicovaginal Fistula- An Interesting Case Report

Sanjay Kumar Patil<sup>1</sup>, Viral Kashyap Sheth<sup>2\*</sup>, Yamini S. Patil<sup>3</sup>

<sup>1,3</sup> Associate Professor, <sup>2</sup>Senior Resident

Department of Obstetrics and Gynaecology, Krishna Institute of Medical Sciences, Karad, Maharashtra, INDIA.

\*Corresponding Address:

[dr.viralsheth@gmail.com](mailto:dr.viralsheth@gmail.com)

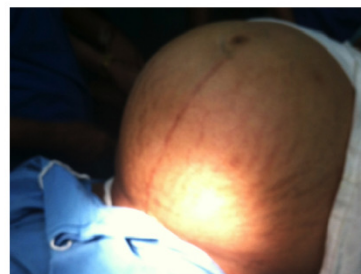
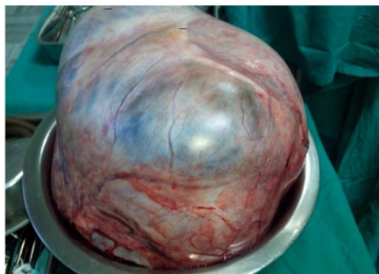
## Case Report

**Abstract:** Our reported case was a 45 old postmenopausal female presented with marked abdominal distension and discomfort since 6 months with dribbling of urine with history of injury to bladder during lower segment cesarean section. The data were collected by history-taking, clinical examination, laboratory investigations, transabdominal ultrasonographic examination, and by histopathological study of the excised surgical specimen. On abdominal examination, a huge ill-defined pelvi-abdominal mass was noticed, extended up to xiphisternum. Pelvic examination revealed normal sized non-pregnant firm uterus and fullness in the cul-de-sac and both adnexae and dribbling of urine. Transabdominal ultrasonography verified a massive multi-loculated cyst without solid components or surface papillary projections, extended up to the subhepatic area, with minimal free intraperitoneal fluid. Staging laparotomy proceed abdominal panhysterectomy with vesico vaginal fistula repair was done. Intraoperatively left ovary was replaced by a large cystic mass (45 × 25 × 30 cm) weighing 15 kg greyish white in colour freely mobile filled with turbid fluid. vesico vaginal fistula opening seen at end of cervix and vagina. Histopathological report confirmed the diagnosis. Postoperative recovery was uneventful and patient was discharged after 20days. This case report emphasizes the significance of thorough evaluation of all women presented with vague abdominal pains. Although the condition is extremely rare, it is a potentially dangerous in its massive form if not timely diagnosed and managed properly. With the increasing awareness of such conditions, more and more cases could be detected, reported and treated early.

**Keywords:** Multiloculated cyst, Vesico vaginal fistula, Staging laparotomy.

## Introduction

Ovarian mucinous cystadenoma is a benign tumor that arises from the surface epithelial of ovary. It is a multilocular cyst with smooth outer and inner surface. It tends to be huge in size. It comprises 15% of all ovarian tumors. About 80% are benign, 10% borderline and 10% malignant. Benign ovarian tumors are rare at extremities of age before puberty and after menopause, they are common between third and fifth decades. The most frequent complications are torsion, haemorrhage and rupture. As it contains mucinous fluid, its rupture lead to mucinous deposits on the peritoneum. (pseudo-myxoma peritonei) Vesicovaginal fistula: Abnormal communication between urinary bladder and vaginal leading to continous leakage of urine from vagina. In India, 90% of fistulas result from obstetric causes. It may be because of obstructed or prolonged labour, head of the fetus compresses the trigone or the bladder neck against the anterior arch of pubic symphysis. Instrumental trauma, incomplete healing of third degree perineal tears, during lscs bladder base may be torn. Here we present a rare case of massive ovarian mucinous cysadenoma with vesico vaginal fistula creating diagnostic and operative difficulties.



## Case report

A 45 years postmenopausal woman came with gross abdominal distension and discomfort since 6

months and able to walk with difficulty. She had dribbling of urine with history of injury to bladder during lower segment cesarean section. She attained menopause

4 years back. She had two normal deliveries and LSCS was done in last delivery for deep transverse arrest in which she faced with bladder injury. Bladder was repaired during that but later she developed fistula. General examination revealed normal vital signs other than slight raised BP of 130/90 mmHg. Her body weight was 98 Kg height was 158 cm and her abdominal circumference was 138cm. On Per abdomen examination A huge ill-defined, pelvic abdominal mass was noticed, extended up to xiphisternum with evident dermal striae. The abdomen was cystic tense on palpation without tenderness or shifting dullness or ascites. Tympanic note present on percussion .On Per speculum examination dribbling of urine was seen and cervix was flushed with vagina. Pelvic examination: revealed normal sized firm uterus and fullness in the cul de sac and both adnexae. A fistula was also felt with dribbling of urine. Vesicovaginal fistula was confirmed by three swab test.

### Investigations

Transabdominal ultrasonography verified a massive multi-loculated cyst without solid components or surface papillary projections, extended up to the subhepatic area, with minimal free intraperitoneal fluid. Patient was investigated further including full blood picture, serum biochemistry, cancer antigen Ca-125 which were normal. A plain chest X-ray shows an upward displacement of diaphragm affecting air entry into the lower lobe of lungs. No pleural effusion or metastasis were seen.

### Treatment

Patient was counseled and signed informed consent for surgical exploration(staging laparotomy). Exploratory laparotomy proceed abdominal panhysterectomy with vesico vaginal fistula repair was done. Under anaesthesia, a midline vertical incision below the xiphisternum was taken to deliver the cystic mass intact. The outer surface of the mass was smooth and intact all around without external growth or adhesions. The uterus, right adnexa and appendix were healthy. Left ovary was replaced by a large cystic mass (45x25x30cm), wedge shape weighing 15 Kg, greyish white in colour freely mobile filled with turbid fluid. Dilated vessels seen over cyst. No visible or palpable liver, peritoneal or intestinal metastasis seen. No enlarged lymph nodes. Peritoneal fluid sent for cytology. A fistulous opening approx 3-4 cm was present between the urinary bladder and vagina.

### For VVF Repair

Sagittal incision was taken of the posterior bladder wall into fistula and excision of the fistula was done. Single layer closure of the vagina. Mobilisation of a omental flap to cover the vaginal defect. Two layers closure of the bladder wall (urothelium and tunica muscularis) with vicryl 2-0. Suprapubic catheter was removed after 7 days.

Total abdominal hysterectomy with bilateral salpingoopherectomy with vvf repair was done. Suprapubic catheter was kept for 7 days and transurethral for 14days(dual drianage). Postoperative period was uneventful and patient was discharged after 20 days.

### Histopathology report

Microscopic examination revealed a cyst lined by a single layer of nonciliated columnar epithelium without stromal invasion. Cytology report showed peritoneal fluid negative for malignant cells. Histopathology report confirmed mucinous cystadenoma of left ovarian cyst.

### Discussion

Mucinous cystadenoma is a benign ovarian tumour comprising 30-40% of all ovarian tumors. Only 10% are bilateral and 12% of these are malignant. On gross appearance they are characterized by cysts of variable size without surface invasion. Various theories have been postulated that it arises from surface or germinal epithelium (Hertig),arises from brenner tumour as two are known to coexist, few may be derived from a monophyletic teratoma-it has been shown to be associated with dermoid, a special differentiation of the totipotent gonadal mesenchyme. Cross section- shows a multiloculated cyst. The number of loculi depending upon which is more active: septa laying activity and septa destroying activity. In septa laying activity the cross section has a honey comb appearance. The loculi contains sticky, viscid, mucinous material. The fluid is colourless but may be green yellow or brown depending upon the blood pigments. Histologically - the cysts are lined by tall columnar picket cells which resemble the secretory cells of endocervix. They have deep staining basal nuclei and finely granular acidophilic cytoplasm. Between them actively secreting goblet cells secreting glycoprotein and argentaffine cells have been identified. Detection of ovarian cysts causes considerable worry for women because of fear of malignancy, but fortunately the majority of ovarian cysts are benign. Management of ovarian cysts depends on the patient's age, the size of the cyst and its histo-pathological nature. After surgery, the patient should be followed-up carefully as some tumours reoccur. Although the tumour was removed completely and intact with the affected ovary, our patient was given appointments to be reviewed every 3 months for a year.

### References

1. Mittal S, Gupta N, Sharma A, Dadhwal V. Laparoscopic management of a large recurrent benign mucinous cystadenoma of the ovary. Arch Gynecol Obstet. 2008;277(4):379-380. doi: 10.1007/s00404-007-0556-5. [[PubMed](#)] [[Cross Ref](#)]
2. Crum CP, Lester SC, Cotran RS. In: Robbins' Basic pathology. 8. Kumar V, Abbas A, Fausto N, Mitchell R,

- editor. Ch 19. Elsevier Company, USA; 2007. Pathology of female genital system and breast.
3. Ioffe OB, Sinsir A, Silverberg SG. In: Practical Gynaecologic Oncology. Berek JS, Hacker NF, editor. Lippincott Williams and Wilkins Company; 2000. Pathology; pp. 213–214
  4. Miller NF. Treatment of Vesico-vaginal fistulae. *Am J Obstet Gynecol* 1935;30:675–9.
  5. Jonas U, Petri E. Genitourinary fistulae. In Stanton SL ed. *Clinical Gynecologic Urology*. St. Louis: CV Mosbey, 1984.p. 238–55.
  6. Occhipinti K.A.: Computed tomography and magnetic resonance imaging of the ovary. In: Anderson JC, ed. *Gynecologic imaging*. London, England: Churchill Livingstone, 1999, 345-359.
  7. Tancer ML. Observation on prevention and management of vesico-vaginal fistulae after total hysterectomy. *Surg Gynecol Obstet*. 1992;175(6):501–6.
  8. Vizza E, Galati GM, Corrado G, Atlante M, Infante C, Sbiroli C. Voluminous mucinous cystadenoma of the ovary in a 13-year-old girl. *J Ped Adoles Gynecol*. 2005;18(6):419–422. doi: 10.1016/j.jpag.2005.09.009. [[PubMed](#)] [[Cross Ref](#)]
  9. Ozgun MT, Turkyilmaz C. A giant ovarian mucinous cystadenoma in an adolescent: a case report. *Arch Med Sci*. 2009;5(2):281–283.
  10. Yenicesu GI, Cetin M, Arici S. A huge ovarian mucinous cystadenoma complicating pregnancy: a case report. *Cumhuriyet Med J*. 2009;31:174–177.
  11. Alobaid AS. Mucinous cystadenoma of the ovary in a 12-year-old girl. *Saudi Med J*. 2008;29(1):126–128. [[PubMed](#)]
  12. Young RH. In: Sternberg's *Diagnostic Surgical Pathology*. Mills SE, Carter D, Greenson JK, Reuter E, editor. Raven Press, NY; 2009. The ovary; p. 2195