

A Rare Presentation of Sternal Tuberculosis with Pulmonary Tuberculosis in an Immunocompetent Adult

V. R. Lokhande

Terna Sahyadri Hospital, Opposite Nerul Railway Station, Sec – 22, Nerul West, Navi Mumbai, Maharashtra- 400706, INDIA.

Corresponding Address:

vrl_doc@yahoo.co.in

Case Report

Abstract: The case of a 30 years old male presenting with pain and swelling over the manubrium sternii with no constitutional symptoms is presented here. The patient was immunocompetent and found to have tuberculous affection of sternum with lung involvement as well based on imaging and histopathology. He was treated with anti tuberculous therapy for 9 months and responded well with complete resolution of the lesions. A one year follow up has revealed no recurrence so far. This case highlights the importance of rare presentations of TB in immunocompetent individuals.

Keywords: Tuberculosis, sternum, Immunocompetent

Introduction

Bone and joint TB account for less than 7% of the total cases of tuberculosis. Tuberculous affection of the flat bones is even rare with sternal TB accounting for less than 1.5% of the cases [1]. In developing countries, TB affection of rare sites is predominant in immunocompromised population, though few cases of immunocompetent subjects being afflicted have been reported [2]. Untreated, sternal TB may result in destruction and even fracture of the sternum, at times necessitating surgical repair [3, 4]. Extrasternal sites may be involved in less than 50% of the cases of sternal TB, most commonly, hilar lymph nodes or adjoining lung parenchyma [5]. The diagnosis is usually by histopathology [5]. Imaging modalities like CT and MRI may help differentiate the nature of the lesion, as well as the extent [6]. The medical treatment is standard with 4 drug antitubercular treatment for 2 months, followed by two drug therapy for 4 months though some experts recommend extending therapy to a total duration of 9 months in bone TB[7].

Case Report

A 30yrs old male presented with a painful swelling over the manubrium sternii of 6 months duration, gradually increasing in size accompanied by fever and weight loss. There was no history of bone pains elsewhere. There was no prior history of antecedent trauma as reported by the patient. General examination revealed an averagely built

patient, with no evidence of malnutrition or telltale signs of immunocompromised state such as oral thrush. Systemic examination revealed decreased air entry on the left side while locally, a tender swelling was observed over the manubrium, 2 cm x 2 cm, non fluctuating and cold. There was no enlargement of the cervical or axillary group of lymph nodes. Hemogram revealed a raised ESR – 78 mm with normal leucocyte count and hemoglobin of 10.8 gm/dl. Chest radiographs revealed doubtful left upper zone infiltrates, but sternal region appeared unremarkable. Ultrasound examination of the lesion revealed a cystic lesion overlying the manubrium sterni. Computed tomography of the chest showed extensive erosion involving the manubrium, involving the inner and outer cortex with surrounding soft tissue extending into the surrounding superior mediastinum (Fig.1 and 2). There were multiple branching nodular opacities in the left lung upper zone with enlarged hilar lymph nodes. The blood sugar was normal, HIV was non- reactive. Renal profile and liver function tests were normal, suggesting no evidence of immunocompromised state. FNAC of the lesion was done that showed evidence of granulomatous inflammation with lymphocytes, epithelioid granulomas, rare giant cells with caseation; suggestive of tuberculosis. The patient was started on 4 drug anti- tuberculosis treatment regimen consisting of Isoniazid, Rifampicin, Ethambutol and Pyrazinamide as per weight, along with hematinics; within a month the swelling regressed with considerable pain relief and the patient was afebrile. He was fully asymptomatic at the end of 2 months with weight gain, improved appetite and a sense of well- being with a rise in Hb to 12.7 gm/dl. After 2 months, he was put on 2 drug ATT consisting of Isoniazid and Rifampicin. ATT was continued for a total of 9 months after which a follow up CT Chest revealed complete resolution of the soft tissue around the manubrium, resolution of the hilar and paratracheal lymph nodes and fibrotic scarring over the upper zone of the left lung (Fig.

3).The patient was regularly followed up for the past one year; and he has been asymptomatic and disease free.

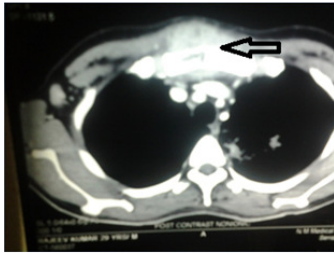


Figure 1: Osteomyelitis of manubrium sternii.
Note the erosion of the sternum with soft tissue shadows

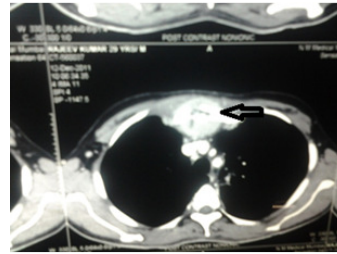


Figure 2: Soft tissue eroding the sternal cortex, with extension into the mediastinum

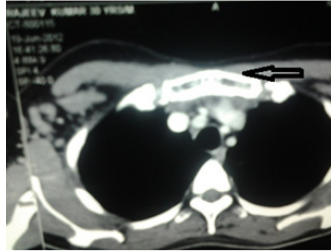


Figure 3: Near complete resolution of the soft tissue as compared to the previous images (Figure 1 and 2)

Discussion

The burden of tuberculosis in developing countries is high, more so in the immunocompromised population. HIV TB co-infection may lead to severe morbidity and may also prove costly in terms of resources. Pulmonary tuberculosis accounts for the majority of cases of TB, while bone and joint TB account for less than 7% of the total cases of tuberculosis. Tuberculous affection of the flat bones is even rare, with sternal TB accounting for less than 1.5% [1]. In developing countries, TB affection of rare sites is predominantly seen in immunocompromised population, though few cases of immunocompetent subjects being afflicted have been reported [2]. Sternal tuberculous affliction may either present as osteomyelitis of the sternum or as a granuloma formation. The clinical presentation is generally a painful swelling over the sternum. Extrasternal sites are involved in less than 50% of the cases of sternal TB, most commonly, hilar lymph nodes or adjoining lung parenchyma [5]. There have been case reports of destruction of the sternum following TB and requiring extensive debridement and partial sternectomy and flap closure [3]. Rare cases of spontaneous fracture of the sternum following sternal TB have also been reported [4], which was more common with malignant infiltration of the sternum. Considering the proximity of the mediastinal structures, an invasive disease affecting the sternum could be life threatening. The diagnosis is usually by histopathology [5], which remains the gold standard. FNAC has been proven useful in many cases [5]. Isolation of the mycobacteria would be ideal [5], more importantly when dealing with a case of suspected MDR TB for drug sensitivity testing. Imaging modalities like CT and MRI are more relevant as

radiographs may not reveal any lesions [6].MRI findings include destruction and signal intensity changes of the sternum, destruction of the cartilage, soft tissue changes representing granulation tissue or abscess, and inflammatory changes in the adjacent structures in the form of cellulitis and myositis[6]. MRI may help differentiate the nature of the lesion , as well as the extent of soft tissue as well as marrow involvement [6].CT of the thorax may reveal soft tissue abscess or sclerosis of the ribs as reported in one series[7]. The medical treatment is 4 drug antitubercular treatment for 2 months, consisting of Isoniazid, Rifampicin, Etambutol and Pyrazinamide, followed by two drug therapy of Isoniazid and Rifampicin for 4 months though some experts recommend extending therapy to a total duration of 9 months in bone TB[8]. Surgical debridement and flap closure is required in cases with extensive destruction [3]. In conclusion, the presentations of TB may be bizarre and at unusual locations. Clinicians need to keep TB in the differential diagnosis of unusual site presentations so as to be able to decide appropriate and timely treatment to prevent serious consequences. It would be worthwhile to evaluate the patient for concomitant pulmonary and lymph node involvement. It is also essential to remember that though the predilection for extrapulmonary TB is more in immunocompromised individuals, it has often been observed in immunocompetent persons as well and investigations for the same would be worthwhile.

References

1. Tuli SM. Tuberculosis of rare sites, girdle and flat bones. In: Tuli SM (ed). Tuberculosis of the Skeletal System. Bursal Sheaths. 2nd ed. Delhi: Jaypee Brothers Medical Publishers, 2000: 159-160.

2. Cherif E, Ben Hassine L, Boukhris I, Khalfallah N. Sternal tuberculosis in an immunocompetent adult. *BMJ Case Rep.* 2013 Apr 10; 2013.
3. Zhao X¹, Chen S, Deanda A Jr, Kiev J. A rare presentation of tuberculosis. *Am Surg.* 2006 Jan; 72(1):96-7.
4. Watts RA, Paice EW, White AG. Spontaneous fracture of the sternum and sternal tuberculosis. *Thorax* 1987; 42: 984-985
5. McLellan DG¹, Philips KB, Corbett CE, Bronze MS. Sternal osteomyelitis caused by mycobacterium tuberculosis: case report and review of the literature. *Am J Med Sci.* 2000 Apr; 319(4):250-4.
6. Shah J¹, Patkar D, Parikh B, Parmar H, Varma R, Patankar T, Prasad S Tuberculosis of the sternum and clavicle: imaging findings in 15 patients *Skeletal Radiol.* 2000 Aug; 29(8):447-53.
7. A. Khali, C. Le Breton, M Tsart *et al.* Utility of CT scan for the diagnosis of chest wall tuberculosis *Eur. Radiol.* 9 (1638- 1642), 1999
8. WHO. Treatment of Tuberculosis guidelines. 4th Edition 2010.