

Small bowel volvulus due to multiple jejunal diverticulae – a rare case report

G. P. Sekar^{1*}, T. V. Subha², B. Selvaraj³, M. M. Usman⁴

^{1,3}Associate Professor, ^{2,4}Assistant Professor, Department of Surgery, Sri Venkateshwaraa Medical College Hospital and RC, Ariyur, Puducherry- 605102, INDIA.

Email: dr.gpsekar@yahoo.com

Abstract

Small bowel volvulus without malrotation is uncommon, and most surgeons have limited experience in this condition. We present an interesting case of small bowel volvulus with jejunal diverticulosis but without any evidence of malrotation. 55 yrs old female patient who complained of intermittent upper abdominal pain for 2 yrs. CT scan revealed mesenteric vessel 'whirlpool' sign and laparotomy showed small bowel volvulus with multiple jejunal diverticulae in the involved segment. This case highlights the small bowel volvulus secondary to jejunal diverticulosis, a rare cause of small bowel obstruction which needs early diagnosis and prompt treatment.

Keywords: volvulus, small bowel obstruction, jejunal diverticula

*Address for Correspondence

Dr. G.P. Sekar, Associate Professor, Department of Surgery, Sri Venkateshwaraa Medical College Hospital and RC, Ariyur, Puducherry- 605102 INDIA.

Email: dr.gpsekar@yahoo.com

Received Date: 14/05/2014 Accepted Date: 09/06/2014

Access this article online

Quick Response Code:	Website: www.statperson.com
	DOI: 09 June 2014

INTRODUCTION

Intestinal obstruction is a common cause of emergency surgical admission. Small bowel obstruction due to volvulus is a rare cause of obstruction in adults. There are two types primary and secondary. Secondary may be due to adhesive bands, Meckel's diverticulum, jejunoileal diverticulum, internal hernias. Early diagnosis and expedient surgical treatment is required to prevent bowel ischemia. Jejunoileal diverticulum is an uncommon entity. Most of the cases are asymptomatic. It may present as diverticulitis, perforation, hemorrhage or intestinal obstruction. We present a case of small bowel volvulus secondary to multiple jejunal diverticulae without bowel ischemia.

CASE REPORT

55 yr old female was admitted with complaints of severe upper abdominal pain with one episode of non bilious vomiting. No history of constipation and diarrhea. History of passing flatus. Past history of previous similar episodes for 2 yrs. There was no history of previous abdominal surgeries. On examination patient general condition was fair, vitals were stable. Examination revealed a soft undistended abdomen with epigastric tenderness. There was no guarding or rigidity and bowel sounds were present. Digital rectal examination was normal. Abdomen x-ray showed no abnormalities. Blood investigations total count, differential count, serum amylase were within normal limit. USG abdomen showed 'whirl sign' which was suggestive of mesentery torsion (Fig.1). To confirm the diagnosis CECT abdomen was done. CT revealed jejunal loops were spiraling counterclockwise in a horizontal orientation around the superior mesenteric axis producing 'whirl sign' (Fig.2). SMA and SMV relationship appeared to be normal. CT imaging features suggested midgut volvulus probably without malrotation. Emergency laparotomy was done. Laparotomy findings were three complete rotation of proximal jejunum in counter clockwise direction along its axis without bowel ischemia. (Fig3) Additional finding was volvulus part of bowel containing multiple jejunal diverticulae among this one was giant diverticulum (Fig.4). Caecum was in right

iliac fossa and ligament of Treitz was in normal anatomical position which revealed there was no malrotation. Derotation with resection and anastomosis of

diverticulum containing jejunum was done. Postoperative period was uneventful. Patient discharged on 9th post operative day.

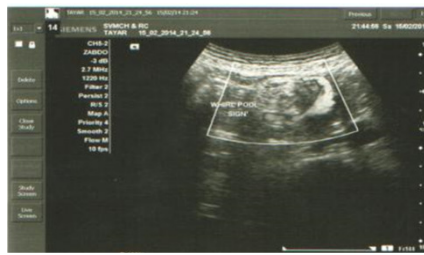

Figure 1: USG abdomen shows 'whirl sign'

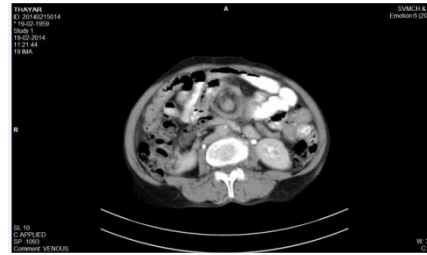


Figure 2: CECT abdomen shows 'whirl sign'

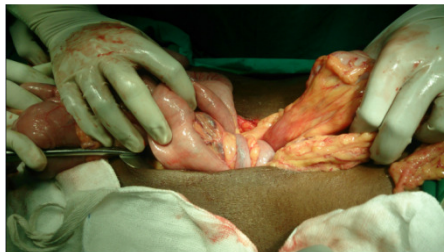

Figure 3: Intra operative picture shows volvulus of proximal jejunum

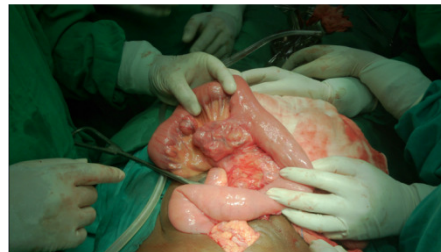

Figure 4: Intra operative picture shows multiple jejunal diverticuli in the summit of volvulus

DISCUSSION

The term volvulus is derived from latin word volvere which means to turn or roll. Volvulus refers to twisting of hollow organ about its mesentery more than 180 degree which results in intestinal obstruction, impaired venous return and progressed to bowel ischemia. The incidence of small bowel volvulus compared to caecal and sigmoid volvulus is very low. The reported annual incidence ranges from 1.5 to 5.7 per one lakh population in the Western world and 24 to 60 per lakh population in Africa and Asia¹. Small bowel volvulus refers to twist of the small bowel around the main trunks of the superior mesenteric artery and vein. In neonates and infants volvulus is usually associated with congenital malrotation. In adults, small bowel volvulus is classified into primary and secondary. It is thought that primary volvulus is due to bulky food bolus in the small bowel pulling the loop down and shifting the other empty parts of small bowel upwards and results in twisting of mesentery^{2, 3, 4}. Secondary volvulus results from various predisposing factors such as bands⁵, adhesions^{4,6}, Meckel's diverticulum, jejunal diverticulum^{7,8}, internal hernia⁹, bypass procedures^{10,11}, pregnancy¹² and congenital malformations¹³. In jejunoileal diverticulosis, volvulus may be due to pulling of fluid filled diverticulum containing bowel segment downwards like pendulum results in torsion of mesentery. Most of the cases are diagnosed as acute intestinal obstruction⁷. Severe abdominal pain is the principal symptom in almost all

patients^{1, 3}. Central abdominal pain resistant to narcotic analgesia should heighten the suspicion of the diagnosis¹. Associated symptoms are nausea, vomiting, abdominal distention³. In our case, patient presented with severe upper abdominal pain. Small bowel volvulus is difficult to diagnose clinically because clinical signs are those of obstruction and peritonitis. Laboratory investigations such as leucocytosis, raised amylase, raised lactate dehydrogenase¹⁴ and metabolic acidosis all suggest the diagnosis but non specific. Plain x –ray abdomen may show multiple air fluid level or dilated bowel loops which are features of obstruction. Other imaging investigations more helpful in diagnosis are barium studies and angiography. Barium studies can show the 'cork screw' appearance¹⁵. Angiogram shows the 'barber pole' sign due to spiraling of superior mesenteric artery¹⁶. However these investigations do not allow rapid diagnosis. CT is the non-invasive mode of imaging and widely available with rapid diagnosing ability. 'Whirl sign' is present in 75 % of small bowel volvulus cases which is due to the torsion of mesentery. 'Peacock tail sign' is described when there is bowel torsion around its mesenteric axis^{8,16}. Both signs are diagnostic. CT scan is a valuable investigation to diagnose small bowel volvulus with sensitivity of 94-100% and specificity of 90-95%^{8, 16}. The surgical treatment for small bowel volvulus are detorsion with or without fixation and resection of the involved segment with anastomosis. Earlier the diagnosis better will be the outcome, because mortality rate is high in gangrenous

bowel^{1, 3}. Jejunal diverticulosis is a rare entity and mostly asymptomatic. Surgical intervention is mandatory in patients with complications of jejunal diverticulosis, and formal resection is the mainstay of surgical treatment¹⁷. In our case, patient had multiple jejunal diverticulosis involving volvulus of intestine, we did derotation and resection of the involved segment with anastomosis.

CONCLUSION

Small bowel volvulus without evidence of malrotation is rare. Jejunal diverticulosis as the precipitating factor for the small bowel volvulus was present in our case. Prompt surgery and resection if necessary would be the optimal management.

REFERENCES

1. Iwuagwu O, Deans GT. Small bowel volvulus: a review. *J R Coll Surg Edinb* 1999; 44: 150-5.
2. Leo j de souza Volvulus of the small bowel. *British Medical Journal*, 1976, 1, 1055-1056
3. Richard c. frazee, M.D, peter mucha, M.D., Volvulus of the Small Intestine From the Department of Surgery, Mayo Clinic and Mayo Foundation, Rochester, Minnesota, *Ann. Surg* November 1988 vol 208 no 5
4. Wig J D, Bose S M, Kaushik S P – J, Volvulus obstruction of the small and large bowels, *Postgrad Med Year* : 1978 | Volume : 24 | Issue : 2 | Page : 117-120
5. Zulfiqar Ali Jehangir Khan, FRCS, Elisabeth Drye, MBBS, [...], and John Richard Novell, M Chir, Small Bowel Volvulus Resulting in Infarction due to an Anterior Gastropexy Band, *JSLs*. 2002 Jan-Mar; 6(1): 77-79
6. Peter G. Katis and Solange M. Dias, Volvulus: a rare twist on small-bowel obstruction, *CMAJ*. Sep 28, 2004; 171(7): 728.
7. Ömer Rıdvan Tarhan, İbrahim Barut, Celal Çerci , An interesting coexistence: Small bowel volvulus and small bowel diverticulosis, *The Turkish Journal of Gastroenterology* 2006, Volume 17, No 4, Page(s) 300-304
8. Jia-Li Hu and Wei-Zhong Chen, Midgut volvulus due to jejunal diverticula: A case report *World J Gastroenterol*. Oct 28, 2012; 18(40): 5826–5829.
9. Ajai Khanna, Beverley Newman, [...], and Thomas E. Starzl ,Internal hernia and volvulus of the small bowel following liver transplantation, *Transpl Int*. 1997; 10(2): 133–136.
10. Pranav H Patel, Alistair AP Slessor, [...], and Jeremy I Livingstone, A rare case of small bowel volvulus after jejunoileal bariatric bypass requiring emergency surgery: a case report, *J Med Case Rep*. 2012; 6: 78.
11. Arilyn Ng, Ruben Toribio, and Ginosuke Sugiyama ,Rare case of concurrent intussusception and volvulus after Roux-en-Y gastric bypass for morbid obesity, *J Surg Case Rep*. Jan 2013; 2013(1): rjs018.
12. Ioannis Vassiliou, Alikı Tympa, [...], and Nikolaos Vlahos, Small bowel Ischemia due to Jejunum Volvulus in Pregnancy: A Case Report, *Case Rep Obstet Gynecol*. 2012; 2012: 485863.
13. Hee Jang, MD, Su Lim Lee, MD Jin Small Bowel Volvulus Induced by Mesenteric Lymphangioma in an Adult: a Case report, *Korean J Radiol*. 2009 May-Jun; 10(3): 319–322.
14. Uday kumar, Anand sharan, Shaheema kamal. Raised serum lactate dehydrogenase associated with gangrenous small bowel volvulus: a case report. *Indian journal of clinical biochemistry*, 2003 18(2) 6-7.
15. Chung kuaou chou, M.D., Chee wai mark, M.D., Large diverticulum and volvulus of small bowel in adults. *World j. surg* 29, 80-82(2005).
16. Ugur Bozlar, MD, Mehmet Sahin Ugurel, MD, [...], and Unsal Coskun, MD, CT Angiographic Demonstration of a Mesenteric Vessel "Whirlpool" in Intestinal Malrotation and Midgut Volvulus: a Case Report, *Korean J Radiol*. 2008 Sep-Oct; 9(5): 466–469.

Source of Support: None Declared
Conflict of Interest: None Declared