

A silent presentation of a pituitary macroadenoma - detected by simple colour vision evaluation

N. Ezhilvathani^{1*}, Thiagarajan M. S.², M. J. Venkatesan³

¹Associate Professor and HOD, ²Professor, ³Assistant Professor, Department of Ophthalmology, Pondicherry Institute of Medical Sciences, Kalapet, Pondicherry, INDIA.

Email: ezhilvathani3@gmail.com

Abstract

Pituitary adenoma is a benign epithelial neoplasm derived from and composed of adenohypophysial cells. Patients with intracranial pituitary adenomas are most commonly detected by endocrinologists, although the non-secreting tumours may first present to Ophthalmologists. Herewith reporting a case of a huge pituitary adenoma of size 34x23x31mm which presented with the symptoms of an occasional vague, transient blurring of vision during the initial visit with a normal visual acuity, anterior segment and a posterior segment. The clinical importance of recording colour vision apart from the regular evaluation of visual acuity, slit lamp evaluation, intraocular pressure measurement and fundus evaluation in an otherwise asymptomatic patient is stressed in this article. This clinical evaluation is very important in the early diagnosis and patient management which should have far reaching benefits.

Keywords: Macroadenoma, Colour vision, Bjerrum's screen, Computerized Humphrey field analyser, Bi-temporal hemianopia,

Address for Correspondence

Dr. N.Ezhilvathani, Associate Professor and HOD, Department of Ophthalmology, Pondicherry Institute of Medical Sciences, Kalapet, Pondicherry, INDIA.

Email: ezhilvathani3@gmail.com

Received Date: 12/06/2014 Accepted Date: 21/06/2014

Access this article online

Quick Response Code:	Website: www.statperson.com
	DOI: 24 June 2014

INTRODUCTION

The sellar region is a site of various types of tumors. Pituitary adenomas are the most common. They arise from epithelial pituitary cells and account for 10-15% of all intracranial tumors. Tumors affect individuals of all ages, but incidence increases with age, peaking between the third and sixth decades of life. Tumors exceeding 10 mm are defined as macroadenomas, and those smaller than 10 mm are termed microadenomas. Most pituitary adenomas are microadenomas. Further to this, pituitary

adenomas are classified according to their hormonal activity as functioning and non-functioning adenomas. Functioning adenomas are hormonally active, and include: Prolactin secreting adenomas (PRL), Adrenocorticotrophic Hormone (ACTH) secreting adenomas, Growth Hormone (GH) secreting adenomas, Thyroid Stimulating Hormone (TSH) secreting adenomas and Mixed adenomas. Non-functioning adenomas account for between 25 and 35 percent of pituitary adenomas, they are hormonally inactive, and are the most common form of macroadenoma. Pituitary tumours that produce Follicle Stimulating Hormone (FSH) and/or Luteinizing Hormone (LH) are classified as non-functioning adenomas as well.

CASE REPORT

A 26 yr old lady had come to the OPD with complaints of transient blurring of vision in both eyes, lasting for an hour on and off at different intervals of time for a duration of 1 month. There was no other history of any previous systemic illness. Patient had a child birth 1 year

ago and she was still lactating. On examination, patient had a visual acuity of 6/6 in both eyes. Intraocular pressure measurement was normal and slit lamp examination revealed a normal anterior segment. Fundus examination using 90D was normal. The pupillary size, shape and reaction to light were equal in both eyes. Cover test, alternate cover test and convergence tests were within normal limits. The patient was advised to consult the physician and was given nutritional supplements. There was spontaneous resolution of the blurring of vision and the patient was symptom free for 7 months. Seven months later patient came with a history of constant blurring of vision in the right eye for 2 weeks. On examination, patients visual acuity in right eye was 6/24 improving to 6/18 with pin hole and the visual acuity in left eye was 6/6. Pupillary reaction in the right eye showed a RAPD and the left eye pupillary response was normal. Fundus examination of right eye showed mild temporal pallor and the left eye fundus was normal. Colour vision evaluation (Ishihara's chart) was ordered and it was found to be defective in both eyes. This ruled out the possibility of retrobulbar neuritis in the right eye

alone. Field evaluation using Bjerrum's screen (fig.1and2) and Computerized Humphrey field analysis (fig.3and4) showed bitemporal field loss with minimal nasal field involvement in both the eyes. Patient was advised to undergo a MRI scan of the brain and an empirical IV methylprednisolone for 3 days was started along with neuro-vitamins. Patient's visual acuity improved to 6/9 in right eye and with pin hole it improved to 6/6 in both the eyes. The plain and the contrast MRI scan revealed a huge pituitary macroadenoma measuring 34mm (c-c) x 23mm (A-P) x 31mm (M-L) (fig.5, 6, 7and8) which seemed to be occupying sellar and suprasellar regions. No separate pituitary was seen. The lesion was seen to be widening the sella and displacing the surrounding vessels. Patient underwent a neurosurgical endoscopic endonasal trans-sphenoidal pituitary adenoidectomy 1 week after diagnosis. Patient was started with systemic steroids in the dose of 1mg /kg body weight and gradually tapered over a period of 6 weeks. The endocrine levels of cortisol, thyroid, leutinizing and follicle stimulating hormone and prolactin levels were found to be in normal limits.

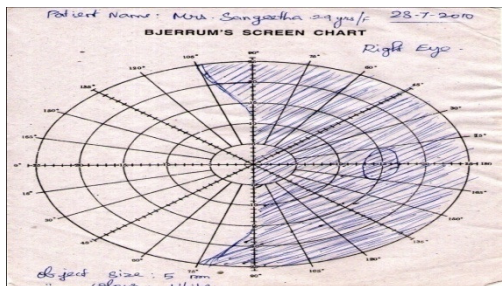


Figure 1: Bjerrum's screen full field of Rt

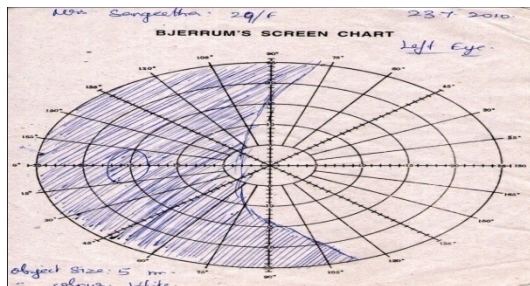


Figure 2: Lt eye showing bitemporal hemianopia

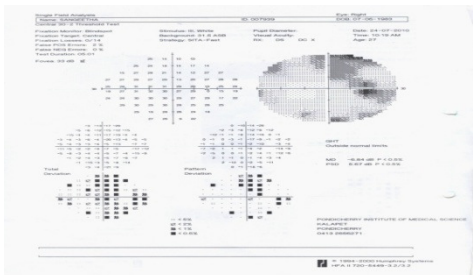


Figure 1: Bitemporal Hemianopia in both right

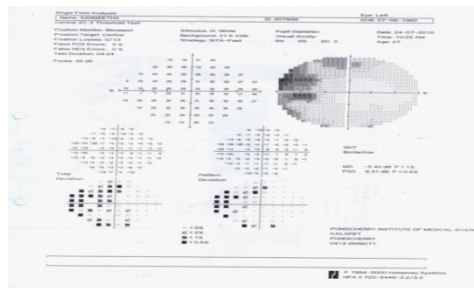


Figure 2: Left eye by computerised Humphrey field analysis

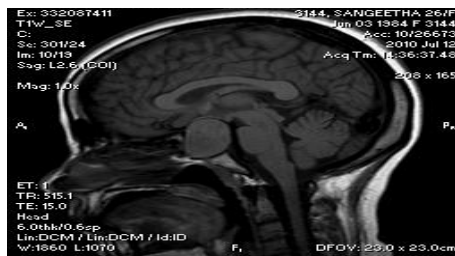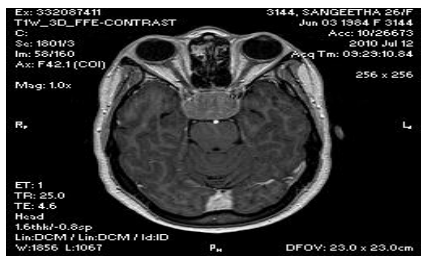


Figure 5 and 6: MRI scan of Brain with and without contrast T1 weighted coronal and sagittal

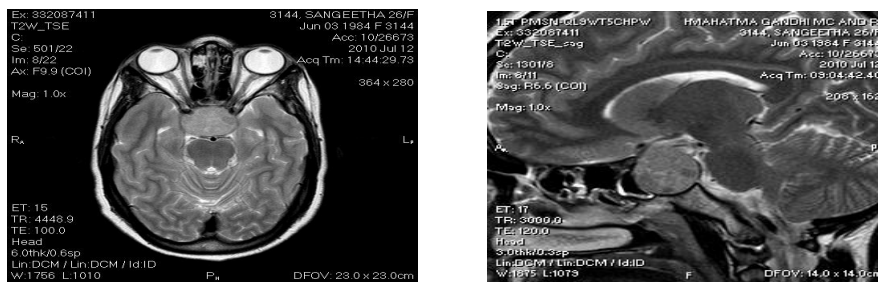


Figure 7 and 8: T2 axial an Sagittal

On review after 3 months, patients visual acuity was 6/6 in both eyes, colour vision by ishihara's chart was found to be normal in both eyes. Bjerrum's screen (fig.9) and Computerized Humphrey visual field assessment showed few isolated depressions (scotomas) in both eye visual fields (fig.10and11). Pupillary response to direct and consensual light reflex was normal in both eyes. Fundus examination showed mild temporal pallor in right eye and normal disc and vessels in left eye.

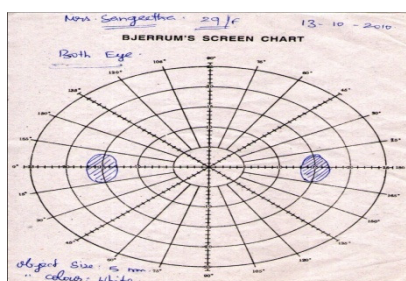


Figure 9: Bjerrum's screen showing disappearance of bitemporal hemianopia following surgical excision of pituitary macroadenoma




Figure 10 and 11: Resolution of the Bitemporal Hemianopia with few isolated scotomas in both eyes in computerized Humphrey field analyser after

DISCUSSION

Depending on the population surveyed, the reported annual incidence of pituitary adenomas varies from 1.0 to 7.6 per 100,000 populations¹. By this statement, pituitary adenomas are not only the dominant form of neoplasia arising in the sellar region, but are also among the most frequent primary intracranial tumors encountered in clinical practice. These figures, derived primarily from neurosurgical series, may underestimate the true incidence of pituitary adenomas, because their frequency in unselected autopsy cases approaches 25%¹. Therefore, it is important that these cases are evaluated and diagnosed with accurate clinical acumen as early surgical removal reduces the mortality and morbidity in these

patients. The cause of pituitary macroadenoma is unknown. The most favoured theory attributes monoclonal neoplastic transformation of pituitary cells as the cause of tumour initiation and growth. The monoclonal nature of most pituitary tumours and their retention of a response to negative feedback by hormones produced by target organs support this hypothesis.² Symptoms of pituitary tumour vary depending on its size and hormone secretion function. The diagnosis of secreting pituitary adenoma is usually obvious because of signs and symptoms characteristic of hormone hypersecretion^{4,6}. The non-secreting pituitary macroadenomas produces symptoms due to compression effects on the optic nerve, optic chiasm and on the sella

tursica. They may present with visual deficits, headache, elevated intra-cranial pressure, or intra-cranial hemorrhage. Pituitary apoplexy results from infarction of a pituitary tumour or sudden hemorrhage within³. This presents as a medical emergency with a headache, sudden collapse, shock and death if not treated urgently. This tends to occur in macroadenomas. Furthermore, the large tumors usually are difficult to remove completely by surgical excision, and recurrences are more frequent than with small, well-demarcated tumors confined to the sella⁷. Bilateral acquired colour vision defects in an eye with acute vision impairment and also in the eye with a normal vision should raise a suspicion of neuro-ophthalmological disorder. Therefore careful and prompt relevant bedside evaluations like colour vision test using Ishihara's chart and field test by Bjerrum's screen should be done apart from the routine visual acuity test, slit lamp evaluation, intraocular pressure measurement and fundus examination in all patients with acute defective vision in one or both eyes.

Key points and Conclusion

- A huge pituitary macroadenoma had been silent for many months without neurological and visual symptoms. The mild blurring of vision had not been further evaluated on the initial visit of the patient. It had spontaneously resolved and the patient was symptom free for 7 months.
- Colour vision evaluation led for the diagnosis of a huge pituitary macroadenoma. Colour vision testing is an easy, less time consuming and less expensive test to the patient. Acquired onset bilateral colour vision defect should raise a suspicion and must prompt further neuro-ophthalmological evaluations.
- Neurosurgical reference and surgical removal of the pituitary adenoma would have been performed earlier to 7 months had colour vision been tested during the initial visit. The patient

might not have had a partial optic disc pallor and atrophy, which is due to the degeneration of optic nerves caused not only by compression-induced edema, but also by compression of the arteries, veins, and capillary networks.

Acknowledgements

Department of Radiology, PIMS,
Mrs. Megaladevi, Ophthalmic technician, the patient and his family.

REFERENCES

1. Thapar K, Kovacs K. Tumors of the sellar region. In Bigner DD, Mc Lendon RE, Bruner JM, eds. Russel and Rubinstein's Pathology of Tumors of the Nervous System, 6th ed. Baltimore: Williams and Wilkins; 1998:561.
2. Alexander JM, Biller BMK, Bikkal H, Zervas NT, Arnold A and Klibanski A 1990. Clinically nonfunctioning pituitary tumours are monoclonal in origin. Journal of clinical investigation 86 336-340.
3. Arafah BM, Ybarra J, Tarr RW, Madhun Z and Selman WR 1997. Pituitary tumour apoplexy: Pathophysiology, clinical manifestations and management. Journal of Intensive care medicine 12 123-134
4. Lamberts SW, de Herder WW, Kwekkeboom DJ, vd Lely AJ, Nobels FR, Krenning EP. Current tools in the diagnosis of pituitary tumours. Acta Endocrinol (Copenh) 1993; 129 Suppl 1:6-12.
5. Pressman BD. Pituitary imaging. In: Melmed S, Ed. The Pituitary. 2nd ed. Boston; Blackwell Science 2002:663-686.
6. Chong BW, Kucharczyk W, Singer W, George S. Pituitary gland MR: a comparative study of healthy volunteers and patients with microadenomas. AJNR Am J Neuroradiol 1994; 15:675-679.
7. Mohr G, Hardy J, Comtois R, Beauregard H. Surgical management of giant pituitary adenomas. Can J Neurol Sci 1990; 17:62-66.
8. Chang CY, Luo CB, Teng MM, *et al.* Computed tomography and magnetic resonance imaging characteristics of giant pituitary adenomas. J Formos Med Assoc 2000; 99:833-838.

Source of Support: None Declared
Conflict of Interest: None Declared