Research Article

Trochanteric fixation nailing for the treatment of unstable osteoporotic intertrochanteric neck femur fractures in elderly patients

Avinash B. Yelne[1], Ulhas V. Sonar[2*], Milind V. Ingle[2], Maruti R. Koichade[3], Naveen Malu[4]

[1]Post graduate student, [2]Assistant Professor, [3]Professor and HOD, [4]Registrar, Department of Orthopaedics, Indira Gandhi Government Medical College, Nagpur, Maharashtra, INDIA.

Email: dr_ulhasortho@rediffmail.com, dr.ulhasortho@gmail.com

Abstract

Objective: To prospectively evaluate results of trochanteric fixation nailing (TFN) in unstable osteoporotic intertrochanteric neck femur fractures in elderly patients. **Method:** Thirty patients, 65 years or older with unstable osteoporotic intertrochanteric neck femur fractures were treated with trochanteric fixation nailing. Results were evaluated by Harris Hip Score. **Results:** Average age of patients was 75.73 ± 6.57 years. Average trauma surgery interval was 5.7 days (range 2 to 12 days). The average surgical time was 74.33 minutes (range 55 to 95 minutes). Average hospital stay was 18.23 days (range 14 to 24 days). Fourteen fractures were A2.2 type rest were A2.3. Twenty seven patients were community ambulator and 3 were household ambulator. The average blood loss was 132.5 millilitres (range 50 to 350 millilitres). Partial weight bearing was achieved in mean 4.77 days (range 2 to 9 days). Full weight bearing was achieved after 49.33 ± 5.47 days (41 to 57 days). Complication included one screw cut out, one superficial infection, two pneumonias, three pressure sores, one varus collapse and two deaths over follow up of one and half years. Functional results using Harris hip score indicated excellent to fair results in all but one patient. **Conclusion:** Trochanteric fixation nailing is effective method of fixation in unstable osteoporotic intertrochanteric neck femur fractures with satisfactory results and reasonably low complication rates.

Keywords: Trochanteric fixation nail, unstable osteoporotic intertrochanteric fractures

[*]**Address for Correspondence:**
Dr. Ulhas Sonar, Assistant Professor, Department of Orthopaedics, Indira Gandhi Government Medical College, C A road, Nagpur, Maharashtra, INDIA.
Email: dr_ulhasortho@rediffmail.com, dr.ulhasortho@gmail.com

Received Date: 20/07/2014 Accepted Date: 02/08/2014

Access this article online	
Quick Response Code:	Website: www.statperson.com
	DOI: 05 August 2014

INTRODUCTION

Intertrochanteric neck femur fractures are the common fractures of elderly population. Due to an increasing life span, the incidence of these fractures is increasing.[1] They are associated with high rates of morbidity and mortality due to the need for prolonged immobilization, although results are improved with use of recent modalities of internal fixation.[2] Operative management is preferred as patients can be mobilized earlier. Prolonged immobilization in this age group can cause complications like deep vein thrombosis, hypostatic pneumonia, pressure sores, dehydration, atelectasis, metabolic disturbances, etc. So these patients have increased morbidity and mortality threshold. The comminuted intertrochanteric fractures being in cancellous area, fixation of all fragments is difficult. The posteromedial void is generally present which makes the fracture very unstable.[3] Resulting instability with combination of osteoporosis makes early resumption of full weight bearing difficult if conventional methods of fixation like Dynamic Hip Screws are used. Recently popular modality is fourth generation of intramedullary nails like the Proximal Femoral Nails.[4] But these are not found to be very suitable in Indian population because of variation in anthropometry of proximal femur. This may lead to an increased difficulty in placement of femoral neck screws. Therefore, Trochanteric Fixation Nail (TFN) which is smaller in size than Proximal Femoral Nail (PFN) was introduced and has been found suitable for Indian population.[5] We have hereby evaluated the results of use of this implant in our population to find out effectiveness of this method of fixation.

How to site this article: Avinash B. Yelne, Ulhas V. Sonar, Milind V. Ingle, Maruti R. Koichade, Naveen Malu. Trochanteric fixation nailing for the treatment of unstable osteoporotic intertrochanteric neck femur fractures in elderly patients. *International Journal of Recent Trends in Science and Technology* August 2014; 12(1): 77-81 http://www.statperson.com (accessed 06 August 2014)

MATERIAL AND METHODS

This study comprises a series of unstable osteoporotic intertrochanteric neck femur fractures treated by Trochanteric Fixation Nail (TFN) at our institute. Thirty patients aged sixty five years or more having unstable osteoporotic intertrochanteric neck femur fractures who are willing to participate in study were included in the study. Thorough history regarding age, gender, mode of trauma, occupation, time since injury, associated medical illness and pre-injury morbidity was taken. Examination assessing the general condition of the patient, vital parameters, associated life-threatening systemic injuries as well as other associated orthopaedic injuries was done. Clinical examination evaluating site of trauma, with special consideration for swelling, condition of distal joints, neurovascular status of the limb was done. Associated co-morbidities were noted. AO/ASIF classification (A1-A3) was used to classify the fractures.

Trochanteric Fixation Nail (TFN):

All parts of the TFN implant are made up of a stainless steel 316L type. The system consists of cannulated nail, cannulated hip screws of sizes 8 millimetres and 6.4 millimetres and locking bolts (4.9 millimetres). There is a locking mechanism in the upper part of the nail to control the rotation of the hip screw. The proximal diameter of the nail is fifteen millimetres. Length of nails is 180 millimetres. The diameter varies from nine to twelve millimetres. All nails have an anatomical valgus angle of six degrees. All parts of the nail are cannulated allowing insertion over guide wire. The angle between the nail and hip screws are available in 130 and 135 degrees. In the nail, there are two holes distally for static and dynamic locking. The locking bolts have a diameter of 4.9 millimetres.

Operative protocol:

All patients were operated under regional anaesthesia.

Surgical Procedures:

Patients were placed in a supine position under spinal or epidural anaesthesia, with the trunk deviated to the opposite side on fracture table. Closed reduction was achieved and confirmed under C-arm. Three to five centimetres incision was made just proximal to the tip of greater trochanter parallel to the femoral shaft. Entry was made with a curved awl just lateral to the tip of greater trochanter. A guide wire was passed through the entry point across the fracture site. It was reamed gradually to the size according to canal diameter. Entry point was reamed with entry reamer of large size to accommodate the nail tip. The nail of size less than one millimetres of largest reamer used was mounted on a radio-opaque jig depending on the neck shaft angle of the opposite hip. Guide wires were passed through proximal holes. Their position was confirmed under C-arm in two orthogonal views. Proximal locking was achieved through one stabilization screw and one compression screw of 6.4 millimetres and 8 millimetres respectively. Distal interlocking entailed both static and dynamic holes. The wound was closed in layers. Sterile dressing was applied.

Post operative protocol:

Intravenous antibiotics were given for five days in immediate postoperative period followed by oral antibiotics for eight days. Antibiotics were continued for few more days in case of infection. Analgesics were added as per need. Immediate postoperative limb elevation was given. Wound was checked and dressed on third and fifth postoperative day. Sutures were removed between 12-14 days. Early mobilization was begun within limits of pain tolerance. Active, assisted and active range of motion exercises proved to be valuable adjuvant for achieving good range of motion. All patients were advised partial weight bearing with a walker for a period of six to eight weeks. Patients were allowed full weight bearing after radiological evidence of fracture union. X-rays were taken at regular intervals and evaluated for fracture healing alignment, screw breakage or screw back-out, cut-out, varus malunion collapse. Clinical union was defined as a painless fracture site during full weight bearing. Radiographic union was defined as bridging trabeculations across the fracture line on two orthogonal views in the absence of migration, loosening or breakage of hardware. Cases were followed up until one and half year. Functional assessment of patients was done using Harris Hip Scoring system; formulated by W.H Harris as described in Table no.1.[5]

OBSERVATION AND RESULTS

Out of thirty patients two could not complete the study, as they expired due to myocardial infarction. Thus a total study of twenty eight patients was carried out. Patients were followed up at three months, six months, one year and one and half year.

In our study we derived the following results:

Average age of patients was 75.73 ± 6.57 years. There were eighteen male patients, rest were females. The youngest patient in our series was sixty seven years old and the oldest was ninety two years old. Seventeen fractures involved right side. Rest fractures were left sided. Average trauma surgery interval was 5.7 days (range 2 to 12 days). The average surgical time was 74.33 minutes (range 55 to 95 min). Average hospital stay was 18.23 days (range 14 to 24 days). Fourteen fractures were A2.2 type rest were A2.3. Out of thirty patients, twelve patients were suffering from hypertension with ischaemic heart disease, seven patients were suffering from diabetes

mellitus, four patients were suffering from both hypertension and diabetes mellitus, three patients had cataract and two patients had chronic obstructive pulmonary disease (COPD). Twenty seven patients were community ambulator and three were household ambulator. The average blood loss was 132.5 milliliters (range 50 to 350 milliliters). Partial weight bearing was achieved in mean 4.77 days (range 2 to 9 days). Full weight bearing was achieved after 49.33 ± 5.47 days (41 to 57 days). In our series most of the complications were minor and resolved with minimal interventions without causing any lasting morbidity. There was one case of screw cut out which was later revised with total hip replacement. There were no cases of periprosthetic fractures. Complications are depicted in table no. 2. Two patients expired during period of follow up. So the final functional assessment of twenty eight patients was done at the last follow-up at one and half years. Functional results using Harris hip score at three months, six months, one year and at one and half year are depicted in table no 3,4, 5 and 6 respectively.

DISCUSSION

Outcomes of treatment of intertrochanteric fractures depends on quality of bone, age of patient, general health, trauma surgery interval, and adequacy of treatment, co-morbidities and stability of fixation.[6,7,8] Intertrochanteric fractures in the elderly pose certain special problems. In this age group the fracture configuration is generally comminuted with presence of extensive osteoporosis. There is problem with correct and accurate placement of the implant and hold of the implant. So if the fixation is not stable, prolonged immobilization may be required to achieve complete union. On the other hand there is a need for rapid weight bearing and mobilization of this group of patients as they are generally medically compromised due to age and associated diseases. Biological and biomechanical changes that occur in osteoporosis make the management of these fractures more difficult. Cancellous bone has reduced bone mineral density and changes in trabecular pattern. Cortical bone also becomes thin. So in these comminuted fractures in cancellous areas, fixation of all fragments is difficult. Also the posteromedial void which is usually present in these fractures makes them very unstable. Thus implant fixation is compromised.[9] Literature concerning the treatment and results of unstable osteoporotic intertrochanteric fracture of the hip is extensive. But despite the publication of reports of randomized trials[10] and comparative studies.[6,11,12] Treatment of unstable intertrochanteric fractures in elderly patients is still controversial. Holi Dimon and Hughston, Sarmeinto and Willams have done outstanding work in attempt to change an unstable intertrochanteric fracture into a stable one and fix it with a device until it heals. The reported complication rate for treating unstable intertrochanteric fractures range from 18-50%.[13,14] Elderly patients even if they are in good health cannot usually be mobilized without some weight bearing on the involved limb. This has led to periodic introduction of various designs and stable implants. Proximal femoral nail (PFN) was developed by AO/ASIF in 1996. It was designed to overcome implant related complications, especially in treatment of unstable peritrochanteric fractures. It is an intramedullary device. The proximal femoral nail uses two hip screws for fixation into the femoral head and neck. The distal larger screw is intended to carry the majority of the load. The smaller proximal screw is inserted to provide rotational stability. Anthropometry of proximal femur in Indian population is different from western population. Generally, it is deemed smaller than that of Caucasian population as the build of our population is smaller as well. So there appeared a need of design suitable for Indian Population. TFN is one such design introduced considering anthropometry of Indian population. It is smaller in size than PFN. It acts as a buttress to prevent medialisation of the shaft and provides more efficient load transfer.[15] It is designed to provide linear intraoperative compression of head neck segment to shaft along with rotational stability which minimizes neck malunions, resulting in negligible complication rate.[16] It also reduces stress concentration at the tip and the smaller distal diameter may prevent femoral shaft fractures. [17]It has been proved to be a superior implant compared to previous implants for stable and unstable intertrochanteric fractures in terms of operating time, surgical exposure, blood loss, and complication rates.[18] Latest design of Trochanteric fixation nail (TFN) has been introduced by Synthase in 2002. It uses a helical blade instead of lag screws. We treated 30 patients with trochanteric fixation nailing and evaluated results of this mode of treatment in Indian population. There were no cases of periprosthetic fractures probably related to smaller size of implant. Complications we noted were related to osteoporosis and age related morbidities of patients. There was one case of screw cut out which had to be revised with total hip replacement. There was one case of varus collapse. Three patients developed pressure sores and two patients suffered pneumonia which required medical management. There was one case of superficial infection improved with debridement and course of antibiotic. There were two deaths over period of one and half years. We derived excellent to fair results in all but one patient. Results improved gradually over period of one and half years follow up.

Table 1: Harris Hip scoring for functional evaluation of Hip

Point scale with maximum of 100 points distributed as follows		
	Pain	44
	Function	47
	Range of motion	05
	Absence of deformity	04
	Total	**100**
I	**PAIN**	**44**
1	Totally disabled, crippled, pain in bed, bedridden	00
2	Marked pain, serious limitation of activities	10
3	Moderate plain, tolerable but makes concession to plain	20
4	Mild pain, no effect on average activities	30
5	Slight, occasional, no compromise in activity	40
6	None, or ignores it	44
	Total	
II	Function	47
A	Distance walked	
1	Bed and chair only	00
2	Two or three blocks	05
3	Six blocks	08
4	Unlimited	11
B	Activities	
	Shoes and Socks	
1	Unable to fit or tie	00
2	With difficulty	02
3	With ease	04
	Public transportation	
1	Unable to use public transportation (bus)	00
2	Able to use transportation (bus)	01
	Limp	
1	Severe or unable to walk	00
2	Moderate	05
3	Slight	08
4	None	11
	Support	
1	Two crutches or not able to walk	00
2	Two canes	02
3	One crutch	03
4	Cane most of the time	05
5	Cane for long walks	07
6	None	11
	Stairs	
1	Unable to do stairs	00
2	In any manner	01
3	Normally using a railing	02
4	Normally without using a railing	04
	Sitting	
1	Unable to sit in any chair comfortably	00
2	On a high chair for 30 min	03
3	Comfortably on a ordinary chair for one hour	05
	Total	
	Motions	
III	Flexion+ Abduction + Adduction+ External rotation + internal rotation=	05
1	00 to 29°	00
2	30 to 59°	01
3	60 to 99°	02
4	100 to 159°	03
5	160 to 209°	04
6	210 to 300°	05
	Total	
IV	Deformity	04
1	Flexion deformity 30° of more	00
2	Flexion deformity less than 30°	01
1	Fixed adduction 10° more	00
2	Fixed adduction less than 10°	01
1	Fixed internal rotation(in extension) 10°or more	00
2	Fixed internal rotation(inextension) less than 10°	0
1	Limb length discrepancy more than or equal to 3.2 cms	00
2	Limb length discrepancy less than 3.2cms	01
	Total	
	Total of I+II+III+IV	**100**

The score is reported as follows	
HHS between 90 to 100	Excellent results
HHS between 80 to 89	Good
HHS between 70 to 79	Fair
HHS between 60 to 69	Poor, and
HHS below 60	As a failed result

* HHS: Harris Hip Score

Table 2: Complications in two groups

Complications	TFN
Sciatic nerve palsy	0
Pressure sores	3
Pneumonia	2
Sup infection	1
Deep infection	0
Cutting out of screws	1
Shortening	0
Death	2
Periprosthetic fracture	0
Varus collapse	1
Revision Surgery	1
Deep venous Thrombosis	0

Table 3: Functional results at 3 months

Results	TFN
Excellent (HHS 90-100)	2
Good (HHS 80-89)	15
Fair (HHS 70-79)	11
Poor (HHS 60-69)	2
Failed (HHS below 60)	0

*HHS: Harris Hip Score

Table 4: Functional results at 6 months

Results	TFN
Excellent (HHS 90-100)	9
Good (HHS 80-89)	12
Fair (HHS 70-79)	6
Poor (HHS 60-69)	2
Failed (HHS below 60)	0

* HHS: Harris Hip Score

Table 5: Functional results at 1 year

Results	TFN
Excellent (HHS 90-100)	13
Good (HHS 80-89)	9
Fair (HHS 70-79)	4
Poor (HHS 60-69)	2
Failed (HHS below 60)	0

* HHS: Harris Hip Score

Table 6: Functional results at 1 and ½ years

Results	TFN
Excellent (HHS 90-100)	16
Good (HHS 80-89)	9
Fair (HHS 70-79)	2
Poor (HHS 60-69)	1
Failed (HHS below 60)	0

* HHS: Harris Hip Score

Figure 1

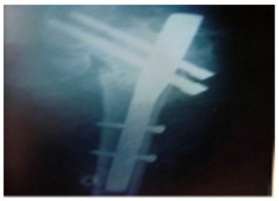

Figure 2

Figure a

Figure b

Figure c

Legend

Figure 1: Instruments for Trochanteric Fixation Nailing

Figure 2: X ray showing varus collapse

Figure a: Pre operative X ray

Figure b: Post operative X ray

Figure c: Union at three months

CONCLUSION

Trochanteric fixation nailing is effective method of fixation in unstable osteoporotic intertrochanteric neck femur fractures with satisfactory results and reasonably low complication rates.

ACKNOWLEDGEMENT

Authors acknowledge the immense help received from scholars whose articles are cited and included in references of this manuscript. The authors are also grateful to authors/editors/publishers of all those articles, journals, books from where the literature for this article has been reviewed and discussed.

REFERENCES

1. Koval KJ, Aharonoff GB, Rokito AS, *et al*. Patients with femoral neck and intertrochanteric fractures. Are they the same? Clin Orthop Relat Res.1996; 330:166-172.
2. Campbell's operative orthopedics; Philadelphia: Mosby Elsevier; 2008.Vol 3; 11th edition: 3239-3256.
3. Grisso JA, Kelsey JI, Strom BL, and Chio GY. Risk factors for falls as a cause of hip fractures in women. New England journal of medicine. 1991; 324:1326-1331.
4. Meislin RJ, Zuckerman JD, Kummer FJ, *et al*. A biomechanical evaluation of the gamma nail. J Bone Joint Surg.1998; 70-A: 239.
5. Anchal Kumar. Femoral neck geometry and rationale of placement of the proximal femoral nail and its relation with fracture risk in the Indian population review of 120 cases. 2010: Gulmohar Hospital, Ranchi.
6. Kyle RF, Gustilo RB, Premer PF. Analysis of Six hundred and Twenty–two intertrochanteric Hip Fractures. J. Bone Joint Surg. 1979 March; 61-A: 216-21.
7. Dahl E. Mortality and life expectancy after hip fractures. Acta Orthop Scand. 1980 Feb; 51(1)163-70.
8. Kaufer H. Mechanics of the treatment of hip injuries. Clin Orthop Relat Res. 1980 Jan-Feb;146:53–61.
9. Grisso JA, Kelsey JI, Strom BL, and Chio GY. Risk factors for falls as a cause of hip fractures in women. New England journal of medicine. 1991; 324:1326-1331.
10. Ender J, Simon-Weidner R. Die Fixierung der trochanteren Bruche mit runden elastischen Condylennageln. Acta chir Austriaca 1970; l: 40-42.
11. Cleas H, Broos P, Stappaerts K. Pertrochanteric Fractures in Elderly patient Treatment with Ender's nail, blade-plate or endoprosthesis? Injury. 1985; 16(4):261-64.
12. Heyse-Moore G.H, MacEachen AC, and Jameson Evans DC. Treatment of trochanteric fractures of the femur. J Bone Joint Surg. 1983; 65-B: 262-267.
13. Sarmiento. Intertrochanteric fractures of femur 150-degree angle nail plate fixation and early rehabilitation, a preliminary report of 100 cases. J Bone Joint Surgery.1963 June; 45-A: 706-722.
14. Dimon JH, Hughston JC. Unstable intertrochanteric fractures of hip. J Bone Joint Sug.1967; 49-A: 440-450.
15. Morihara T, Arai Y,Tokugawa S, Fujita S, Chatani K, Kubo T. Proximal femoral nail for treatment of trochanteric femoral fractures. Journal of Orthopaedic Surgery 2007; 15(3):273-7.
16. Ruecker AH, Rupprecht M, Gruber M, Gebauer M, Barvencik F, Briem D, Rueger JM: The treatment of intertrochanteric fractures: results using an intramedullary nail with integrated cephalocervical screws and linear compression. J Orthop Trauma. 2009; 23(1):22-30.
17. Bienkowski P, Reindl R, Berry GK, Iakoub E, Harvey EJ: A new intramedullary nail device for the treatment of intertrochanteric hip fractures: Perioperative experience. J Trauma. 2006; 61(6):1458-62.
18. Gill JB, Jensen L, Chin PC, Rafiei P, Reddy K, Schutt RC Jr : Intertrochanteric hip fractures treated with the trochanteric fixation nail and sliding hip screw. J Surg Orthop Adv. 2007; 16(2):62-6.

Source of Support: None Declared
Conflict of Interest: None Declared