

Schizencephaly: a case report of a rare developmental disorder of brain

Kapil S. More^{1*}, Vijaykumar R. Kapse², Sonali Kagne³, Deepak Kubde⁴

{¹Assistant Professor, ^{3,4}Resident, Department of Medicine} {²Assistant Professor, Department of Pulmonary Medicine}
Dr S.C.G.M.C., Nanded, Maharashtra, INDIA.

Email: kapilmore114@gmail.com

Abstract

Introduction: Schizencephaly is an extremely rare developmental disorder of the brain. Its prevalence in Indian data is 1.5: 1,00,000 population. It is a triad of hemiplegia, seizure disorder and mental retardation. Hence we are reposting a case of 28 yrs. old female who presented with intractable seizures and altered sensorium for 2 days. She is a known case of epilepsy since the age of two months. She also had left sided hemiparesis since the same duration. She had delayed developmental milestones and mental retardation. Her, CT brain was done. It showed large fluid filled cavity occupying right frontal, temporo- parietal region lined by grey matter communicated with right ventricle. These findings are consistent with right sided unilateral open-lip schizencephaly.

Keywords: Schizencephaly, Hemiplegia, Seizure Disorder, Mental Retardation

*Address for Correspondence:

Dr Kapil S. More, Assistant Professor, Department of Medicine, Dr S.C.G.M.C., Nanded, Maharashtra, INDIA.

Email: kapilmore114@gmail.com

Received Date: 06/07/2014 Accepted Date: 16/07/2014

Access this article online

Quick Response Code:	Website: www.statperson.com
	DOI: 17 July 2014

INTRODUCTION

Schizencephaly is an extremely rare developmental disorder of the brain. Its prevalence in Indian data is 1.5: 1,00,000 population. It is a triad of hemiplegia, seizure disorder and mental retardation.

Listed as RARE DISEASE by office of rare diseases of National institute of health.

- Incidence is 1.5 /1,00,000 live birth
- In literature 70 cases of type 2 schizencephaly has been reported

Exact incidence of type 1 is not known
SCHIZENCEPHALY (SPLIT BRAIN)

Yakovlev and **Wadsworth** coined the term "schizencephaly" in year 1946.

CASE REPORT

28 Year old Hindu female, with H/o generalised tonic clonic convulsions- since the age of 2 mths, NOW presented to us with intractable seizure episodes for last 2 days. Patient was in altered sensorium with Left hemiparesis since 2 days. In Past history- H/O recurrent generalised tonic clonic convulsions 2-3 episodes /month associated with post ictal phase of 4 hrs. She was started on some Aurvedic medicines by Local Aurvedic practioner last few years. She was never investigated for her illness in past before visiting our institute. In Antenatal History, She is a Product of non-consanguineous marriage with full term normal vaginal home delivery. Mother also gives history of delayed milestones like- i)Walking at the age at of 5 years ii)Talking at the age of 6 years iii)Running at the of 7 years iv) Understanding full sentence at the age of 8 years v) Performance in the school was below average. In Personal History, She was Having normal menstrual history. Her Sleep, appetite, bowel and bladder habits were normal. There was no history of Headache, Visual disturbance, dysphagia, diplopia , Vertigo, tingling numbness, Chest pain, palpitation, syncope, shortness of breath , Jaundice, arthralgia, arthritis, skin rash , Otorrhia, rhinorrhia.



Figure 1: Photograph of Patient with Schizencephaly

On General Examination, Patient was conscious, co-operative, comfortable in supine position PR-78 bpm, regular, BP-110/70 mm of Hg, Dacrocystitis of right eye is present, No clubbing, cynosis, icterus, paller, lymphadenopathy, edema fee, No skull, spine, skin or nail abnormality, No neurocutaneous markers were present. On Systemic Examination, CVS, RS, and Per Abdomen – No Abnormality was detected. On Central Nervous System Examination, Higher function like Consciousness, Behavior and Memory all were in normal limits. Her Intelligence was average; Mini Mental Examination Score was 26. Her Cranial nerve examination, Sensory system examination were within normal limits On Motor system Examination there was Left spastic hemiparesis with grade 2/5 power in upper limb and 4/5 in left lower limb. Left Deep Tendon Reflexes were exaggerated, left planter- extensor and Right sided all deep tendon reflexes were Witin Normal Limits.

Investigations

Hb-10.5gm, CBC-7800cu/mm Platelet Count – 1.7 Lakhs Serum bilirubin- 0.7 mg, Serum urea- 0.9mg, Serum creatinine- 0.8mg. CT Brain [Plain] was suggestive of - Large fluid filled cavity occupying right frontal parietal region lined by grey matter and communicated with right ventricle. All Finding s/o.large open cleft schizencephaly.

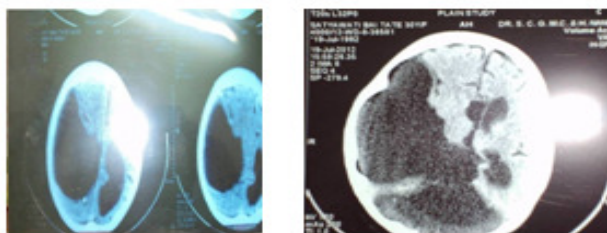


Figure 2 and 3: CT Images of Brain Showing Large Open Cleft Schizencephaly

DISCUSSION

Schizencephaly is a rare developmental disorder of the brain characterized by abnormal continuity of histological gray matter tissue extending from ependyma lining of the cerebral ventricular to the pial surface of cerebral hemisphere surface.

Types of Schizencephaly

Type I /Fused Cleft /Closed cleft Schizencephaly. It has a cord of gray matter tissue either with no fluid cleft or with

ventricular or cortical lips closing one end of an abnormal fluid cleft through the hemisphere¹. Type II /Open lip Schizencephaly. It is more common than type I Schizencephaly. It shows a cerebrospinal fluid filled cleft of varying size and shape extending through the hemisphere from the ependyma centrally to the pia peripherally¹.

Associated Neurological Malformations

- i) Gray matter heterotopia (collection of gray matter in abnormal location)
- ii) Polymicrogyria (abnormal brain tissue with high density of foldings)
- iii) Arachnoid cysts
- iv) Absence of septum pellucidum (80-90%)
- Cortical dysplasia⁷.

Etiology of Schizencephaly

The exact etiology is not known. The likely causes may be Genetic (thought to be associated with EMX2 Gene)⁵ and Physical insults like Infection, infarction, hemorrhage, toxin, mutations^{2,3}.

Pathogenesis

Schizencephaly is probably a disorder of normal neuronal migration during second trimester of intruterine development, when primitive neuron precursors(germinal-matrix)migrate from just beneath the ventricular ependyma to the peripheral hemispheres where they form the cortical grey matter. Gray matter contains neuronal cell bodies and dendrites whereas white matter contains axons, which are coated in myelin.

Clinical Presentations

Individuals with clefts in both hemispheres, or bilateral clefts presents with – i) developmentally delayed ii)delayed speech and language iii) corticospinal dysfunction iv) Microcephaly, mental retardation v) Seizures and spastic quadriplegia . Individuals with unilateral clefts presents with- i) hemiparesis ii) average or near average intelligence iii) seizure disorder Treatment of Schizencephaly involves i) Physiotherapy to involved extremity in hemiparesis ii) Occupational Therapy for rehabilitation iii) Treatment of seizures with oral antiepileptics and iv) Surgical management in the form of Shunt for hydrocephalous⁴. Complications of Schizencephaly are i) Optic nerve hypoplasia⁶ ii)Skull deformity iii)Learning disability iv) seizures⁷

Prognosis

The prognosis of individuals with schizencephaly varies depending on the size of neurological deficit.

- Bilateral clefts are associated with earlier onset of seizures that are more difficult to treat.
- Patients with open-lip schizencephaly die at an earlier age than those with closed-lip form.

REFERENCES

1. Denis D, Chateil JF, Brun M, Brissaud O, Lacombe D, Fontan D, Flurin V, Pedespan J. Schizencephaly: Clinical

- imaging features in 30 infantile cases. *Brain Dev* 2000 Dec; 22(8):475-83
2. Iannetti P, Nigro G, Spalice A, Faiella A, Boncinelli E. Cytomegalovirus infection and schizencephaly: case report *Ana Neuronal* 1998 Jan; 43(1); 123-7
 3. Pati S, Helmbrecht GD. Congenital schizencephaly associated with utero warfarin exposure *Reprod Toxicol* 1994 Mar- Apr 8(2): 115-20
 4. Capra-V; De-Marco-P; Moroni-A; Faiella- A; Brunelli-S; Tortori-Donati-P; Andreussi- I; Boncinelli-E; Cama-A Schizencephaly: Surgical features and new molecular genetic results. *Emr J Pediatr Surg* 1996 Dec; suppl 1:27-9
 5. Al-Qudah-AA Clinical patterns of neuronal migration disorder and parental consanguinity. *J T Prop Pediatr.*1998 Dec; 44(6): 351-4
 6. Gasparetto EL, Warszawiak D, de Carvalho Neto A, Benites Filho PR, Bruck I, Antoniuk S. Septo optic dysplasia plus a case report. *Arq Neuropsiquitar* 2003 Sep; 671-6
 7. Hayashi N, Tsutsumi Y, Barkovich AJ. Morphological features and associated anomalies of schizencephaly in the clinical population: detailed analysis of MR images. *Neuroradiology* 2002 May; 44(5): 418-27

Source of Support: None Declared
Conflict of Interest: None Declared