

Computed tomography evaluation of acute pancreatitis, its complications and CT severity index

Nitin Bhutada^{1*}, Sunita Zanwar², Anup Wakodkar³

¹Medical Officer, Department of Radiology, Indira Gandhi Government Medical College, Nagpur, Maharashtra, INDIA.

^{2,3}Medical Officer, Department of Radiology, Department of Surgery, Government Medical College, Nagpur, Maharashtra, INDIA.

Email: bhutadanitin@gmail.com

Abstract

Aims and objectives: 1) Morphology of pancreas in various grades of Acute pancreatitis 2) Complications of pancreatitis like pseudocyst, abscess, phlegmon formation and vascular complications (pseudoaneurysm and venous thrombosis) etc. 3) Grading the severity of disease using CTSI and Modified CT severity index (CTSI) **Materials and Methods:** This prospective study of 100 patients suspected of pancreatitis will be evaluated with two slice spiral CT scanner, somatom, Siemens (Germany) at Tertiary care centre, from August 2012 to October 2013. The series consists of patients of pancreatitis which were clinically diagnosed and sent directly for CT examination and the patients in whom abdominal ultrasound examination was suggestive of pancreatitis. Helical CT is an effective modality for imaging the pancreas with faster scanning time and no respiratory misregistration. Pancreas if scanned during the peak parenchymal enhancement phase, helps in better morphological characterization of pancreas and detection of pancreatic necrosis. Helical CT effectively detects the different non vascular and vascular complication of pancreatitis. Grading of acute pancreatitis according to the severity of the disease in the form of Modified CTSI which will predict the clinical outcome of the disease could be done effectively with helical CT.

Keywords: CTSI (CT severity index), Modified CTSI (Modified CT severity index)

*Address for Correspondence:

Dr Nitin Bhutada, Medical Officer, Department of Radiology, Indira Gandhi Government Medical College, Nagpur, Maharashtra, INDIA.

Email: bhutadanitin@gmail.com

Received Date: 12/09/2014 Accepted Date: 25/09/2014

Access this article online

Quick Response Code:



Website:

www.statperson.com

DOI: 29 September
2014

INTRODUCTION

Diseases of the pancreas have very variable presentation and hence imaging plays important role in the diagnosis and management of the pancreatic diseases. Modalities for imaging the pancreas range from humble plain x-ray to contrast studies, ultra sonography (USG), endoscopic ultrasound, endoscopic retrograde cholangio-pancreatography (ERCP), computed tomography (CT), magnetic resonance imaging (MRI) and magnetic

resonance cholangio-pancreatography (MRCP). CT is the modality of choice for the noninvasive imaging of pancreas as it is unaffected by bowel gas and large body habitus. The CT severity index, an extension of the CT classification system, attempts to improve the prognostic value of CT in acute pancreatitis. The severity index is a scoring system that combines CT grading and the percentage of necrosis to obtain a number that correlate with risk of developing serious local complications such as abscess or infected necrosis, which in turn correlate with increased incidence of morbidity and risk of death. The modified CT severity index in relation to earlier CT scoring system includes features reflecting organ failure and extra pancreatic complications for predicting course. This index includes presence or absence of acute fluid collection rather than count of collections, it scores necrosis as absent, minimal (< 30%), or substantial (> 30%), and it take into consideration extrapancreatic findings such as pleural fluid, ascitis, extrapancreatic parenchymal abnormalities, vascular complications, or involvement of the gastrointestinal tract. This study was

undertaken to assess the role of spiral CT in the evaluation of pancreatitis, its complications and severity scoring by using Modified CT severity scoring index.

MATERIAL AND METHODS

The series consists of patients of pancreatitis which were clinically diagnosed and sent directly for CT examination and the patients in whom abdominal ultrasound examination was suggestive of pancreatitis. The series consists of patients 100 clinically diagnosed patients in whom abdominal ultrasound examination was suggestive of pancreatitis and sent directly for CT examination. CT examination was performed on multi detector CT Somatom Volume Access; Siemens Medical system, Forchheim, Germany, at Indira Gandhi Government Medical College and Hospital, Nagpur. The scanner has a single slice configuration with gantry rotation time of 0.8 seconds. Medrad vistrion CT pressure injector system was employed for IV contrast material administration. Non ionic contrast i.e. Ultravist 350 mg% in a dose of 100 ml (1.5 ml/kg) at injection rate of 3 ml/sec. was used.

Image Analysis and Data Analysis

CT scans were retrospectively and independently reviewed on workstation by two experienced abdominal radiologists who were unaware of presenting signs and symptoms or of patient outcomes. The severity of the pancreatitis for each case was assessed by each observer using the Modified CT severity index. This index includes simplified evaluation of the presence and number of fluid collections and the extent of pancreatic necrosis and presence of extrapancreatic findings, such as pleural fluid, ascites, vascular complications (venous thrombosis, arterial hemorrhage, or pseudo aneurysm formation), and involvement of the gastrointestinal tract (inflammation, perforation, or intramural fluid collection). Using this modified index, the severity of pancreatitis for each patient was then categorized as mild (0–2 points), moderate (4–6 points), or severe (8–10 points). The Inter-observer agreement for assessing the severity of pancreatitis (mild, moderate, or severe) with modified CT severity index was expressed for reviewers (observer 1 and observer 2) by means of the exact percentage agreement, along with the kappa statistic, which is used to estimate the proportion of inter-observer agreement above that expected by chance. A weighted kappa statistic of 0.41–0.60 was considered to indicate moderate agreement, 0.61–0.80 was considered to indicate good agreement, and 0.81–1.00 was considered to indicate excellent agreement

Outcome Parameters

Outcome parameters were collected from the hospital and radiology information systems and included the length of the hospital stay (in days), need for surgical intervention,

need for percutaneous intervention (aspiration and drainage), evidence of infection in any organ system (positive results on a Gram stain or culture or the combination of a fever $>100^{\circ}\text{F}$ and an elevated WBC $>15,000/\text{mm}^3$), and evidence of organ failure. Patient records were retrospectively reviewed for the presence or absence of dysfunction in six separate organ systems as defined by Fagon *et al*⁶⁸.

RESULTS

The demographic characteristics of patients were as shown in table no.1 Pancreatitis was more common in male than in female (M: F; $\sim 3.5:1$). Commonest age group affected was 3rd to 5th decade. 22 patients were female and shown only less variations in the age distribution with mild increase in incidence in middle age group, between 3rd to 5th decades

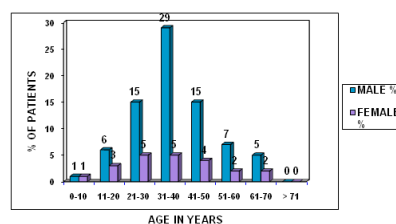


Figure 1: Age Distribution

Etiology

In males, Alcohol found to be most common etiological factor for acute pancreatitis with 64 (82%) out of 78 male patients. Biliary pathologies contributed as a cause of acute pancreatitis only in minor number of male patients (6.4%). In females, Biliary pathologies are found to be the most common etiological factors with 7 (31.8%) out of 22 female patients. Etiological factors other than biliary pathologies (Metabolic disorders, Autoimmune, Infectious and others) were found to be the major cause for acute pancreatitis in female patients (68.2%).

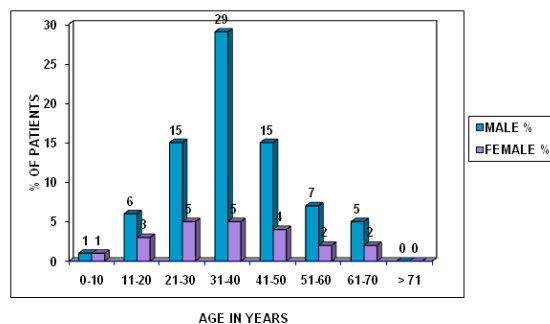


Figure 2: Age Distribution

Table 1

Complications		NO.	%
Pseudocyst		27	27
Necrosis	< 30%	15	15
Presence of gas/abscess	> 30%	9	9
GI tract and biliary involvement		8	8
Solid organ involvement (spleen, kidney and liver)		5	5
Thoracic complications (effusion, mediastinal pseudocyst and etc)		4	4
Vascular and hemorrhagic complications		11	11
Ascites		9	9

Complications

Acute fluid collection was both intrapancreatic and extrapancreatic like in lesser sac, anterior pararenal space or subperitoneal space. 17 patients had single fluid collection while 35 patients had two or more fluid collections. Most common site for peripancreatic inflammatory change was anterior pararenal space. Among the 100 cases 41 patients (41%) developed complications. Out of 100 patients 27 (27%) developed pseudocysts on follow up and appears to be the most common complication. Among 27, 19 (70.3%) were simple and 8 (29.7%) were complex pseudocyst. Pancreatic necrosis was found in 24 (24%) patients. Among 24 patients, necrosis was sterile in 19 (79.1%) cases and infected in 5 (20.9%) cases. Pancreatic abscess found in 8 (8%) patients. GI tract and biliary involvement found in 7 (7%) cases. GI tract involved more commonly than biliary system. Duodenum commonly (3%) involved in GI tract. Solid organ involvement found in 4 (4%) cases. Spleen, kidney and liver involved. Thoracic complications were found in 11(11%) cases. All of them have pleural effusion. Out of total 11 patients eight patients had left sided, two patients had bilateral and only one patient had isolated right pleural effusion. Others were mediastinal pseudocyst and pleuropancreatic fistula. Vascular and hemorrhagic complications were found in 7 (7%) cases. Portal vein thrombosis in 1 patient and splenic vein thrombosis in 2 patients. Splenic artery pseudoaneurysm (1 case).Gastroduodenal artery pseudoaneurysm (1case) Intracystic hemorrhage (3 cases).Two patients have hemorrhagic Pancreatitis. Pancreatic ascites was found in 8 (8%) cases. The

modified CT severity index in relation to earlier CT scoring system includes features reflecting organ failure and extrapancreatic complications for predicting course. This index includes presence or absence of acute fluid collection rather than count of collections, it scores necrosis and it take into consideration extrapancreatic findings such as pleural fluid, ascitis, extrapancreatic parenchyma abnormalities, vascular complications, or involvement of the gastrointestinal tract. Necrosis is defined as areas of less than 30 HU enhancement of pancreatic parenchyma on CECT. In Present study total 24 patients (24%) shown pancreatic necrosis, among which 15 patients had < 30% necrosis noted 9 patients had > 30% necrosis.

Severity of Pancreatitis

Using the currently accepted CT severity index, the observers graded the severity of the acute pancreatitis as mild in 61, moderate in 31, and severe in 8 patients. Interobserver agreement on these observations ranged from 74% to 83% (mean,78%). The kappa statistic for each pair of observers ranged from 0.48 to 0.70, indicating moderate to good agreement. In none of the cases was the severity of the pancreatitis scored differently by both observers. Using the modified CT severity index, the observers graded severity of the acute pancreatitis as mild in 48, moderate in 37, or severe in 15 . Observers agreed on these grades in 70–79% of the cases (mean, 74%). The kappa statistic for each pair of observers ranged from 0.52 to 0.65, indicating moderate to good agreement.. In none of the cases was the severity of the pancreatitis scored differently by both observers.

Table 2

Severity categorisation	No. Of patients (%)	
	CTSI	Modified CTSI
Mild	61 (61)	48 (48)
Moderate	31 (31)	37 (37)
Severe	8 (8)	15 (15)

We found 7 cases, which were graded moderate (Score=4-6) according to CTSI, were found to be severe (Score 8-10) according to modified CTSI

Patient Outcome

The length of the hospital stay ranged from 0 to 35 days (mean, 7.2 days). Table 9 and 10 reveals the mean length

of stay for the different severity subgroups according to both indexes. A total of 24 (24%) patients underwent surgical or percutaneous interventions. Evidently, some patients underwent a combination of procedures (aspiration, drainage, and surgery). Evidence of infection was present in 32 (32%) patients. Organ system failure was present in 15 patients (15%), including failure of the heart (n=3) pulmonary system (n=5), central nervous system (n=2), and kidneys (n=3). In 6 of these patients, more than one organ system failed. Over all mortality noted in study was 6% (6 cases in total 100 patients). Most of them occurred in pts with necrotizing pancreatitis 66.6% (4), Rest in other complications 33.4%². Correlation of Scoring Indexes with Patient Outcome For the correlation between the two indexes and the length of the hospital stay we found a statistically significant correlation between the modified index and the length of

hospital stay ($p = 0.035$) for all severity groups. However, when using the current CT severity index, no significant difference ($p = 0.15$) in the length of the hospital stay was seen between the moderate and severe pancreatitis group. Correlation between the index and the length of the hospital stay, we found a statistically significant correlation between the modified index and the length of hospital stay ($p = 0.001$) for all severity groups. Significant correlation between the need for surgical or percutaneous interventions and the severity of pancreatitis was seen with the modified CT severity index ($p = 0.0001$). Similarly, the presence of infection was correlated with higher scores modified CT severity index ($p = 0.0001$). Finally, a significant correlation ($p = 0.00002$) was seen between the modified severity index score and the development of organ failure

Table 3: Patient Outcomes Using CT Severity Index

Outcome Factor	CT Severity Index		
	Mild (0–3 points)	Moderate (4–6 points)	Severe (7–10 points)
No. of patients	61	31	8
Length of hospital stay (days)	6	12	13
Intervention or surgery	7 (11.5%)	14 (45%)	3 (37.5%)
Infection	13 (21.3%)	16 (51.6%)	3 (37.5%)
Organ failure	5(8%)	7(22.5%)	3(37.5%)

Table 4: Patient Outcomes Using Modified CT Severity Index

Outcome Factor	Modified CT Severity Index		
	Mild (0–2 points)	Moderate (6–6 points)	Severe (8–10 points)
No. of patients	48	37	15
Length of hospital stay (days)	5	11	15
Intervention or surgery	4 (8.3%)	11 (30%)	9 (60%)
Infection	6 (12.5%)	17 (46%)	9 (60%)
Organ failure	2 (4.1%)	5 (13.5%)	8 53.3%)

Table 5: Patient Outcomes Using Modified CT Severity Index

Outcome Factor	Modified CT Severity Index		
	Mild (0–2 points)	Moderate (6–6 points)	Severe (8–10 points)
No. of patients	48	37	15
Length of hospital stay (days)	5	11	15
Intervention or surgery	4 (8.3%)	11 (30%)	9 (60%)
Infection	6 (12.5%)	17 (46%)	9 (60%)
Organ failure	2 (4.1%)	5 (13.5%)	8 53.3%)

DISCUSSION

A total of 100 patients were diagnosed having Acute Pancreatitis using spiral CT of which 78 were male and 22 were female. The present study shows comparable results to the study conducted by the Koenraad J. Mortelet and Walter Wiesner *et al*²⁵ with similar significant correlation between the need for **surgical or percutaneous interventions** and the severity of pancreatitis was seen with the modified CT severity index ($p = 0.0001$). Finally, a significant correlation ($p = 0.00002$) was seen between the modified severity index

score and the development of **organ failure**. When comparing patients with mild pancreatitis and those with severe pancreatitis, we documented a statistically significant correlation between the numeric score obtained with the Modified CT Severity index and the presence of infection, the need for surgery and percutaneous interventions, and the length of the hospital stay. Presence of ascites and pleural fluid may be responsible for the improved correlation, because they may be indicators of organ dysfunction. In conclusion, the modified CT severity index correlates more closely

with patient outcome in all the parameters studied, especially with the length of the hospital stay and the development of organ failure.

CONCLUSION

We conclude that Helical CT is an effective modality for imaging the pancreas with faster scanning time and no respiratory misregistration. Pancreas if scanned during the peak parenchymal enhancement phase, helps in better morphological characterization of pancreas and detection of pancreatic necrosis. Helical CT effectively detects the different non vascular and vascular complication of pancreatitis. Grading of acute pancreatitis according to the severity of the disease in the form of Modified CTSI which will predict the clinical outcome of the disease could be done effectively with helical CT.

REFERENCES

1. Haaga John R: The Pancreas; In Computed Tomography and Magnetic Resonance Imaging of the Whole Body (Vol.2); John R Haaga, Vikram S Dogra, Michael Forsting, Robert C Gilekeson; Fourth Edition 2003; Mosby ELSEVIER Pte. Ltd. Pg. 1395-1486.
2. Balthazar EJ: Acute Pancreatitis: Assessment of Severity with Clinical and CT Evaluation; Radiology 2002; 223:603-613.RSNA.
3. Ferrucci Joseph T, Jr, Wittenberg Jack, Black Edwaid B, Kirkpatrick Rob H, Hall Deborah A: Computed Body Tomography in Chronic Pancreatitis; Radiology 130: 175-182, January 1979.
4. Mendez Gaston, Jr., Isikoff Michael B, Hill Michael C: CT of Acute Pancreatitis: Interim Assessment; AJR 135:463-469, September 1980.
5. Seigelman Stanley S, Copeland Bruce E, Saba George P *et al*: CT of Fluid Collections Associated with Pancreatitis; AJR 134: 1121-1132, June 1980.
6. Federle Michael P, Brooke Jeffery R, Crass Richard A, Van Dalsem Volney: Computed Tomography of Pancreatic Abscess; AJR 136: 879-882, May 1981.
7. Silverstein William, Isikoff Michael B, Hill Michael C, Barkin Jamie: Diagnostic imaging of Acute Pancreatitis: Prospective Study Using CT and Sonognphy; AJR 137: 497-501, September 1981.
8. Brooke Jeffery R, Federle Michael P, Jeffery Brooke R, Cello John P: Early Computed Tomographic Scanning in Acute Severe Pancreatitis; Surgery, Gynecology and Obstetrics; February 1982, Volume 154.
9. Ranson JHC, Balthazar Emil J, Caccavale R and Cooper M: Computed Tomography and the Prediction of Pancreatic Abscess in Acute Pancreatitis; Ann Surg., May 1985, Vol. 391, No. 5.
10. Zeman RK, LV McVay, PM Silverman, EL Cattau, SB Benjamin, DF Fleischer, BS Garra and MH Jaffe: Pancreas divisum: thin- section CT; 1988 Radiology, Vol 169, 395-398
11. Vujic Ivan: Vascular Complications of Pancreatitis; Radiological Clinics of North America-Vol.27, No. 1, January 1989.
12. Bradley EL III, Murphy F and Ferguson C: Prediction of Pancreatic Necrosis by Dynamic Pancreatography; Ann Surg. 1989; oct; 210(4):495-503; discussion503-4.
13. LR King, MJ Siegel and DM Balfé: Acute pancreatitis in children: CT findings of intra- and extrapancreatic fluid collections; Radiology, Vol 195, 196-200, 1995.
14. Paulson EK, Vitellas KM, Keogan MT *et al*: acute pancreatitis complicated by gland necrosis: spectrum of findings on CECT.AJR 1999; 172: 609-613.
15. Balthazar Emil J: Pancreatitis; In Textbook of gastrointestinal Radiology Vol.2, Gore Richard M, Levine Marc S, Laufer Igor; W B Saunders Company; 1994; Pg 2132-2134
16. Terrence C Demos, Harold V Posniak, Carla Harmath1, Mary C Olson1 and Gerard Aranha: Cystic Lesions of the Pancreas; AJR 2002; 179:1375-1388.
17. J. Dario Casas, Rocío Díaz, Gracia Valderas, Antonio Mariscal, Patricia Cuadras; Prognostic Value of CT in the Early Assessment of Patients with Acute Pancreatitis; AJR March 2004;182:569-574;
18. Raul SK. Acute necrotising pancreatitis: Current Concepts. Indian J Surg 2005; 67:78-86.
19. Ishtiaq Ahmed Chishty, Vaqar Bari, Sajida Pasha, Dawar Burhan, Zishan Haider, Zafar Rafique; Role of Computed Tomography in Acute Pancreatitis and its Complications among Age Groups; J Pak Med Assoc2005; 55:431;
20. Nemes R, Georgescu I, Margaritescu D, Saftoiu A, Chiutu L, Georgescu E, Surlin V, Cartu D, Dumitrescu D : The pancreatic pseudocyst--late complication of the severe acute pancreatitis. Therapeutical options; 2006 May-Jun; 101 (3): 259-65.
21. Knoepfli AS, Kinkel K, Berner T, Morel P, Becker CD, Poletti PA: Prospective study of 310 patients: can early CT predict the severity of acute pancreatitis; aug2006 Aug 31 Pub MED.
22. Ekrem Kaya, Adem Dervişoğlu, Cafer Polat; Evaluation of diagnostic findings and scoring systems in outcome prediction in acute pancreatitis; World J Gastroenterol June 2007; 13(22): 3090-3094;
23. Jáuregui-Arrieta LAlvarez-López *et al*, Effectiveness of the modify tomographic severity index in patients with severe acute pancreatitis. Rev Gastroenterol Mex. 2008 Jul-Sep;73(3):144-8
24. Heiss P , Bruennler T, and Salzberger B *et al* , Severe acute pancreatitis requiring drainage therapy: findings on computed tomography as predictor of patient outcome. Pancreatology. 2010; 10(6):726-33.
25. Koenraad J. Morteale, Walter Wiesner, Lisa Intriene, Shridhar Shankar, Kelly H. Zoul, Babek N. Kalantari, Alex Perez, Eric vanSonnenberg, Pablo R. Ros, Peter A. Banks, Stuart G. Silverman: A Modified CT Severity Index for Evaluating Acute Pancreatitis: Improved Correlation with Patient Outcome: AJR November 2004;183: 1261-1265.

Source of Support: None Declared
Conflict of Interest: None Declared