

A study of Clinicopathological aspects of Pilonidal Sinus

Anilkumar M Talwade^{1*}, Sanjay Baswaraj Chanda²

^{1,2}Assistant Professor, Department of General Surgery, BRIMS, Bidar, Karnataka, INDIA.

Email: draniltalwade@gmail.com, chandasanjay31@yahoo.in

Abstract

Introduction: Pilonidal Sinus is a painful condition usually occurring in the intergluteal region, which consists of a Sinus or fistula, situated a short distance behind the anus and generally containing hair. Pilonidal Sinus has its peak incidence between 16-20 years of age and it decreases after age of 25 years it is rare after 45 years. Pilonidal Sinus occurs predominantly in men 80%. All races can develop the disease, but it seems more common in those with dark, stiff hair and hirsute individuals. However, Pilonidal Sinus can also occur in relatively hairless types. **Aims and objective:** to study the Clinicopathological aspects of Pilonidal Sinus. **Materials and Method:** In the present cross sectional study 30 patients of pilonidal sinus were enrolled. Detail history containing age, sex and occupation of the all the patients was noted in prestructured proforma. The main presenting symptoms were also noted. Routine general physical examination was done with special attention towards body hair distribution. On local examination site of the Pilonidal Sinus was confirmed, number of sinuses, presence of tenderness, discharge, any hair protruding from the sinuses and the condition of the surrounding area for indurations was examined. All patients also underwent digital rectal examination and proctoscopy. **Results:** 56.66% of patients were between 16-25 yrs of age. 70% were males. Labourers form the most common group constituting 40% of our patients followed by students. 24 (83.33%) of our patients were hairy individuals of which 18 were males and only 6 patients were hairy females. Discharge was the most common symptoms in the study being present in all patients. It was followed by pain (56.67%). Most common presentation being swelling and discharge from intergluteal region present in 20 (66.66%) of patients. Sinus was present in all patients (100%) and some form of discharge was seen in 86.7% patients. **Conclusion:** thus we conclude that pilonidal sinus is often very painful and associated with discharge and typically occurs in young hairy males.

Key words: pilonidal sinus, discharge, hairy individuals.

*Address for Correspondence:

Dr. Anilkumar M Talwade, Assistant Professor, Department of General Surgery, BRIMS, Bidar, Karnataka, INDIA.

Email: draniltalwade@gmail.com

Received Date: 03/10/2014 Accepted Date: 16/10/2014

Access this article online	
Quick Response Code:	Website: www.statperson.com
	DOI: 18 October 2014

INTRODUCTION

Pilonidal Sinus was probably first described by Mayo in 1833 in his paper entitled "Observation on injuries and diseases of the rectum, whereas some believe it was Anderson in 1847 who first described Pilonidal disease in a paper entitled "Hair extracted from an Ulcer". Hodges in 1880 coined the expressive term Pilonidal

Sinus. Pilonidal Sinus is a painful condition usually occurring in the intergluteal region, which consists of a Sinus or fistula, situated a short distance behind the anus and generally containing hair. Pilonidal Sinus has its peak incidence between 16-20 years of age and it decreases after age of 25 years it is rare after 45 years.¹ Pilonidal Sinus occurs predominantly in men 80%.² The true incidence of disease is unknown, but has been estimated to be around 25 per lakh population according to Norwegian Study³. All races can develop the disease, but it seems more common in those with dark, stiff hair and hirsute individuals. However, Pilonidal Sinus can also occur in relatively hairless types.¹ Pilonidal Sinus seen in sacrococcygeal region. It can also be seen at other sites like interdigital web in hands of hairdressers and barbers,^{4,5} Sheep rearer^{6,7}, Milkers⁸ and Dog groomers.⁹ The disease has also been described in sites like umbilicus¹⁰, Chest Wall¹¹, Anal Canal¹², Ear¹³ and Scalp.¹⁴ Patients may present actually with a complaint of

moderate to severe pain and swelling in the region of lower back, and it is usually the pain that prompts them to seek medical attention. More commonly, patient present with a chronically draining sinus at the base of spine or upper aspect of gluteal crease which cause moderate discomfort. This usually represents of a cycle of chronic, intermittent infection and drainage, which is nuisance and inconvenience to patient. Infrequently, physician may identify Pilonidal Sinus while routinely examining lower back or anorectal region. Rarely a patient may present with large undrained Pilonidal abscess with potential for sepsis and significant tissue damage. On examination the findings are very characteristic, situated accurately in midline about 5 cm or so behind the anus, there is an opening or a series of openings, placed close together or spread out over distance about 2-3 cm. The skin enters them so that they have a smooth edge unlike that of an ordinary fistula. In addition, hair often projects from openings. In majority, there is another sinus opening 2-5 cm more superiorly, almost always slightly to one or other side of midline. This does not differ in appearance from that of any other pyogenic fistula and frequently shows exuberant granulation tissue projecting from it. On palpation an elongated oval or irregular area of induration can usually be felt. 93% patients have secondary sinuses directed cephalad and only 7% have tracks directed caudally.

AIMS AND OBJECTIVE

To study the Clinicopathological aspects of Pilonidal Sinus.

MATERIALS AND METHOD

The present cross sectional study was conducted at Victoria Hospital attached to Bangalore Medical College. The study was conducted for three years. Following inclusion and exclusion criteria was used to select the study patients.

Inclusion criteria

Patients of pilonidal sinus under the age of 15-45 years and no other co-existing illness forbidding therapeutic intervention.

Exclusion criteria

- Pediatric patients and those above 45 years.
- Patients with underlying osteomyelitis.

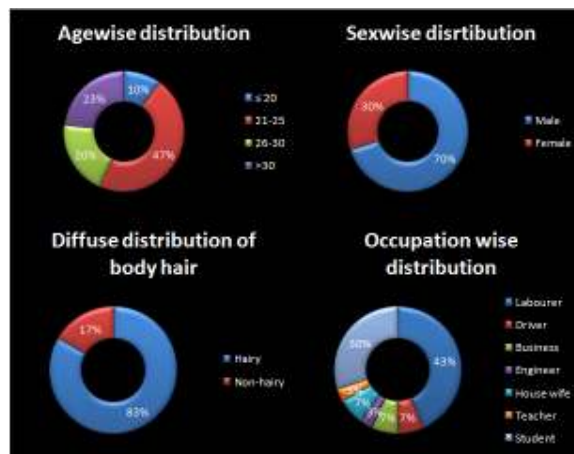
After receiving the permission of ethical committee of college the study was conducted in the department of surgery. Informed consent of all the participant patients was taken. A total 30 patients were enrolled in the study duration. Detail history containing age, sex and occupation of the all the patients was noted in prestructured proforma. The main presenting

symptoms were also noted. Routine general physical examination was done with special attention towards body hair distribution. On local examination site of the Pilonidal Sinus was confirmed, number of sinuses, presence of tenderness, discharge, any hair protruding from the sinuses and the condition of the surrounding area for indurations was examined. All patients also underwent digital rectal examination and proctoscopy.

RESULTS

Table 1: Distribution patients according to age, sex and occupation

Variable	Combined	
	No	%
Age in years	≤ 20	3 10.0
	21-25	14 46.7
	26-30	6 20.0
	>30	7 23.3
Sex	Male	21 70.0
	Female	9 30.0
Occupation	Labourer	13 43.33
	Driver	2 6.67
	Business	2 6.67
	Engineer	1 3.33
	House wife	2 6.67
	Teacher	1 3.33
	Student	9 30.00

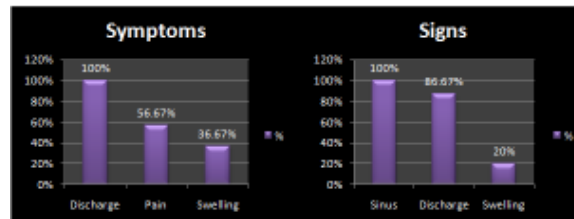


It was observed that majority of patients were young and were in age group of 20 to 30 years. Only 23.3% patients were above 30 years. Youngest patient in this group was 17 years and eldest was 44 years old. Mean age of presentation was 27.60±7.82 years. 70% patients in the study were males and 30% were females. It was observed that pilonidal sinus was most common among labourers (40%) and it was followed by students (30%).

Table 2: Distribution of patients according to signs and symptoms

Symptoms*	Discharge	30	100.00
	Pain	17	56.67
	Swelling	11	36.67
Sign*	Sinus	30	100.00
	Discharge	26	86.67
	Swelling	6	20.00
Diffuse distribution of body hair	Hairy	25	83.33
	Non-hairy	5	16.67

*multiple responses were recorded.



It was observed that discharge was the presenting symptom in all the patients in the study. It was followed by pain (56.67%) and swelling (36.67%). On clinical examination sinus was observed in all patients. Discharge was observed in 86.66% patients and swelling was palpated in 20% patients. Patient was defined as Hairy if there was diffuse distribution of body hair over the chest, abdomen and back. It was observed that 83.33% patients were hairy in the study.

DISCUSSION

Pilonidal Sinus is most commonly present in the sacrococcygeal region. It was observed that majority of the patients were less than 30 years of age. The mean age of presentation was 27.60 +7.82 years. In a study conducted by Keighley MRB et al⁴ it was found that Pilonidal disease was more common between 15-24 years of age and incidence decreases after age 25 years. It was rare after 45 years. Akinici et al¹⁵ observed that mean age of presentation was 22.1 years. Kooistra et al¹⁶ in his study found average age of presentation was 24.9 yrs. It was observed that Pilonidal sinus was predominantly a disease of young male. 70% patients in the study were male. In the study conducted by Guyuron Bet al² 80% of patients were men, Akinici et al¹⁵ observed 94.6% males suffering from the disease whereas in study conducted by Kooistra et al¹⁶ 73.7% of patients were males. Pilonidal Sinus disease was found to be more common among labourers forming 40% of the total study group. Students formed 30% in our study group. These finding were similar to Kooistra et al¹⁶ who in their study observed that university students formed 30% of their study group. Patient with diffuse distribution of body hair over the chest, abdomen and back were defined as Hairy. In the present study we found 83.33% of our patients to be hairy. Keighley MRB et al¹ had found that Pilonidal

Sinus was more common in individuals with dark, stiff hair and hirsute individuals. However, they also stated that Pilonidal Sinus could occur in relatively hairless individuals. Discharge was the presenting complaint in all patients (100%) followed by swelling in 66.66% and pain in 50% of patients. When compared to standard literature pain was less in our series because we considered pain as a complaint only if it was present at the time of admission. If not all our patients had pain at some time in the past during their illness. Kooistra et al¹⁶ in his series found pain (84%) to be the most common symptom followed by discharge (78%). Akinici et al¹⁵ found 87.5% patients presented with pain and 73.2% complaint discharge from sinus. When clinical examination was done sinus was observed in all the present. Discharge was present in 86.66% patients. Swelling was palpated at sinus site in 20% patients. In a study conducted by Kooistra et al¹⁶ 90% of patients had sinuses and only around 46% of patients had discharge.

CONCLUSION

thus we conclude that pilonidal sinus is often very painful and associated with discharge and typically occurs in young hairy males.

REFERENCES

1. Keighley MRB. Pilonidal sinus In: Keighley MRB, Williams N, and editors. Surgery of the anus rectum and colon. 2nd edition. London: W B Saunders: 1999; P.539-63.
2. Guyuron B, Dinner MI, Dowden RV. Excision and grafting in treatment of recurrent pilonidal disease. Surg. Gynecol Obstet 1983; 156: 201-4.
3. Sondenaa K, Andersen E, Nesvik I, et al. Patient characteristics and symptoms in chronic pilonidal sinus disease. Int J Colorectal Dis 1995; 10: 39-42.

4. Patel MR, Bassini L, Nashad R, et al. Barber's interdigital pilonidal sinus of the hand: a foreign body hair granuloma. *J Hand Surg.* 1990; 15A: 652-5.
5. Templeton HJ. Foreign body granuloma or interdigital cysts with hair formation. *Arch Dermatol Syph* 1942, 46: 157-8.
6. Matherson AD. Interdigital pilonidal sinus caused by wool. *Aust N.Z.J Surg* 1951; 21: 76-7.
7. Philips PJ. Web space sinus in a shearer. *Med J Awist* 1966; 2: 1152-3.
8. Meneghini CL. Gianotti F. Granulomatosis fistulosa interdigitalis of milkers hands *Dermatologia* 1964, 128; 38-50.
9. Mohanna PN. Al-Sam SZ, Flemming AFS Subungual Pilonidal Sinus of the hand of a dog groomers *Br J Plas Surg* 2001; 54: 176-8.
10. Allegaert WJ. Pilonidal sinus of the umbilicus. *Br J Clin Pract* 1967; 21: 201.
11. Sagger RP Pilonidal disease of the chestwall *J Ir Med Assoc.* 1967; 60: 125-7.
12. Wilson E. Failes DG, Killingback M. Pilonidal sinus of the anal canal: report of a case *Dis Colon Rectum* 1971; 14: 468-70.
13. Woodward WW. A pilonidal sinus of the ear. *Aust N Z J Surg* 1965; 35: 72-3.
14. Moyer DG Pilonida cyst of the scalp. *Arch Demnatol* 1972; 105: 578-9.
15. Akinici OF, Coskum A, Uzunkoy A. Simple and effective surgical treatment of pilonidal sinus: asymmetric excision and primary closure using suction drain and subcuticular skin closure. *Dis Colon Rectumd* 2000; 43: 701-7.
16. Kooistra HP. Pilonidal sinusesl review of the literature and report of three hundred and fifty cases. *AM J Surg* 1942; 55: 3.

Source of Support: None Declared
Conflict of Interest: None Declared