

Comparative study of PFN and DHS in proximal femoral fractures

Gourishankar D

Assistant Professor, Department of Orthopaedics, BRIMS Bidar, Karnataka, INDIA.

Email: gourish666@gmail.com

Abstract

Introduction: The operative treatment of proximal femoral fractures has been a matter of discussion ever since internal fixation was advocated to prevent the complications of long-term confinement to bed for the elderly. **Aims and objective:** To compare the Dynamic Hip Screw and the Proximal Femoral Nail method of fixation in intertrochanteric fracture of femur. **Materials and method:** total 50 cases of intertrochanteric fracture of femur were enrolled in the study. 25 patients were treated by Proximal Femoral Nail method and 25 were treated by Dynamic Hip Screw method. All the patients were observed meticulously intra operatively and post operatively. Duration required for surgery, blood loss and complications were recored. **Results:** The mean age of the study patients was 64.25years. It was observed that 64% patients in the sturdy were male. In 68% patients cause of fracture was domestic fall. Mean duration of surgery was 58±12 min whereas in DHS group was 91±8. Mean blood loss during surgery in PFN group was 100±16ml whereas in the DHS group was 250±50ml. Limb shortening was observed in 10 cases in PFN group whereas 24% in DHS. Nonunion was seen in one case of DHS group. In PFN group infection was seen in 6% patients and 14% in DHS group. Implant failure was seen in one case of PFN group whereas in two cases in DHS group. Death was observed in one cases of DHS group. **Conclusion:** thus we conclude that the Proximal Femoral Nail method for fixation in intertrochanteric fracture of femur is better as compared to the Dynamic Hip Screw.

Key words: PFN, DHS, intertrochanteric fracture of femur

Address for Correspondence:

Dr. Gourishankar D, Assistant Professor, Department of Orthopaedics, BRIMS Bidar, Karnataka, INDIA.

Email: gourish666@gmail.com

Received Date: 12/10/2014 Accepted Date: 20/10/2014

Access this article online

Quick Response Code:	Website: www.statperson.com
	DOI: 21 October 2014

INTRODUCTION

The operative treatment of proximal femoral fractures has been a matter of discussion ever since internal fixation was advocated to prevent the complications of long-term confinement to bed for the elderly.¹ Dynamic Hip Screw is recommended as the standard fixation method for stable A1 fractures.² Cephalomedullary devices are in favour as the treatment for unstable A2 and A3 fractures, especially in the absence of medial buttressing.^{3,4} In 1997, the AO/ASIF group developed the proximal femoral nail (PFN) with

two proximal screws, the lower load bearing neck screw and an additional antirotation hip pin to solve the above problems. The published data so far confirm the PFN to be a reliable implant with comparable results for the unstable proximal femoral fractures.^{5,6} However, various authors have reported screw cut out of the head-neck fragment.⁷ In 2004, the AO/ASIF group developed the proximal femoral nail antirotation (PFNA) to improve the rotational and angular stability with one single element. The PFNA blade claims to compact the cancellous bone to provide increased stability and this has been biomechanically proven to retard rotation and varus collapse. Biomechanical tests also demonstrated a significantly higher cut out resistance in the osteoporotic bone compared to commonly used screw systems.⁸

AIMS AND OBJECTIVE

To compare the Dynamic Hip Screw and the Proximal Femoral Nail method of fixation in intertrochanteric fracture of femur.

MATERIALS AND METHOD

Department of Orthopaedics, BRIMS Bidar, Karnataka, INDIA. The patients were randomly selected using following inclusion and exclusion criteria.

Inclusion criteria

- Surgically fit patients more than 50 years of age who has been diagnosed as having intertrochanteric fractures.

Exclusion criteria

- Patients unfit for the surgery,
- Compound or pathological fractures,
- Admitted for re-operation and those who have not given written consent for surgery.

Thus using the above mentioned inclusion and exclusion criteria total 50 patients was selected. Patients were randomly divided in two groups. In One group patients were managed by using PFN whereas second group was managed by DHS. Patients were carefully evaluated preoperatively. It included detailed history to determine the cause of fracture and other diseases if any present. The radiograph of pelvis with both hips and lateral view of the affected hip was taken. The fracture was classified using Orthopedic Trauma Association (OTA) classification. Skin traction was applied to all cases. All the patients were followed up regularly and examined in detail to measure the outcome.

RESULTS

Table 1: Demographic distribution of patients

Variable	No.	%
Age (mean±SD)	64.25±8.6	
Sex	Male	18 36
	Female	32 64
Cause of fracture	Domestic fall	34 68
	Road traffic accidents	16 32

It was observed that mean age of the study patients was 64.25 years with standard deviation of 8.6 years. It was observed that 64% patients in the study were male. In 68% patients cause of fracture was domestic fall.

Table 2: Mean duration of surgery and mean blood loss during surgery

	PFN	DHS	P value
Duration of surgery	58±12	91±8	<0.0000 (significant)
Blood loss	100±16	250±50	<0.0000 (significant)

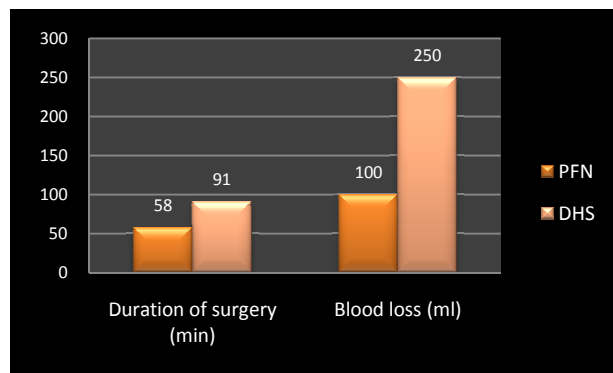


Figure 1: Mean duration of surgery and mean blood loss during surgery

It was seen that in PFN group mean duration of surgery was 58±12 min whereas in DHS group was 91±8. Mean blood loss during surgery in PFN group was 100±16 ml whereas in the DHS group was 250±50 ml.

Table 3: Distribution according to complications

Complications	PFN	DHS
Shortening	5 (10%)	12 (24%)
Nonunion	0 (0%)	1 (2%)
Infection	3 (6%)	7 (14%)
Implant failure	1 (2%)	2 (4%)
Death	0 (0%)	1 (2%)

Limb shortening was observed in 10 cases in PFN group whereas 24% in DHS. Nonunion was not seen in PFN group whereas one case of DHS group. In PFN group infection was seen in 6% patients and 14% in DHS group. Implant failure was seen in one case of PFN group whereas in two cases in DHS group. Death was observed in one case of DHS group.

DISCUSSION

In our study the average age was 64.25 years which was comparable to Indian as well as western authors with similar study. We had an 1:1.7 male: female ratio unlike male predominance in the Indian authors. The most common mode of injury in our study was domestic fall 68%, which was comparable to most of the Indian studies. This was also affected by the age as the older the patient more likely he/she getting the fracture by domestic falls. The average intra operative blood loss was very minimal in the P.F.N. The average blood loss in the P.F.N group was 100 ml and in the D.H.S group was 250 ml. The average operating time for the patients treated with P.F.N was 58 min as compared to 91 min in in

patients treated with D.H.S. We had a greater operating time in the beginning which reduced greatly in the later part of the study. This signifies the learning curve of the proximal femoral nailing. Total complications in our study were 15%. Limb shortening was observed in 10 cases in PFN group whereas 24% in DHS. No patient of nonunion was seen in PFN group whereas one case of DHS group. In PFN group infection was seen in 6% patients and 14% in DHS group. In plant failure was seen in one case of PFN group whereas in two cases in DHS group. Death was observed in one case of DHS group. Kyle et al⁹ and Hardy et al¹⁰ also observed similar complications in their study. Dynamic hip screw was introduced by Clawson in 1964. And it remains the implant of choice due to its favorable results and low rate of complications. It provides control compression at the fracture site. Its use has been supported by its biomechanical properties which have been assumed to improve the healing of the fracture. But Dynamic hip screw requires a relatively larger exposure, more tissue trauma and anatomical reduction. All these increase the morbidity, probability of infection and significant blood loss. It also causes varus collapse leading to shortening and inability of the implant to survive until the fracture union. Kyle RF et al⁹, Boyd HB et al¹¹, Jensen JS et al¹² also observed that Proximal femoral nail was more useful in unstable and reverse oblique patterns. As it has better axial telescoping and rotational stability as it is a load shearing device. It was observed more biomechanically stronger because it withstands higher static and several fold higher cyclical loading than dynamic hip screw. Thus the fracture heals without the primary restoration of the medial support. The implant compensates for the function of the medial column.

CONCLUSION

Thus we conclude that the Proximal Femoral Nail method for fixation in intertrochanteric fracture of femur is better as compared to the Dynamic Hip Screw.

REFERENCES

1. R.K.J. Simmermacher, A.M. Bosch, Chr. Van der Werken. AO/ASIF-proximal femoral nail (PFN): a new

- device for the treatment of unstable proximal femoral fractures. *Injury*, 30 (1999), pp. 327–332
2. M. Saudan, A. Lubbeke, C. Sadowski, *et al.* Ptertrochanteric fractures: is there an advantage to an intramedullary nail? A randomised, prospective study of 206 patients comparing the dynamic hip screw and proximal femoral nail. *J Orthop Trauma*, 16 (2002), pp. 386–393
3. L. Ahrengart, H. Tornkvist, P. Fornander, *et al.* A randomised study of the compression hip screw and Gamma nail in 426 fractures. *Clin Orthop*, 401 (2002), pp. 209–222
4. J.E. Madsen, L. Naess, A.K. Aune, *et al.* Dynamic hip screw with trochanteric stabilizing plate in the treatment of unstable proximal femoral fractures: a comparative study with the Gamma nail and compression hip screw. *J Orthop Trauma*, 12 (1998), pp. 241–248
5. G. Al Yassari, R.J. Langstaff, J.W. Jones, M. Al Lami. The AO/ASIF proximal femoral nail (PFN) for the treatment of unstable trochanteric femoral fracture. *Injury*, 33 (2002), pp. 395–399
6. H. Banan, A. Al Sabti, T. Jimulia, A.J. Hart. The treatment of unstable, extracapsular hip fractures with the AO/ASIF proximal femoral nail (PFN)—our first 60 cases. *Injury*, 33 (2002), pp. 401–405
7. W. Friedl, J. Clausen. Experimental examination for optimised stabilisation of trochanteric femur fractures, intra or extramedullary implant localisation and influence of femur neck component profile on cut-out risk. *Chirurg*, 71 (2001), pp. 1344–1352
8. PFNA. Leading the way to optimal stability: Synthes. Original instruments and implants of the Association for the Study of Internal Fixation. AO/ASIF. *Stratec Medical* 2004;1–44.
9. Kyle RF, Wright TM, Burstein AH. Biomechanical analysis of the sliding characteristics of compression hip screws. *J Bone Joint Surg Am.* 1980;62:1308e1314.
10. Hardy D, Descamps P, Krallis P, *et al.* Use of an intramedullary hip screw compared with a compression hip screw with a plate for intertrochanteric femoral fractures. A prospective randomized study of one hundred patients. *J Bone Joint Surg Am.* 1998;80:618e630.
11. Boyd HB, Griffin LL. Classification & treatment of intertrochanteric fractures. *Arch Surg.* 1949;58:853e866.
12. Jensen JS, Michaelsen M. Trochanteric fractures treated with McLaughlin plate. *Acta Ortho Scand.* 1975;46:795e803.

Source of Support: None Declared
Conflict of Interest: None Declared