

Complications of rigid bronchoscopy in pediatric foreign body aspiration: 3 rare case reports

Salma Shaziya

Ex-resident in MD Pediatrics. Department of Pediatrics. Bapuji Child Health Institute and Research Center, JJM Medical College, Davangere, Karnataka. INDIA.

Email: dr.salmamouzim@gmail.com

Abstract

The severity of complications in pediatric foreign body aspiration is often underestimated as they are rarely reported. Complications are more severe in patients who have tracheo-bronchial aspiration for prolonged time. Rigid bronchoscopy is a common procedure in pediatric age group. Pneumothorax and tracheo-broncheal stenosis are rare complications noticed after rigid bronchoscopy done for pediatric foreign body aspirations. Here are 3 case reports of complications noticed after bronchoscopy. First two cases developed pneumothorax post bronchoscopy and intercostal tube drainage was sufficient in their management. Third case had undergone 3 repeat rigid bronchoscopic procedures in one month duration. At 6 months follow up he had developed mild bronchial stenosis manifesting as intermittent wheezy respiration without respiratory distress. The case was managed conservatively.

Key words: Foreign bodies, Bronchoscopy, Complications.

Address for Correspondence:

Dr. Salma Shaziya, MD Pediatrics. Department of Pediatrics. Bapuji Child Health Institute and Research Center, JJM Medical College, Davangere, Karnataka. 577004 INDIA.

Email: dr.salmamouzim@gmail.com

Received Date: 22/10/2014 Accepted Date: 30/10/2014

Access this article online

Quick Response Code:	Website: www.statperson.com
	DOI: 31 October 2014

INTRODUCTION

Complications following retrieval of foreign body via rigid bronchoscopy are challenging such as bleeding, laryngeal trauma, laryngeal edema, laryngospasms, bronchospasms, infection, hypoxemia, tracheo-broncheal laceration, post-traumatic tracheo-bronchial stenosis, and pneumothorax.¹ The incidence of pneumothorax accounts for 0.2% cases undergoing rigid bronchoscopy.² Failure to recognise pneumothorax post bronchoscopy may prove fatal.³ Bronchial stenosis post repeat bronchoscopy for retained foreign bodies as of injury to the mucosal tissue are rarely reported in pediatric cases. Bronchial stenosis can be treated with various endoscopic treatment techniques. Most common cause of treatment failure is restenosis. Here we discuss 3 rare cases of complications noticed post bronchoscopy and how they were managed conservatively.

CASE DESCRIPTION

CASE 1

5 year old Maruthi brought to pediatric OPD with history of productive cough since 5 days, fever since 3 days, wheeze since 2 days and dyspnea since last night. There was no history of choking or aspiration in past. Child was having repeated respiratory illness treated with antibiotics, bronchodilators since past 40 days with no complete relief in symptoms. On examination there was reduced air entry on the right side, rhonchi and crepitations on right side there was right sided pleural rub. An x-ray chest (Fig -1 a) showed right lung segmental collapse and consolidation. A elective rigid bronchoscopy was done revealed an impacted tamarind seed. After 12 hour post-bronchoscopy child had developed dyspnea and reduced air entry on right side a repeat chest x ray (figure- 1 b) was done showing pneumothorax in the right lung. Immediate repeat bronchoscopy done revealed a retained bit of tamarind seed which was removed. An intercostal tube drainage was put. Time lapse between aspiration and bronchoscopic foreign body retrieval was assessed as >1 month as child was recurrently ill past 40 day. Child was discharged on 9th day of hospital stay after completion of antibiotics. His 6 month follow-up post bronchoscopy was uneventful.

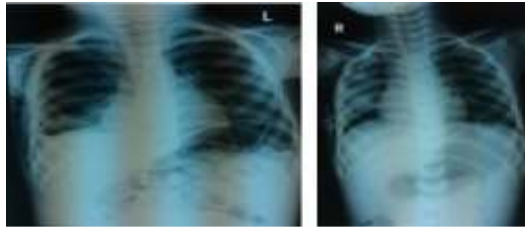


Figure 1a

Figure 1b

Legend

Figure 1a: Right lung collapse consolidation

Figure 1b: Right lung pneumothorax with right sided consolidation 12 hours post bronchoscopy requiring repeat bronchoscopy.

CASE 2

18 month Geetha came with history of cough since 15 days, fever since 5 days, dyspnea and wheeze since 3 days. On careful history there was history of choking noticed by mother one month back while playing with other kids. There was no previous repeated respiratory illness suggesting asthma or any other respiratory infection. Child was absolutely healthy prior 15 days. On

examination of this child there was right side reduced air entry, respiratory distress in form of dyspnea, respiratory rate-50 cycles per minute. Chest x- ray (figure-2a) revealed right lung obstructive emphysema with mediastinal shift . A strong possibility of foreign body aspiration with time lapse of 1month between aspiration and symptoms was made. Emergency rigid bronchoscopy done revealed a corn seed. As of prolonged aspiration the foreign body was impacted and had difficult extraction. 6 hours post bronchoscopy child had dyspnea, dip in oxygen saturation, chest x-ray (figure- 2b) done bedside revealed pneumothorax of left lung. As the corn seed was removed enmasse and pediatric surgeon had no doubt about foreign body retention, she was not subjected to repeat bronchoscopy and intercostal tube drainage for pneumothorax was put. Chest x -ray (figure-2 c) done after removing intercostal tube revealed clearing of pneumothorax. Child was discharged on 10th day of hospital stay. Follow-up of this child for next 6 months was uneventful.

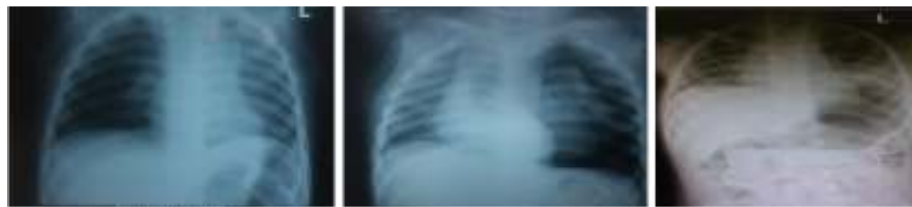

Figure 2a

Figure 2b

Figure 2c

Legend

Figure 2a: Pre-bronchoscopic obstructive emphysema.

Figure 2b: Post bronchoscopy left lung pneumothorax with shift of mediastinum.

Figure 2 c: Clearing of pneumothorax after intercostal tube drainage.

CASE 3

8 year old Kalyan kumar came with history of cough since 2 days , fever since 2 days, dyspnea since last night. Mother gave history of aspiration of tamarind seed 4 days back. On examination child had reduced air entry on right side with respiratory distress. Chest x-ray (figure -3 a) showed complete collapse of right lung with mediastinal pull towards same side. Emergency bronchoscopy was done revealed tamarind seed which had to be removed piece meal. 12hours post bronchoscopy child had dyspnea, an x-ray (figure-3b) taken showed consolidation of right lung. As the pediatric surgeon had suspicion of retained foreign body after first bronchoscopy, immediate 2 nd bronchoscopy was done, retained bits of tamarind seeds (figure 3 c) were removed. An x-ray (figure-3d) taken post 2nd bronchoscopy showed clearing of both lung fields. The child remained asymptomatic for 20 days, then started to notice respiratory distress and lower respiratory illness not responding to antibiotics. An x-ray (figure 3 e) taken at 1 month post second bronchoscopy showed unilateral right sided emphysema suggesting right

bronchial obstruction due to retained foreign body. He was subjected for third bronchoscopy showing retained swollen foreign body which was removed. He remained asymptomatic for subsequent 1 month. Later parents started noticing child to have audible wheeze noticed early in mornings or after exertional work intermittently . Child was brought to OPD with same complaints of whistling sound during inspiration and expiration audible intermittently during early mornings or night time or after exertion activity. On careful examination there was right side biphasic whistling sound heard both in inspiration and expiration over chest wall, there was no respiratory distress, nor the child had signs of lower respiratory illness. Child was not having history suggesting recurrent illness in past suggesting bronchial asthma . A chest CT scan (figure 3f and 3g) done revealed right bronchial concentric thickening causing mild airway narrowing. A virtual bronchoscopy done suggested right bronchial concentric narrowing supporting mild right bronchial stenosis as cause for recurrent biphasic whistling sound during respiration. As child remained asymptomatic and

maintained saturation and growth other than the complaint of recurrent intermittent noisy breathing or whistling sound during respiration, he was kept under follow up every 3 months. Even upto 2 years of follow up of this child he continued to have intermittent whistling

sound both in inspiration and expiration with no other complaint. The child's growth parameters also remained normal. Parents were reassured about the benign nature of stenosis and need for bronchoscopic dilatation and mitomycin ablation only if symptoms worsen.

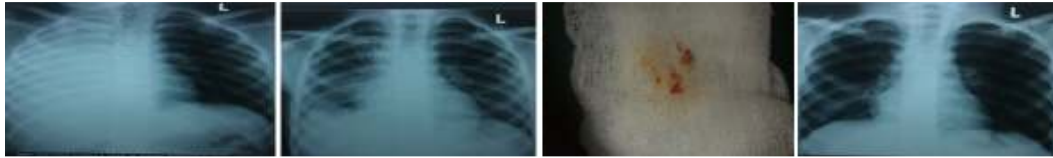


Figure 3a

Figure 3b

Figure 3c

Figure 3d

Legend

Figure 3a: Pre bronchoscopy right lung collapse with mediastinal shift to same side.

Figure 3b: Consolidation of right lung 12 hour post 1st bronchoscopy

Figure 3c: Retained bits of tamarind seed removed after 2nd bronchoscopy.

Figure 3d: Normal chest X-ray after 2nd bronchoscopy.

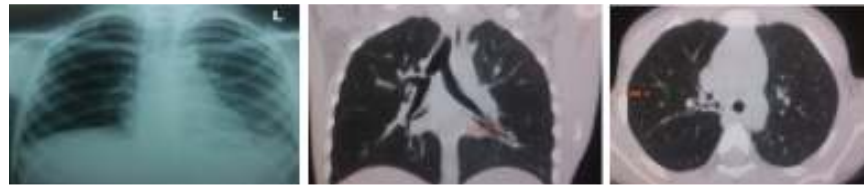

Figure 3e

Figure 3f

Figure 3g

Legend

Figure 3e: Obstructive emphysema of right lung noticed 1 month after 2nd bronchoscopy.

Figure 3f: Right bronchial concentric thickening 6 months after 3rd bronchoscopy suggesting bronchial stenosis.

Figure 3g: Right bronchial concentric thickening 6 months after 3rd bronchoscopy suggesting bronchial stenosis.

DISCUSSION

Foreign body or the procedure of bronchoscopy can independently damage the tracheobronchial system. The incidence of pneumothorax is very rare after rigid bronchoscopy.² Complications in foreign body aspiration develop depending upon time the object is present in bronchial system and the length of process during rigid bronchoscopy.⁴ The longer the foreign body is in airway granulation tissue increases and the more is the chance of mucosal damage during its extraction. In our first two cases pneumothorax was seen post bronchoscopy, first case became symptomatic 12 hours after and second case had symptoms 6 hours later to rigid bronchoscopy. In both cases there was organic foreign body and time lapse in aspiration was more than 1 month duration causing impaction of foreign body. The length of process during rigid bronchoscopy was increased in both cases in order to extract impacted foreign body. The cause of pneumothorax is because of sudden accumulation of extra pulmonary air after rigid bronchoscopy as of rupture of alveoli rather than iatrogenic airway perforation. Spontaneous alveolar rupture may be caused due to prolonged procedure causing pressure variations in airway. The risk of developing pneumothorax can be reduced when instruments are introduced and advanced gently and patient is breathing spontaneously. Jet

ventilation is also not recommended in children to prevent pneumothorax.⁵ In both of our first two cases pneumothorax resolved with only intercostal tube drainage as supported by Hasdiraz L *et al.*² Acquired stenosis of trachea-bronchial tree may result from thermal inhalation, chemical burns or intubation.⁶ Trachea-bronchial stenosis are amenable to endoscopic treatment techniques such as laser vaporization and serial dilation. The most common cause of failure is restenosis. A corticosteroid may be injected in stenotic area or mitomycin may be applied locally under endoscopic guidance to inhibit recurrence and scar formation. Mitomycin C is an antineoplastic antibiotic that acts as alkylating agent inhibiting cell division, protein synthesis and fibroblast proliferation. Mitomycin C impedes inflammatory response. The ideal treatment for trachea-bronchial stenosis is CO₂ laser or Nd YAG laser ablation which provides vaporization and coagulation.^{7,8} Our third case was a case of mild bronchial stenosis. The possible etiology was because of repeated bronchial mucosal injury as of retained foreign body and three consecutive rigid bronchoscopies done in a span of one month. All the three times child had classical unilateral lung signs and x-ray pictures suggestive of foreign body aspirations. The child had retained bits of foreign body retrieved at each of repeat bronchoscopic procedure. He had wheeze or

whistling sound while breathing in morning hours and night or on exertion noticed intermittently. This wheeze was not troubling him in his daily activity like dyspnea, lag in growth and activity. The child was followed up conservatively every 3 months till 2 year duration. He had no any worsening of symptoms as of which no further step in treatment was taken. The possibility of restenosis even after bronchoscopic dilation or ablation is a known fact. Introducing bronchoscope for mild stenosis and causing further injury with dilation , electrical or chemical ablation with no assurance for permanent relief was kept in mind and hence patient was managed conservatively, as stenosis was not causing any hindrance for growth and activity of child except for wheezy respiration.

CONCLUSION

Pneumothorax is rare complication following rigid bronchoscopy which may be fatal if not treated. Every case post bronchoscopy should be monitored for this complication and treated early. Retained foreign bodies in airway may require multiple bronchoscopic retrieval which may injure the mucosa and cause bronchial stenosis. Iatrogenic mild benign bronchial stenosis with no symptoms of respiratory distress can be conservatively managed with regular follow up care.

REFERENCES

1. Reddy V. Anesthetic management of 18 month old child for rigid bronchoscopy: A difficult case scenario. *Perspectives in Medical Research*. 2014 jan; 2(1):41-42.
2. Hasdiraz L, Oguzkaya F, Bilgin M, Bicer C. Complication of bronchoscopy for foreign body removal: experience of 1035 cases. *Ann Saudi Med*. 2006;26(4):283-87.
3. Merrill W, Michels MD. Pneumothorax and Mediastinal Emphysema Complicating Tracheostomy. *Arch Otolaryngol*. 1939;29(5):842-52.
4. Ciftci A O, Bingol KM, Enocak ME, Tanyel F C, Buyukpamukcu N. Bronchoscopy for evaluation of foreign body aspiration in children. *J Pediatr Surg*. 2003;38:1170-76.
5. Campisi P, Forte V. Rigid endoscopy of airway: Basic technique. Chapter 9. *Operative endoscopy and endoscopic surgery in infant and children*. Taylor and Francis group. 2012: 57-59.
6. Smith ME, Elstad MR. Bronchology. Chapter 84. *Ballengers otorhinolaryngology : Head and Neck surgery*. Snow Wackym. 17th edition. 2006:966-67.
7. Burkey BB, Gardy S L, Rohde S L. Airway control and laryngotracheal stenosis in adults. Chapter 78. *Ballengers otorhinolaryngology: Head and Neck surgery*. Snow Wackym. 17th edition. 2006:909-11.
8. Puchalalski J. Tracheal and bronchial stenosis: etiologies, bronchoscopic interventions and outcomes. *Pakistan Journal of Chest Medicine*. 2012 jan-mar;18(1):38-46.

Source of Support: None Declared
Conflict of Interest: None Declared