

Bombay blood group in a female child with congenital anomalies and recurrent infections – a rare case report

Priya Subashchandrabose^{1*}, Vasudevan Kasturirengan², Monica Vincent Bonipace³, Sarada Venkatesan⁴

¹Assistant Professor, ^{2,3}Tutor, ⁴Professor and HOD, Department of Pathology, Chennai Medical College Hospital and Research Centre, Trichy, Tamilnadu, INDIA.

Email: drsriya782@gmail.com, vasurohit54@gmail.com, drmonicavincen@gmail.com, drvsarada@gmail.com

Abstract

Bombay blood group is a very rare phenotype within ABO group and is inherited in an autosomal recessive pattern. This phenotype necessitates extreme caution while blood transfusion as these individuals can be given either autologous transfusion or blood from other Bombay group individuals only. Review of literature reveals that Bombay blood group is reported to be associated with congenital disorder of Glycosylation Type 2c, leukocyte adhesion deficiency type 2 and Rambam–Hasharon syndrome. To the best of author's knowledge, there are no other syndromic associations described so far. We report a case of incidentally identified Bombay blood group in a 12 year old female child during routine pre operative evaluation for drainage of cerebellar abscess. She had a constellation of clinical findings which include Bombay blood group, congenital anomalies (Bilateral Microtia with Supra aural fistula), history of mild delay in developmental milestones and recurrent infections (Mastoiditis).

Keywords: Bombay Blood group, Congenital anomalies, Prevalence of Bombay phenotype, Recurrent infections.

*Address for Correspondence:

Dr. Priya Subashchandrabose, Assistant Professor, Chennai medical college hospital and research centre (SRM group), Irungalur, Trichy-621 105, Tamilnadu, INDIA.

Email: drsriya78@gmail.com

Received Date: 20/10/2014 Accepted Date: 30/10/2014

Access this article online

Quick Response Code:	Website: www.statperson.com
	DOI: 31 October 2014

INTRODUCTION

Bombay blood group (BBG) is an extremely rare phenotype within ABO blood group system.¹ Review of literature reveals that the BBG is reported to be associated with congenital disorder of Glycosylation Type 2C,² Leukocyte adhesion deficiency type 2,³ and Rambam–Hasharon syndrome.⁴ So far, no other syndromic associations are described for BBG. We report the first case of an Indian female child, who had a constellation of

clinical findings which include Bombay blood group, congenital anomalies (Bilateral Microtia with Supra aural fistula), history of mild delay in developmental milestones and recurrent infections (Mastoiditis).

CASE REPORT

A 12 year old female child presented to the outpatient department with complaints of discharge from left ear and intractable headache. She had history of recurrent mastoiditis for past three years. She was born of consanguineous marriage. There was a history of mild delay in developmental milestones. On examination, she had bilateral microtia (grade 3) (Figure 1A and 1B) and features of left mastoiditis. Computerized Tomography (CT) scan revealed a left cerebellar hemispheric abscess (Figure 2) and hence drainage of cerebellar abscess was planned. Routine pre operative evaluation of the child was performed. She was referred to blood bank for blood grouping which was done by tube method. Forward grouping was done with patient's 5% red cell suspension against Anti A, Anti B, Anti D and Anti H grouping sera

(manufactured by J. Mitra and Co, New Delhi, India.) which showed agglutination with Anti D sera and absence of agglutination with Anti A, Anti B and Anti H sera. This indicates the absence of A, B and H antigens on the Red cells (Figure 3A). Reverse grouping was done with

A, B and O pooled cells (prepared in-house in our blood bank) against patients serum, which showed agglutination in all three tubes, thus revealing the presence of Anti A, Anti B and Anti H antibodies (Figure 3B). So the blood group was reported as Bombay O Rh positive.

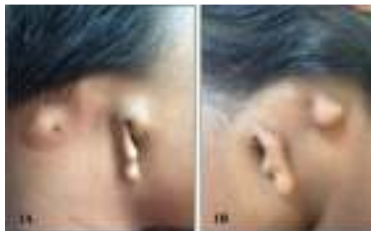

Figure 1: Bilateral Microtia with Supra-Auricular fistula

Figure 1A: Right side showing absence of external ear and just a remnant of skin and cartilage (Right microtia – grade3) A supra aural fistula is also seen. 1B: Left side showing absence of external ear and just a small remnant of skin and cartilage (Left microtia – grade3). An additional skin tag is also noted

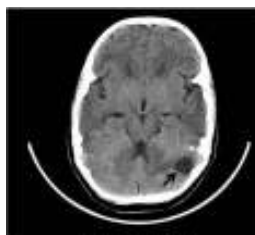


Figure 2: CT Brain

Figure 2: Computerized tomographic picture showing a left cerebellar abscess (black arrow)

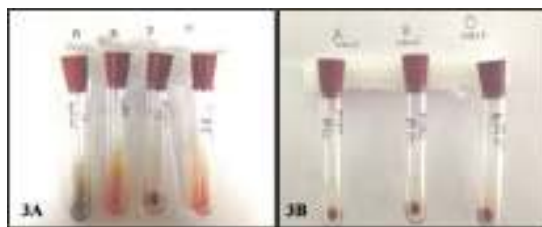

Figure 3: Forward and Reverse grouping by Tube method

Figure 3A: Forward grouping with Anti A, Anti B, Anti D and Anti H grouping sera showing absence of agglutination in three test tubes (Anti A, Anti B and Anti H sera) and positive agglutination (cell button) in test tube with Anti D sera. 3B: Reverse grouping with A, B and O pooled cells show positive agglutination (cell button) in all three test tubes

DISCUSSION

Bombay phenotype (Oh or hh) was first identified in 1952 by Dr. Y. M. Bhende, in a patient with blood group O, whose blood was incompatible with multiple O group donors on cross matching.¹ BBG is extremely rare with an estimated prevalence of 1:10,000 individuals in India and about 1: 1,000,000 persons in other parts of the world.⁵ In our Blood bank, 47,753 blood groupings have been performed for a period of four years nine months from January 2010 to September 2014 and 9 individuals (four males and five females with a male: female ratio of 0.8: 1) were identified to have Bombay blood group, accounting for a prevalence of 0.02 %, which is much higher when compared to literature data which states a prevalence of 0.004 % in Tamil Nadu.⁶ Bombay

phenotype is characterized by the lack of H antigen on the Red Blood Cells (RBCs). Since H antigen is the precursor of A and B antigens, these individuals also lack A and B antigens on RBCs. As a consequence, these persons produce Anti-A, Anti-B and Anti-H antibodies. This phenotype is unique for the reason that in routine blood grouping it is typed as O group (because of the absence of A and B antigens on red cells), however when cross matching the BBG individual with group O donors, there will be incompatibility (due to the presence of anti – A, anti – B and anti – H in the serum of these individuals which reacts with O cells of donor). The clinical significance of anti H antibodies is that, they can cause acute hemolytic reaction, if the blood from other O group individuals containing H antigen are given and hence

when considering these patients for transfusion, either autologous transfusion or blood from identical Bombay type can only be safely transfused.⁷ The H antigen has the same wide tissue distribution similar to the A and B antigens. In persons who are "secretors", a soluble form of the H antigen is found in all body fluids excluding the cerebrospinal fluid.⁵ H antigen is formed by a specific fucosyl transferase (FUT) enzyme, FUT1. RBCs have the H locus which contains the FUT1 gene. At least one normal FUT1 gene should be present (H/H or H/h) on the RBCs for the production of H antigen and consequently, Bombay phenotype occurs if both copies of FUT1 gene are inactive (h/h). The Tyr316Ter mutation in the coding region of FUT 1 is the most common cause of classical Bombay phenotype.⁸ Two cases of Congenital Disorder of Glycosylation Type 2C were reported by Dauber *et al* with features of autism, short stature, BBG, developmental delay, and recurrent otitis media. Genetic analysis identified compound heterozygous mutations in the SLC35C1 gene.² Two children with Leukocyte adhesion deficiency type 2 (LAD 2) with short stature, severe mental retardation, peculiar facies, BBG and defective leukocyte motility were reported. It was identified that transport of GDP – L- fucose into golgi apparatus was defective.³ The gene for fucosyl transferase is necessary for synthesis of H antigen and hence they had BBG. The mutations in the GDP fucose transporter were identified in three other patients with LAD2.⁹ Rambam–Hasharon syndrome (RHS) is an inborn error in fucose metabolism transmitted in an autosomal recessive pattern, characterized by short stature, Mental retardation, coarse facies, and recurrent infections. The lack of membrane glycoprotein H on RBCs due to deficiencies of fucosylated proteoglycans is responsible for BBG.⁴ Two more cases RHS with features of peculiar facies, microcephaly, mental retardation, seizures, short stature, hypotonia, recurrent infections, decreased neutrophil motility and BBG were reported. The mutation in GDP fucose donor was identified as the cause of these varied clinical manifestations.¹⁰ To conclude, we report the first

case of an Indian female child, who had a constellation of clinical findings which included BBG. Further studies in large cohort of population are required to unravel other syndromic associations of Bombay Blood Group.

REFERENCES

1. Bhende YM, Deshpande CK, Bhatia HM. A new blood group character related to the ABO system. *Lancet* 1952; 1:903-4.
2. Dauber A, Ercan A, Lee J, James P, Jacobs PP, Ashline DJ, *et al*. Congenital disorder of fucosylation type 2c (LADII) presenting with short stature and developmental delay with minimal adhesion defect. *Hum Molec Genet*. 2014; 23:2880-7.
3. Sturla L, Puglielli L, Tonetti M, Berninsone P, Hirschberg CB, De Flora A *et al*. Impairment of the Golgi GDP-L-fucose transport and unresponsiveness to fucose replacement therapy in LAD II patients. *Pediatr Res*. 2001; 49 (4): 537–42.
4. Frydman M, Vardimon D, Shalev E, Orlin JB. Prenatal diagnosis of Rambam–Hasharon syndrome. *Prenat Diagn*. 1996; 16: 266–9.
5. Oriol R, Candelier JJ, Mollicone R. Molecular genetics of H. *Vox Sang* 2000;78:105-8.
6. Das PK, Nair SC, Harris VK, Rose D, Mammen JJ, Bose YN, *et al*. Distribution of ABO and Rh-D blood groups among blood donors in a tertiary care center in South India. *Trop Doct* 2001; 31:47-8.
7. Khan MQ. Bombay blood group: a case report. *Pacific J Sci Tech* 2009; 10:333-7.
8. Koda Y, Soejima M, Johnson PH, Smart E, Kimura H. Missense mutation of FUT1 and deletion of FUT2 are responsible for Indian Bombay phenotype of ABO blood group system. *Biochem Biophys Res Commun*. 1997; 238:21–5.
9. Lubke T, Marquardt T, Etzioni A, Hartmann E, Von Figura K, Körner C. (May 2001). Complementation cloning identifies CDG-IIc, a new type of congenital disorders of glycosylation, as a GDP-fucose transporter deficiency. *Nat Genet*. 2001; 28 (1):73–6.
10. Frydman M, Etzioni A, Eidlitz-Markus T, Avidor I, Varsano I, Shechter Y *et al*. Rambam–Hasharon syndrome of psychomotor retardation, short stature, defective neutrophil motility, and bombay phenotype. *Am J Med Genet*. 1992; 44:297–302.

Source of Support: None Declared
Conflict of Interest: None Declared