Case Report

Massive haemoptysis, SOB and bilateral lung infiltrates: a case report

Manish Jain[1*], Soni Shridha[2], Prem Kumar[3], Anupam[4], Asif Feroz[2], Sachet[2]

[1]Associate Professor, [2]Resident, [3]Assisstant Professor, [4]Senior Resident, Department of Respiratory Medicine, NIMS University, Shobha Nagar, Jaipur, Rajasthan, INDIA.

Email: doctormanishjain2@gmail.com

Abstract

Introduction: LD, 60 years old male, resident of village, Shahpura, reported to us with SOB and hemoptysis for 4 days. He did not suffer from orthopnea, paroxysmal nocturnal dyspnea, wheeze, sneeze or any other system illness. Prior to this he was suffering from a febrile illness of undiagnosed etiology for 4 months. For this, he was put on various antibiotics but without any relief. He was also put on methylprednisolone, 16mg/day for 20 days prior to this admission. About 15 years back, he also took anti tubercular treatment for 9 months and was declared as cured. He was a reformed smoker but never took alcohol. He was Jeweller by occupation. Laboratory investigations, done prior to admission and in hospital, showed persistent leukocytosis and falling hematocrit but sputum examination did not reveal AFB, fungi or any other micro-organism. X-ray chest PA view dated 11.01.2014 showed extensive bilateral opacities. Old X-rays and CT images were irreparably damaged. In hospital examination revealed tachypnea and bilateral crepitation. SPO2 at admission was 80% off oxygen. Awaiting further investigations and serology, the patient was kept on antibiotics and oxygen. Voreconazole was added latter but the patient succumbed to his illness. Serology, received post mortem, was negative for ANA, C-ANCA, P-ANCA and anti GBM antibodies but was positive for anti Asp Ab, IgE and GM.

Keywords: Massive hemoptysis, Shortness of breath, Fever.

***Address for Correspondence:**
Dr. Manish Kumar Jain, 105, Shubham Apartment, Central Spine, Vidhyadharnagar, Jaipur-302023, Rajasthan, INDIA.
Email: doctormanishjain2@gmail.com

Received Date: 07/11/2014 Accepted Date: 16/11/2014

Access this article online	
Quick Response Code:	Website: www.statperson.com
	DOI: 17 November 2014

INTRODUCTION

A triad of hemoptysis, shortness of breath (SOB) and bilateral infiltrates is a common clinical problem but massive hemoptysis, acute SOB and bilateral infiltrates in a patient with chronic febrile illness should not only be rare but certainly pose a diagnostic dilemma to any respiratory physician. While chronic inflammatory conditions like bronchiectasis, tuberculosis and lung abscesses, malignancies, pulmonary aspergillomas and rarely endometriosis (catamenial hemoptysis)/Behcet's disease, all may cause massive haemoptysis[1,2] acute SOB is rare in any of these disorders. On the contrary, diseases like Wegener's grannulomatosis and Good pasture's syndrome often present with SOB, hemoptysis, pulmonary infiltrates, and anaemia but massive hemoptysis is remarkably uncommon in these disorders.[3,4] Review of clinical history, prompt investigations and good clinical skills are the key to timely diagnosis and treatment of such patients. Any delay is likely to be catastrophic. We are presenting such a case for the benefit of the readers.

CASE REPORT

LD, 60 years old, Hindu male was admitted to our hospital with shortness of breath (SOB) and uncontrolled hemoptysis for 4 days. He did not have any orthopnea, paroxysmal nocturnal dyspnea, wheeze, sneeze or other system illness.

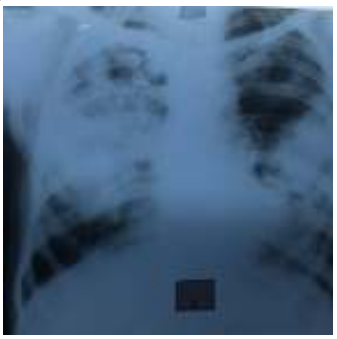

Figure 1

How to site this article: Manish Jain, Soni Shridha, Prem Kumar, Anupam, Asif Feroz, Sachet. Massive haemoptysis, SOB and bilateral lung infiltrates: a case report. *International Journal of Recent Trends in Science and Technology* November 2014; 13(1): 151-153 http://www.statperson.com (accessed 17 November 2014).

Table 1: Laboratory Investigations

Date	16.9.13	5.10.13	13.10.13	10.12.13	23.12.13	11.01.14	12.01.14
HMG	12.9		10.4	7.4	8.2	6.4	4.2
TLC	11400	17200	19900	25100	12600	14700	14000
DLC P	65	78	78	70	66	69	85
L	25	20	18	24	29	26	14
E	05	01	00	04	00	04	01
M	03	00	02	00	02	01	00
PLT	2.11	-	-	4.23	3.69	4.80	6.70
MCH	30	-	31	23	-	-	-
MCHC	33.7	-	34	25	-	-	-
HCT	-	-	-	19.3	23	15.7	-
TRBC	-	-	-	2.31	2.73	2.13	-
ESR	38	-	-	-	-	-	53
Urea	20.4	-	-	-	-	-	92
Creatinine	-	-	-	-	-	-	2.10
SGOTSGPT	-	-	-	-	-	-	29 19
Urine	NAD	NAD	-	-	-	-	
Widal	-ve	-	-	-	-	-	-
RBS	92.4	-	-	102	-	-	-
Sputum for AFB	-ve	-ve	-ve	-ve	-ve	-	-ve
HIV	-	-ve	-	-	-	-	-ve
U Abdomen	-	-	NAD	-	-	-	-

Fifteen years back, he had pulmonary tuberculosis and was put on anti-tubercular drugs but was declared as cured. About 4 months back, he reported back to a private practitioner with low grade fever and cough for few days. He was put on co-amoxyclav and symptomatic drugs but without any relief. Since then he has consulted several physicians and investigated time and again (Table 1). Bronchoscopy, done on 13.10.2013, was unremarkable. Bronchial washings showed squamous epithelial cells, occasional RBC's and proteinaceous material but did not any show any organism on Gram's stain, ZN staining, KOH mount and culture on Lowenstein Jenson media/line probe assay. He was put on various antibiotics, anti-tubercular drugs and fluconazole in standard doses but without any relief. Prednisolone, 20mg/day, was also added. On this the patient improved partially but only to worsen later. His X-ray chest PA view dated 11.01.2014 showed extensive bilateral opacities (Figure 1). His old chest X-rays and computerised tomograms (CT) were irreparably damaged and were not good enough to review. Other than the above, there was no history of pain chest, hoarseness, hematuria, joint pains or skin rashes in the past. There was no past history of any allergic diathesis or bronchial asthma either. He was a reformed smoker but never took alcohol. He was a jeweller by occupation. On general examination, he looked pale and anxious. His temperature was 99.6 ^{0}F; pulse rate, 128/min; blood pressure, 130/70 mm Hg and respiratory rate, 26/min. Neck veins were not engorged. Fingers were clubbed but lymph nodes were not enlarged. Physical examination of his chest revealed bilateral coarse crepitation. Examination of other systems did not reveal any abnormality. At this hospital the patient was put on cephaperazone-salbactum 1.5 gm IV, 8 hourly. Routine investigation sent on 12.01.2014 showed leukocytosis and falling hematocrit but biochemical studies were within normal limits. Urine routine examination revealed albumin; ++, sugar; nil, RBCs; 18-20/HPF, WBCs; 06-08/HPF and granular cast. Total protein excretion in urine was 1.5gm/24hrs. Sputum smear was negative for AFB and fungal elements. Sputum, blood and urine culture were reported as sterile. Bleeding time and clotting time were within normal limits. An emergency bronchoscopy done on 13.01.2014 failed to control bleeding even after repeated lavage with adrenaline mixed cold saline hence the plan to obtain lung biopsy was shelved. BAL was negative for malignant cells and microbes on Gram's stain, ZN staining and KOH mount. High resolution computerized tomography (HRCT) could not be undertaken as by this time the patient was very sick. Meropenam 1 gm 8 hourly was added. Meanwhile his serum was sent for estimation of antinuclear antibodies (ANA), anti-neutrophil cytoplasmic antibodies (p-ANCA and c-ANCA), immunoglobulin E (IgE), anti aspergillous antibodies (Anti Asp Ab) and glactomannan (GM). As the patient was fast deteriorating, aspergillosis was considered in view of history of pulmonary tuberculosis, multiple antibiotic administration and steroid therapy in the past. Accordingly, voreconazole 200 mg IV 12 hourly was added on an empirical basis on 15.01.2014. Four

units of blood were also transfused. Immune-suppressive therapy was also under active consideration as patient was having hematuria but was held up until the serology reports in view of the chronic febrile illness. On 16.01.2014, he was severely breathlessness and was hypoxemic even on high flow oxygen so he was put on mechanical ventilation. Latter, he had a bout of massive hemoptysis and died the same day. Serology, received post mortem, was negative for ANA, p- NCA, c-ANCA and anti GBM but Anti Asp Ab, IgE and GM levels were raised (136, 1136 and 2.4 units respectively).

DISCUSSION

Our patient was initially suffering from a chronic febrile illness and his clinical course latter was complicated by massive hemoptysis, acute onset SOB and bilateral pulmonary infiltrates. Serology was found to be positive for Anti Asp ab and IgE. This type of serology in our patient with chronic febrile illness was highly suggestive of chronic nectortising pulmonary aspergillosis (CNPA)[5] which is characterized by local invasion of lung tissue by fungal elements without vascular invasion.[6] Dissemination to other organs does not occur in CNPA in spite of the prolonged illness.[7,8] It manifests in middle-age and elderly patients, with nonspecific symptoms including fever, cough, hemoptysis and weight loss of 1–6 months duration[6] but massive hemoptysis is a rare. Indeed Vahid and Marik[9] have reported the first and only case of CNPA with massive hemoptysis. Although, CNPA by itself, could have caused massive hemoptysis in our case also, yet progression to invasive pulmonary aspergillosis (IPA) looks more likely the possibility. Our patient was at least partly immune suppressed host as he was on prolonged use of antibiotics and received steroids for >15 days, the risk factors included in the list for IPA.[10]In this background, acute onset and rapidly progressive symptoms, lung infiltrates and raised GM levels are good enough evidences to diagnose IPA in this patient even in the absence of histo-pathological proof. We, in deed started antifungal therapy on 15.01.2014 on empirical basis as time was running out but it was still too late.

REFERENCES

1. Hirshberg B, Biran I, Glazer M, et al. Hemoptysis: etiology, evaluation, and outcome in a tertiary referral hospital. Chest 1997; 112:440–4.
2. Rumbak M, Kohler G, Eastrige C, et al. Topical treatment of life threatening haemoptysis from aspergillomas. Thorax 1996; 51:253–5.
3. Schwarz MI, Brown KK. Small vessel vasculitis of the lung. Thorax 2000; 55:502–10.
4. Dweik RA, Stoller JK. Role of bronchoscopy in massive hemoptysis. Clin Chest Med 1999; 20:89–105.
5. Denning DW, Riniotis K, Dobrashian R and Helen Sambatakou H. Chronic Cavitary and Fibrosing Pulmonary and Pleural Aspergillosis: Case Series, Proposed Nomenclature Change, and Review Clinical Infectious Diseases 2003;37:S265-S280.
6. Binder RE, Faling LJ, Pugatch RD, Mahasaen C, Snider GL. Chronic necrotizing pulmonary aspergillosis: a discrete clinical entity. Medicine (Baltimore) 1982; 61(2):109–124.
7. Saraceno JL, Phelps DT, Ferro TJ, Futerfas R, Schwartz DB. Chronic necrotizing pulmonary aspergillosis: approach to management. Chest 1997; 112(2):541–548.
8. Soubani AO, Chandrasekar PH. The clinical spectrum of pulmonary aspergillosis. Chest 2002; 121(6):1988–1999.
9. Vahid B and Marik PE. Fatal Massive Hemoptysis in a Patient on Low-Dose Oral Prednisone: Chronic Necrotizing Pulmonary Aspergillosis. Respir Care 2007; 52:56 –58.
10. Denning DW: Aspergillosis in Harrison's principles of internal Medicine. Edi; Fauci AS, Braunwald E, Kasper BL, Hauser SL, Longo DL, Jammerson JL and Loscazlo J: Ed 17th, Mc Graw Hill, New York, Page 1256-60.

Source of Support: None Declared
Conflict of Interest: None Declared