

Histopathological study of xanthogranulomatous reaction in various sites

Ronald J Bosco^{1*}, S Sowmya²

¹P. G. Student, ²Professor and HOD, Department of Pathology, Sri Manakula Vinayagar Medical College, Pudhucherry-605107, INDIA.

Email: ronaldaswathy@gmail.com, drssowmya@hotmail.com

Abstract

Introduction: Xanthogranulomatous inflammation is a chronic inflammatory disease. Histologically characterized by collection of foamy macrophages admixed with polymorphonuclear leukocytes, plasma cells and lymphocytes in a mosaic like pattern along with marked fibrosis and organ destruction. Most common sites are gall bladder, kidney, followed by lymph nodes and urogenital tract. They mimic malignant neoplasm both radiologically and clinically. Usually they are incidental findings in the histopathological sections. They can be induced or associated with neoplastic and inflammatory processes. **Materials and Methods:** Histopathologically diagnosed cases of xanthogranulomatous reaction from the department of pathology, SMVMCH for a period of 2 years from 2012 to 2013 were taken for this study. **Observation and Results:** Totally 16 patients were diagnosed to have xanthogranulomatous reaction in various sites. It was found in association with various conditions like radicular cyst, anal fistula, cholecystitis, synovitis, pyelonephritis, mastitis, serous cystadenoma of ovary, vaginal wall mullerian cyst, epididymo-orchitis and ruptured epidermal cyst. PAS showed diffuse granular cytoplasmic staining which differentiates it from malakoplakia. **Conclusion:** Most xanthogranulomas present as a mass lesion extending to adjacent structures and can mimic infiltrating carcinoma. It may also accompany inflammatory signs like pain, fever, leukocytosis due to delayed type hypersensitivity reaction. Therefore distinguishing infections from neoplasm for further management is important. So histopathology is essential for confirmation of the lesion.

Keywords: foam cells, lipid rich macrophages, foamy macrophages, xanthogranuloma.

*Address for Correspondence:

Dr. Ronald J. Bosco, P. G. Student, Department of Pathology, Sri Manakula Vinayagar Medical College, Pudhucherry-605107, INDIA.

Email: ronaldaswathy@gmail.com

Received Date: 24/11/2014 Accepted Date: 05/12/2014

Access this article online	
Quick Response Code:	Website: www.statperson.com
	DOI: 05 December 2014

INTRODUCTION

Xanthogranulomatous reaction (XG) are usually incidental findings in the histopathological sections. They can mimic malignant neoplasm both clinically and radiologically if the lesions are large enough grossly.^{1,2,3,4,5} They can be induced or associated with neoplastic/ inflammatory processes.⁶ Xanthogranulomatous reaction is a chronic inflammatory disease. Histologically lesions are characterised by collection of foamy macrophages admixed with polymorphonuclear leukocytes, activated plasma cells

and lymphocytes in a mosaic pattern with fibrosis and tissue destruction.^{6,7,8,9}

AIMS AND OBJECTIVES

1. To differentiate these lesions from simulating neoplastic and non neoplastic conditions.
2. To identify the associated and underlying lesions.

MATERIALS AND METHODS

Biopsy and excision specimens with a histopathological diagnosis of xantho - granulomatous reaction from varying sites were taken for the study for a period of 2 years from 2012 to 2013 in the department of Pathology, SMVMCH

OBSERVATIONS AND RESULTS

16 cases were diagnosed to have xanthogranulomatous reaction (XG) in various sites associated with various lesions. Patients' age ranged from 21 years to 63 years and there was no sex predilection. Most are chronic inflammatory conditions due to infections which did not respond well to antibiotic therapy. Few are benign lesions/ tumors / cysts.

Table 1: Organs involved with associated lesions in the present study

Sr. No	Organs involved	Associated lesions
1	Gall bladder(2)	Chronic calculous cholecystitis
2	Kidney	Chronic pyelonephritis
3	Peri anal fistulous tract(2)	Fistula in ano (granulomatous inflammation with foreign body)
4	Cyst in dental region(2)	Radicular cyst
5	Breast (2)	Granulomatous mastitis
6	Synovial tissue	Non specific synovitis
7	Spleen	Epithelial cyst of spleen
8	Vaginal wall cyst	Bartholin cyst
9	Skin	Epidermal cyst
10	Soft tissue	Cysticercosis
11	Appendix	Eosinophilic appendicitis with E. Vermicularis
12	Testis	Pyocele, epididymoorchitis and infarction of testis

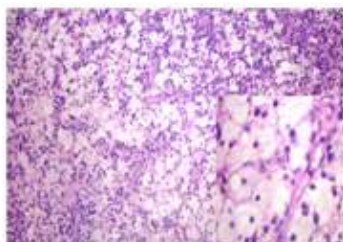


Figure 1: Ulcerated radicular cyst wall with foamy macrophages HandE, 10X. INSET- foamy macrophages. 40x

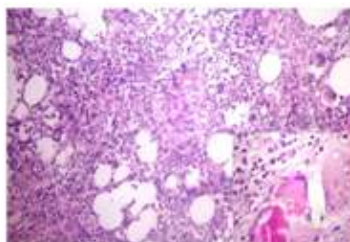


Figure 2: Foamy cells infiltrating the surrounding fat in gall bladder mimicking malignant lesion H and E 40x. Inset foreign body giant cells accompanying mucin H and E, 40x.

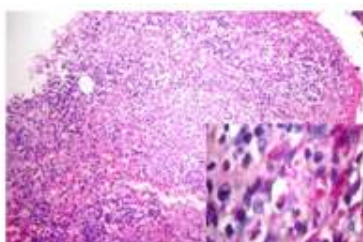


Figure 3: Xanthogranulomatous reaction in synovial tissue HandE, 10x. Inset Histiocytes with PAS +ve, diastase resistant granules PAS, 40x

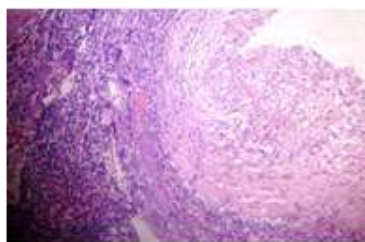


Figure 4: Splenic cyst wall showing xanthogranulomatous reaction HandE 4x.

DISCUSSION

XG is a rare chronic inflammatory disease which may be a focal or diffuse destructive inflammatory process, with accumulation of lipid-laden fibrous tissue, and acute and chronic inflammatory cells. It may involve any organ. Most common sites being gallbladder and kidney which can coexist with inflammatory / neoplastic conditions.^{6,7,8,9,10} Large lesions mimic malignant tumors in radiologic findings leading to radical procedures. In addition no biochemical or hematological markers are available. Imaging studies, fine needle aspiration cytology, and clinical endoscopy may be suggestive but not confirmatory. Multiple biopsies may show only acute and chronic inflammation.^{5,6,7,8,9,10}

Histopathology

Their macroscopic appearance varies from bright yellow or golden yellow mass-like lesions associated with abscess cavities. They present with microabscesses, and lipid-rich macrophage with extensive fibrosis under microscopic examination.^{6,7,8} PAS positive and diastase resistant granules are seen in cytoplasm. There is no minimum requirement for histiocytes to make the diagnosis.^{6,7,8,9,10} In the presence of soft tissue around the lesion, adjacent tissue is accompanied by severe infiltration forming an inflammatory mass.¹

Pathogenesis

Exact pathogenesis of XG is not well established. Chronic recurrent infection, obstruction, immunologic disorders, and defective lipid transport are suggested. Obstructive hypothesis is suggested for cholecystitis, pyelonephritis and appendicitis; chronic irritation by the urachal

remnants in bladder dome for bladder lesions; altered immune responses for Inflammatory bowel disease, rupture of Rokitansky Asch off sinus and extravasation of bile for gall bladder lesions. Less common causes include ineffective antibiotic use, in association with neurofibromatosis, urticaria pigmentosa of skin, which occurs mostly in infancy with 20% of them being congenital and having good prognosis. XG reaction is

common in ruptured acute appendicitis treated with antibiotics / interval appendectomy due to prolonged inflammation associated with tissue damage and microscopic perforation caused by foreign material.^{1,6,7,8,9,10} Foam cells are formed by various causes like ineffective antibiotic therapy for infections, hyperlipidemia, due to prolonged IUCD use, eluting drugs which have lipoid substance.

Table 2: Differential diagnosis of XG in various organs

Sr. No	Site of XG	Differential diagnosis
1	Genito urinary system	RCC, spindle cell neoplasm of kidney(CD 68+, CK- ve), angiomyolipoma ^{4,10}
2	Appendix	Mucocele, Pseudomyxoma peritonei, signet ring cell carcinoma of appendix ^{2,7}
3	Small intestine	Crohns disease ^{3,7}
4	Bone	Osteolytic lesions, Langerhan cell histiocytosis
5	Colon	Malignancy ^{3,7}
6	Female genital tract	Sclerosing stromal tumor(foam cells and fibrosis)
7	Endometrium	Malignancy, may also show underlying malignancy ¹⁰
8	Soft tissue	Inflammatory malignant fibrous histiocytoma
9	Skin	Langerhan cell histiocytosis, fibrous histiocytoma, xanthoma ¹

CONCLUSION

Xanthogranulomatous reaction is usually incidentally identified. It is inflammatory and invasive in nature and hence a complete resection of adjacent adhesive tissues should be attempted. Histopathology is presently the gold standard for diagnosis, as the underlying lesion/ malignancy causing it can also be identified.

Xanthogranulomatous reaction must be considered in

1. Lesions presenting with inflammatory symptoms followed by a mass mimicking malignancy
2. Repeated biopsies showing histiocytes along with other inflammatory reactions
3. Fibrosis in clinically and radiologically suspected cases of malignancy

REFERENCES

1. Arun A et al. Multiple generalized xanthogranuloma in adult: case report and treatment. *Indian J Dermatol* 2011; 56(2): 197–199.

2. Kazunari Mado et al. Xanthogranulomatous appendicitis. *Indian Journal of Surgery* 2013; 75(5): 405-406.
3. Chuang YF et al. Xanthogranulomatous appendicitis. *J Formos Med Assoc* 2005; 104(10):752-4.
4. Li L et al. Xanthogranulomatous pyelonephritis. *Arch Pathol Lab Med* 2011; 135(5):671-4.
5. Koo JS et al. Xanthogranulomatous mastitis: clinicopathology and pathological implications. *Pathol Int* 2009; 59(4):234-40.
6. Juan Rosai. Rosai and Ackerman’s *Surgical Pathology*. 9th ed. New Delhi: Elsevier; 2004.
7. Ozde RD et al. *Surgical Pathology of the GI Tract, Liver, Biliary tract and Pancreas*. 2ed. Piladelphia: Elsevier; 2009.
8. *FDiagnostic Histopathology of Tumors*, Christopher D. M. Fletcher, 4ed.
9. Weidner et al. *Modern Surgical Pathology*. 2nd ed. Piladelphia: Elsevier; 2009.
10. Ming Z et al. *Genitourinary Pathology: A volume in foundations in diagnostic pathology series*.
11. Gattuso et al. *Differential diagnosis in surgical pathology*. 2nd ed. Piladelphia: Elsevier; 2010.

Source of Support: None Declared
Conflict of Interest: None Declared