

Intra operative management of a case of pheochromocytoma excision by thoracic approach - a nightmare for the anaesthesiologist

Debashish Paul^{*}, Col Manu Tandon^{**}, Maj Bhupendra^{***}

^{*}Specialist, Department of Anaesthesiology, Indian Naval Hosp Kalyani, Vishakhapatnam, Pin-530005, Andhra Pradesh, INDIA.

^{**}Senior Advisor, Department of Anaesthesiology, Military Hospital, Jabalpur, Madhya Pradesh, INDIA.

^{***}Resident, Department of Anaesthesiology, AFMC, Pune-40, Maharashtra, INDIA.

Email: drdpaulamc@rediffmail.com

Abstract

Pheochromocytoma is a potentially lethal catecholamine containing tumor of chromaffin tissues. The classic triad of headache, palpitation and diaphoresis is present in up to 70% of the cases and only 50% have sustained hypertension. The best approach for pheochromocytoma treatment is surgical excision of the affected adrenal gland. Although uncommon type of tumor, pheochromocytomas present a great challenge to the Anaesthesiologist, since it has unspecific clinical symptoms, complex detection tests and possibility of unfavorable results, including death when not previously diagnosed. The perioperative course and anesthetic management of patients with catecholamine-secreting pheochromocytoma has typically been reported only in small case series because of the infrequent incidence of these tumors. In this report, we describe a successful management of a case of Normetanephrine secreting bilateral adrenal and Rt Subhepatic region & Lt Paravertebral region pheochromocytoma that underwent excision with favorable outcome. Because of surgical approach for excision by thoracotomy, one lung ventilation (OLV) was established which is itself a challenge for the Anaesthesiologist.

Keywords: Pheochromocytoma; Anesthesia Management; Normetanephrine; OLV.

*Address for Correspondence:

Dr. Debashish Paul, Specialist, Department of Anaesthesiology, Indian Naval Hosp Kalyani, Vishakhapatnam, Pin-530005, Andhra Pradesh, INDIA.

Email: drdpaulamc@rediffmail.com

Received Date: 28/02/2015 Revised Date: 05/03/2015 Accepted Date: 08/03/2015

| Access this article online | |
|---|--|
| Quick Response Code: | Website: www.statperson.com |
|  | DOI: 10 March 2015 |

INTRODUCTION

Pheochromocytoma is a catecholamine secreting tumour which may arise anywhere in the body other than its primary site¹. Symptoms are mainly because of excessive secretion of catecholamines (norepinephrine, epinephrine, or dopamine) into the circulation². The released catecholamines cause significant hypertension, often severe and refractory to conventional treatment¹⁻⁶. Early diagnosis and definitive treatment with surgical resection is important because the tumour may be fatal if undiagnosed, especially in patients undergoing surgery

for other disorders or in pregnant women during delivery^{1,5}. Perioperative management of pheochromocytoma remains a highly stressful situation for the anaesthesiologists². Appropriate preoperative medical management dramatically decreases morbidity and mortality during the operative management of this tumour⁶. This case report emphasizes the preoperative and intra-operative anaesthetic management by establishing one lung ventilation intra-operatively and postoperative care in the intensive care unit.

CASE HISTORY

A 40 year old male weighing 67 kg presented as a case of uncontrolled hypertension for 1 year, pain right lower abdomen-02 years with h/o dysuria-02 months. Clinical examination showed blood pressure 150/100. Respiratory and cardiovascular system-NAD. USG Abdomen- Mild Cortical Scarring in the inferior pole of Right Kidney. CECT abdomen suggests B/L dense enhancing heterogenous adrenal mass lesion (Right>Left), intensely enhancing right supra renal tumors with left para-aortic lesions, extra-adrenal lesions in the aorto-caval and para aortic location.



Figure 1:



Figure 2:

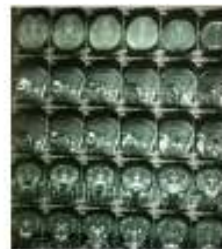

Figure 3:

MRI abdomen-s/o right adrenal, superior mesenteric and left paraaortic pheochromocytoma. I-131 MIBG Whole Body Scan -- B/L catecholamine secreting masses in Right Subhepatic Region and Left Paravertebral Region (ref fig:1-3). MRI Brain- ruled out von Hippel Lindau Disease; 24 hr Urine-Metanephrines-78.21 ug/g creatinine (ref range-27-155), Marked elevation in levels of Normetanephrines -1977.37 ug/g creatinine (ref range-46-256), VMA 30.45(1.60-4.20)g/24hours consistent with the diagnosis of pheochromocytoma. However dopamine level was normal 119.96(52-480)g/24hours. Fundoscopy showed- retinal folds over macula and polypoidal subretinal mass 1.5 disc diameter in the right eye with overlapping tortuous vessels. Evidences of orthostatic hypotension was ruled out during pre-operative evaluation. METS > 4. Routine investigations and biochemical examinations reports were within normal

limit. Cortisol level (Post dexamethasone administration) was 2.99 ug/dl (27-155 ug/dl). Chest X-Ray and ECG-normal. 2-D echo was normal with LVEF-60%. PFT was normal. Cardiovascular and endocrinological evaluations were done in detail. Following pre-operative optimization of blood pressure and adequate intra vascular volume replacement, patient was taken up for open adrenalectomy with excision of the tumour mass from the extra-adrenal site by thoracotomy approach. Angiogram and angio-embolisation of the tumour was done at intervention radiology centre under conscious sedation along with invasive monitoring of blood pressure (ref fig:4-6). Embolization of right middle and inferior suprarenal and bilateral lumbar arteries at L1 level, coiling in left lumbar branch and paravertebral branch of middle suprarenal artery was done.

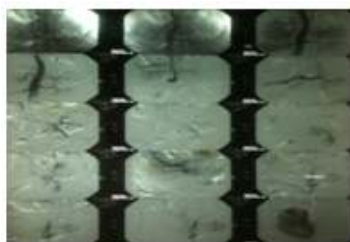

Figure 4:

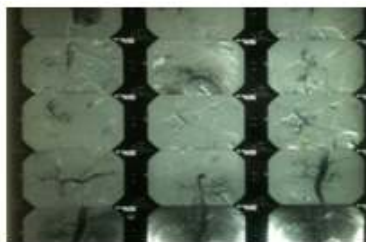


Figure 5:

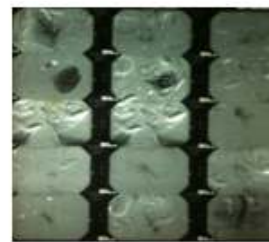


Figure 6:

Post embolization, α -blocker(prazosin), $\alpha+\beta$ blocker(carvedilol) and Ca^{2+} Channel blocker(amlodipine) were continued. Anaesthesia goals were planned for 1)management of haemodynamic instability. 2) one lung ventilation as surgery was by thoracic approach.3) prevention of hypothermia and adequate hydration. 4) changes due to Cork-screw positioning. 5) postoperative ventilation with adequate pain management. Tab alprazolam 0.5mg was given in the night before and 2 hrs prior to surgery. Patient was wheeled to the operating room. Cannulation of Lt Radial artery and thoracic epidural at T-10/T-11 level under local anaesthesia were established. Following preoxygenation, pre-medication was done with inj fentanyl - 0.3ugm/Kg iv, inj ondansetron 6 mg iv, inj midazolam 2 mg iv. Induction was done with inj

propofol@ 2 mg/kg followed by inj vecuronium 100 ugm/kg. Double Lumen Tube of size 39 Fr (left sided) was placed and confirmed by auscultation, capnometry and by fiber optic bronchoscopy. Haemodynamic variations was less than 20% from Basal parameters. Maintenance of Anaesthesia was done with O_2 and Isoflurane (1%-1.4%). Rt subclavian vein was cannulated for inotropes infusion and CVP monitoring. Epidural analgesia was continued by infusion following bolus dose. Surgical manipulation of tumour specially the extra adrenal tumour resulted in haemodynamic variation with tachycardia followed by bradycardia, changes in mean arterial pressure ranging from 28-210 mm of Hg. This extreme variation in blood pressure and heart rate required sodium nitroprusside infusion at a rate of @ 0.2-0.7ug/kg/min, inj fentanyl-250 ug iv and inj pheylephrine

-500 ug in divided doses, inj metoprolol-2 mg iv, inj mephentermine-15 mg, nitroglycerin infusion@5-30ug/min, infusion of noradrenaline @.06-.08 ug/kg/min and infusion of phenylephrine @ 3.3 ug/min by titration. Insulin Infusion @ 1 IU/hour was started as blood sugar was > 200 mg/dL. Ligation of adrenal vein and removal of tumor resulted in decrease in systolic BP. Also retraction and compression of the IVC resulted in labile blood pressure. Intra operative fluid were ringer lactate - 5000 ml, 0.9% normal saline -2000 ml, packed red blood cells-1000 ml and fresh frozen plasma-600 ml. Urine output was 1450 ml. Blood loss was estimated as 2900 ml. Prevention of lung atelectasis and desaturation was managed with intermittent application of PEEP and insufflation of oxygen with 100 % oxygen. Ventilation was guided by serial arterial blood gas analysis (*ref table-I*).

Table 1: Intra-op ABG

| Sr. No. | Time | Ph | Pco2 | Hco3 | Pao2 | Fio2 |
|---------|------|------|------|------|-------|------|
| 1 | 0840 | 7.37 | 36.5 | 25.4 | 140.2 | 0.5 |
| 2 | 1130 | 7.29 | 40.2 | 19.2 | 118.6 | 1 |
| 3 | 1400 | 7.32 | 36.5 | 17.2 | 156.7 | 1 |
| 4 | 1700 | 7.34 | 32.6 | 15.5 | 180 | 1 |

Surgery lasted for 09 hours and 55 minutes. After placing right sided ICD patient was shifted to the ICU for post op elective ventilation. Epidural infusion of 0.125% bupivacaine was continued in the post operative period. Sedation with propofol infusion @25-75 ug/Kg/Min and infusion of noradrenaline and phenylephrine were tapered off before extubation. Adequate analgesia was maintained with continuous epidural analgesia. Patient made an uneventful recovery and discharged on 7th post operative day.

DISCUSSION

Anaesthetic management of a case of pheochromocytoma is a challenge even in best of centers. Co-ordination with Surgeon, valuable inputs from the Cardiologist and Endocrinologist with optimization of conditions is necessary and a must in pre-operative preparation. Most of the time this tumour remains undiagnosed. But once diagnosed, the best approach for pheochromocytoma treatment is surgical excision of the affected adrenal gland⁷. MIBG (meta-iodobenzyl guanidine) scintigraphy is the best choice of investigation to detect tumours at extra-adrenal site⁸. Optimization of blood pressure and maintaining adequate intra-vascular volume, avoidance of stress is the key word to prevent catecholamine surge. All efforts like cautious transferring of patient, left radial artery cannulation under local anaesthesia, thoracic epidural analgesia were made to prevent any stimulus for

catecholamine release. DLT was placed with minimal laryngoscopic and intubation reflex. These reflexes were abolished by epidural analgesia and premedications. Opioids (Inj Fentanyl), beta adrenergic agonist (Inj metoprolol), infusion of phenylephrine, nitroglycerin and noradrenaline, bolus doses of mephenteramine were administered. Drugs were kept prepared before induction. To prevent hypotension following sudden decrease in catecholamine level after adrenal veins ligation, adequate fluid balance with vasopressors were used. Intra operative hyperglycemia was managed by insulin infusion. Post-operatively, there was no evidence of hyperglycemia as suppression of beta-pancreatic cells is less following tumour removal and increase in endogenous Insulin level⁹. Hypoxemia was overcome as per guideline for OLV in the intra-op period¹⁰. It was evident that well preparation before hand for the anaesthetic management of case of Pheochromocytoma is the key for a good outcome. Intra-op vigilance and prompt reaction to a situation is the mainstay of success in managing such a challenging case.

REFERENCES

1. Vuguin P, Perez N, Monsalve MM. Pheochromocytoma. Web article from eMedicine Specialties>Pediatrics>Oncology. Last updated: June 5, 2006. eMedicine from WebMD. www.emedicine.com/ped/topic1788.htm
2. Prys-Roberts C. Pheochromocytoma - recent progress in its management. Br J Anaesth 2000; 85:44-57.
3. Singh G, Kam P. An overview of anaesthetic issues in Pheochromocytoma. Ann Acad Med Singapore 1998; 27:843-8.
4. Kariya N, Nishi S, Hosono Y, Hamaoka N, Nishikawa K, Asada A. Cesarean section at 28 weeks' gestation with resection of pheochromocytoma: perioperative antihypertensive management. J Clin Anesth 2005; 17:296-9.
5. Kinney MA, Narr BJ, Warner MA. Perioperative Management of Pheochromocytoma. J Cardiothorasc Vasc Anesth 2002; 16:359-69.
6. Schiff RL, Welsh GA. Perioperative evaluation and management of the patient with endocrine dysfunction. Med Clin N Am 2003; 87:17592.
7. Pheochromocytoma Anesthetic Management, Daniel D. Kim, Christiano Matsui, Judymara L. Gozzani, Ligia A. S. T. Mathias, Open Journal of Anesthesiology, 2013, 3, 152-155
8. Kinney MA, Narr BJ, Warner MA. Perioperative Management of Pheochromocytoma. J Cardiothoracic Vascular Anesthesia; 2002; 16:359-69.
9. Hull CJ. Pheochromocytoma: Diag, pre-op prep and anaes management. Br J Anaes 1986; 58:1453-68.
10. Gosh S, Latimer R.D, Thoracic anaesthesia : Principles and practice. Oxford :Butterworth Heinemann; 1999

Source of Support: None Declared
Conflict of Interest: None Declared