

Inverted Meckel's diverticulum as a leading point for ileoileal intussusceptions in an infant: a case report

S R Kulkarni¹, Ashar Shaikh^{2*}, Ronak Chaudhari³, Sandeep Gupta⁴, Tejas Chincholi⁵, Kishor Bandagar⁶

¹Professor, ^{2,3,4,5,6}Resident, Department of General Surgery, Krishna Institute of Medical Sciences, Karad, Maharashtra, INDIA.

Email: ashars97@gmail.com

Abstract

Meckel's Diverticulum and intussusception are relatively common but the combination is quit infrequent. Intestinal obstruction due to inverted Meckel's Diverticulum is rare. There are various mechanism by which it can cause intestinal obstruction such as intussusception. We report the case of a 8 month old infant operated on emergency for acute intestinal obstruction. Surgical exploration confirmed a rare type of obstruction due to Meckel's diveerticulum.

Keywords Meckel's diverticulum.obstruction

*Address for Correspondence:

Dr. Ashar Shaikh, Resident, Department of General Surgery, Krishna Institute of Medical Sciences, Karad, Maharashtra, INDIA.

Email: ashars97@gmail.com

Received Date: 24/02/2015 Revised Date: 05/03/2015 Accepted Date: 11/03/2015

Access this article online	
Quick Response Code:	Website: www.statperson.com
	DOI: 15 March 2015

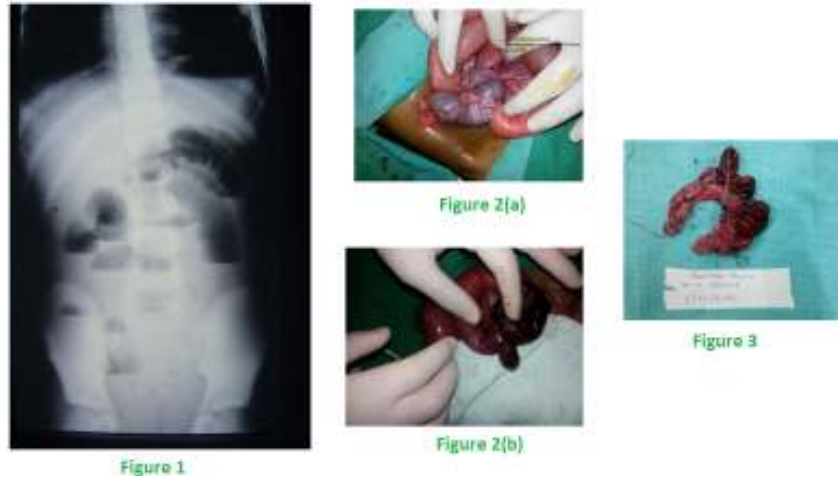
INTRODUCTION

Meckel's diverticulum(MD) is named the remnant of the omphalomesentric duct, which is normally obliterated by the 5th week of gestation. The name is derived from a German anatomist Jhinn Fridrich Meckel who described the embryological and pathological features in 1801.¹ The main complication of MD is small bowel obstruction², bleeding³, perforation⁴ and acute inflammation.⁵

CASE REPORT

A 8 month old female infant child admitted in our hospital with abdominal distension, excessive cry, fever, vomiting and signs of intestinal obstruction of three days

duration. The patient was second child in the family and his birth & feeding history were normal. On abdominal examination abdomen was markedly distended there was no lump palpable on both abdominal and rectal examination. The laboratory data were not contributing, except an increase in white blood cell count(14,000/mL) with neutophilic predominance(80%). Abdominal X-Ray demonstrated dilated small bowel loops(fig. 1). We made a preoperative diagnosis of acute intestinal obstruction on the basis of ultrasound findings which is suggestive of multiple dilated bowel loops with to and fro peristalsis in left upper quaderent and in periumbilical region with dilated large bowel s/ostrecture?cecal volvulus?, but we didn't know the exact cause. On laperotomy we found An intussusception was found with around 5 inches of ileum prolapsed through the ileocecal valve. This was reduced by expulsion and at the apex of intussusceptum was found a Meckel's diverticulum about 1cm in length by squeezing the diverticulum was everted and was gangrenous along with distal ileum(Fig. 2a and b). The gangrenous diverticulum along with ileum is resected out and ileostomy was done (Fig.3). The post operative course was uneventful and the patient recovered quickly 6 days postoperatively. The histological examination showed no abnormality.



Legend:

Figure 1: abdominal X-Ray showing dilated bowel loop

Figure 2(a) and Figure 2(b): preoperative view showing MD strangulating the small bowel, and photo after expulsion, showing gangrenous MD

Figure 3: The small bowel including Meckel's diverticulum resected

DISCUSSION

Meckel's diverticulum is the remnant of the prenatal yolk stalk (vitello-intestinal duct). The yolk sac of the developing embryo is connected to primitive gut by the yolk stalk or omphalomesenteric duct. This structure normally regresses between the fifth and seventh week of fetal life. If this process of regression fails, various anomalies can occur. The spectrum of defects includes Meckel's diverticulum, a fibrous cord attaching the distal ileum to the abdominal wall, an umbilical intestinal fistula. Of these Meckel's diverticulum is the most common congenital anomaly of the gastrointestinal tract in humans occurring in approximately 2% of the population with equal incidence in male and female.⁶

The three most common complications of Meckel's diverticulum are bleeding, obstruction and inflammation. There are various mechanisms by which it can cause intestinal obstruction.⁷

- Volvulus of small intestine around a fibrous band extending from Meckel's diverticulum to umbilicus.
- Littre's hernia: Incarceration of diverticulum in hernia (inguinal and femoral) causing intestinal obstruction
- Intussusception: Meckel's diverticulum sags into the bowel lumen and then serves as lead point to allow telescoping of small intestine into first the distal ileum and then into the large intestine causing ileoileal and ileocolic types of intussusceptions.
- Stricture secondary to chronic diverticulitis.

- Meckel's diverticulum lithiasis can cause small bowel obstruction by two mechanisms (it can cause impaction in terminal ileum after its extrusion from the diverticulum and (2) by promoting local inflammation of the diverticulum

CT is rarely used when Meckel's diverticulum is suspected because of distinction between a diverticulum and intestinal loops are usually impossible. Even though CT is more specific than US.⁸ Laparoscopy is a safe diagnostic and therapeutic tool that can overcome all diagnosis problems. It decreases the time spent for diagnosis and theoretically avoids the morbidity and mortality of a delayed diagnosis while keeping costs at minimum.⁹

CONCLUSION

Intussusception is a condition in which one portion of the bowel, usually proximal to the ileocecal valve, invaginates into an adjacent segment. This process leads to bowel wall edema which progressively causes obstruction of venous outflow. The bowel becomes secondarily ischemic, which can eventually lead to necrosis and perforation. Ileocolic intussusceptions are the most common with ileoileal, cecocolic, colocolic, and jejunojejunal, occurring less often.⁹ Intussuscepted Meckel diverticulum is rare. Symptoms caused by Meckel diverticulum are abdominal pain, bleeding and intestinal obstruction. Obstruction is usually due to the congenital mesodiverticular band but occasionally results from intussusception. Infrequently, Meckel diverticulum can invert and invaginate into the ileal lumen. Inversion

of Meckel diverticulum is not yet clearly understood. One theory is that abnormal peristaltic movement due to ulceration or ectopic tissue at the base of Meckel diverticulum may cause it to invert. The pre operative diagnosis by US, CT examination is rarely possible. Laparoscopy may help in diagnosis and treatment of this rare pathology.

REFERENCES

1. Raymond P (2007) Adjunctive procedure in intestinal surgery. In mastery of surgery, 5th edn, pp.1392-1393
2. Catarci M, Zaraca F, Scaccia M, Gossetti F, Negro P, Carboni M (1995) Laparoscopic management of volvulated Meckel's diverticulum. *Surg Laprosc* 5:72-74
3. Imdhal A (2001) Gnesis and pathophysiology of lower gastrointestinal bleeding. *Langenbecks Arch Surg* 386:1-7
4. Schmid SW, Schafer M, Krahenbuhl L, Buchler MW (1999) The role of laparoscopy in symptomatic Meckel's diverticulum. *Surg Endosc* 13:1047-1049
5. Sarli L, Costi R (2001) Laparoscopic resection of Meckel's diverticulum: report of two cases. *Surg Today* 31:823-825
6. Evers BM (2004) small intestine. In Sabiston textbook of surgery, 17th edn. Townsend CM Elsevier, pp.1366-1368
7. Sharma RK, Jain VK (2008) Emergency surgery for Meckel's diverticulum. *World J Emerg Surg* 3:27
8. Rivas H, Cacchione RN, Allen JW (2003) Laparoscopic management of Meckel's diverticulum in adults. *Surg Endosc* 17:620-622
9. M. D. Stringer, S. M. Pablot, and R. J. Brereton, "Paediatric intussusception," *British Journal of Surgery*, vol. 79, no. 9, pp. 867-876, 1992.

Source of Support: None Declared
Conflict of Interest: None Declared