Research Article

Clinical evaluation of extratesticular lesion: A hospital based study

A Setu Madhavi[1*], K C T Naik[2]

[1]Assistant Professor, [2]Associate Professor, Department of Surgery, RIMS Medical College, Ongole, Andhra Pradesh, INDIA.
Email: madhavi5ayodhya@gmail.com, drkctnaik@yahoo.com

Abstract

Introduction: Scrotal masses may be intratesticular or extratesticular, either solid or cystic. Most of the intratesticular masses should be considered malignant unless proved otherwise. Extratesticular cystic masses are almost certainly benign, whereas extratesticular solid masses have a malignant rate of 16%, which though being much lower than intratesticular masses, is high enough to be of concern. **Amis and Objectives:** To evaluate the clinical features of extratesticular lesion confirmed by USG and FNAC. **Materials and Method:** The present study was conducted in the department of surgery of RIMS medical college. To achieve the above, mentioned objective, all the patients of scrotal lesion attending the various OPDs were enrolled in the study. Thus total 71 cases of scrotal lesion were diagnosed during the study duration. Out of these 19 were excluded from the study as they were of testicular origin. 52(73.24%) were confirmed to be extratesticular lesion. The detail history of all the patients was taken which followed by clinical examination. All the positive findings were recorded in a prestructured proforma. The diagnosis of extra testicular lesion was confirmed by USG and FNAC wherever required. **Results:** In the present study total 71 cases of scrotal lesion with various complaints were presented in the surgery OPD, out of them 52 (73.24%) were of extratesticular origin whereas 19 (26.76%) were testicular origin. Majority of the patients (40.38%) with extra testicular swelling were 21-30 years of age. 61.54% presented with scrotal enlargement, while 3.85% complaint of multinodular swelling and 1.92% with massive swelling. Acute scrotal pain was the presenting complaint in 28.85% and mild pain was reported by 30.77% cases. 5.77% cases complaint of dragging pain. Chronic epididymitis was diagnosed in 30.77% cases whereas acute epididymitis was diagnosed in 15.38% cases. Hydrocele was diagnosed in 19.23% cases. Acute epididymo-orchitis was diagnosed in 5.77% cases. In 5.77% cases scrotal sewing was due to trauma. **Conclusion:** Thus we conclude that majority of scrotal lesions were extratesticular origin. Epididymitis was the common extra testicular origin, out of which acute Epididymitis presents with fever, swelling, and acute pain whereas chronic epididymitis present with swelling and mild pain.

Keywords: extratesticular lesion, epididymitis, acute pain, swelling.

[*]**Address for Correspondence:**
Dr. A Setu Madhavi. 1Assistant Professor, Department of Surgery, RIMS Medical College, Ongole Andhra Pradesh, INDIA.
Email: madhavi5ayodhya@gmail.com
Received Date: 20/06/2015 Revised Date: 29/06/2015 Accepted Date: 01/07/2015

Access this article online	
Quick Response Code:	Website: www.statperson.com
	DOI: 01 July 2015

INTRODUCTION

Scrotal masses may be intratesticular or extratesticular, either solid or cystic. Most of the intratesticular masses should be considered malignant unless proved otherwise. Extratesticular cystic masses are almost certainly benign, whereas extratesticular solid masses have a malignant rate of 16%, which though being much lower than intratesticular masses, is high enough to be of concern.[1-1]. The acute scrotum is a medical emergency defined as scrotal pain, swelling, and redness of acute onset[1,2,3]. The differential diagnosis includes torsion, infection, trauma, tumor, and other rarer causes. The diagnostic evaluation begins with history-taking. Scrotal abnormalities can be divided into three groups, which are extra-testicular lesion, intra-testicular lesion and trauma. Causes of scrotal pain include inflammation (epididymitis, epididymo- orchitis, abscess), testicular torsion, testicular trauma, and testicular cancer.[4,5] The evaluation of extratesticular swelling by clinical examination and history is not sufficient; thus use of sonography and FNAC has increased to confirm the diagnosis. Micallef M *et al* conducted a retrospective study of 582 patients to

How to site this article: A Setu Madhavi, K C T Naik. Clinical evaluation of extratesticular lesion: A hospital based study. *International Journal of Recent Trends in Science and Technology.* July 2015; 15(3): 444-447 http://www.statperson.com (accessed 02 July 2015).

establish the cause of scrotal swelling, define the role of high frequency ultrasound examination in the management of scrotal swellings. The study concluded that ultrasound examination distinguishes extratesticular (almost always benign) from intra testicular (potentially malignant) causes of scrotal swelling. Infection, trauma, and torsion mimic the ultrasound appearance of tumor as do rare benign entities[6]. Fine needle aspiration cytology (FNAC) has proved to be of great diagnostic importance in testicular lesions, its scope in extratesticular lesions is largely unexplored.

AMIS AND OBJECTIVES

To evaluate the clinical features of extratesticular lesion confirmed by USG and FNAC.

MATERIAL S AND METHOD

The present study was conducted in the department of surgery of RIMS medical college. To achieve the above, mentioned objective, all the patients of scrotal lesion attending the various OPDs were enrolled in the study. Thus total 71 cases of scrotal lesion were diagnosed during the study duration. Out of these 19 were excluded from the study as they were of testicular origin. 52(73.24%) were confirmed to be extratesticular lesion. The detail history of all the patients was taken which followed by clinical examination. All the positive findings were recorded in a prestructured proforma. The diagnosis of extra testicular lesion was confirmed by USG and FNAC wherever required.

RESULTS

Table 1: Distribution according to type of lesion

Type of lesion	No. of patients	Percentage
Extratesticular lesion	52	73.24%
Testicular lesion	19	26.76%
Scrotal lesion	71	100.00%

In the present study total 71 cases of scrotal lesion with various complaints were presented in the surgery OPD, out of them 52 (73.24%) were of extratesticular origin whereas 19 (26.76%) were testicular origin.

Table 2: Age wise distribution of patients

Age (years)	No. of patients	Percentage
<10	1	1.92%
11-20	9	17.31%
21-30	21	40.38%
31-40	10	19.23%
41-50	6	11.54%
51-60	4	7.69%
>60	1	1.92%

It was observed that majority of the patients (40.38%) with extra testicular swelling were 21-30 years of age, followed by 31-40 years (19.23%) and 11-20 years (17.31%).

Table 3: Distribution according to presenting complaints

Complaints	No. of patients	Percentage
Acute pain	15	28.85%
Mild pain	16	30.77%
Dragging pain	3	5.77%
scrotal enlargement	32	61.54%
Massive swelling	1	1.92%
Multinodular swelling	2	3.85%
Fever	9	17.31%

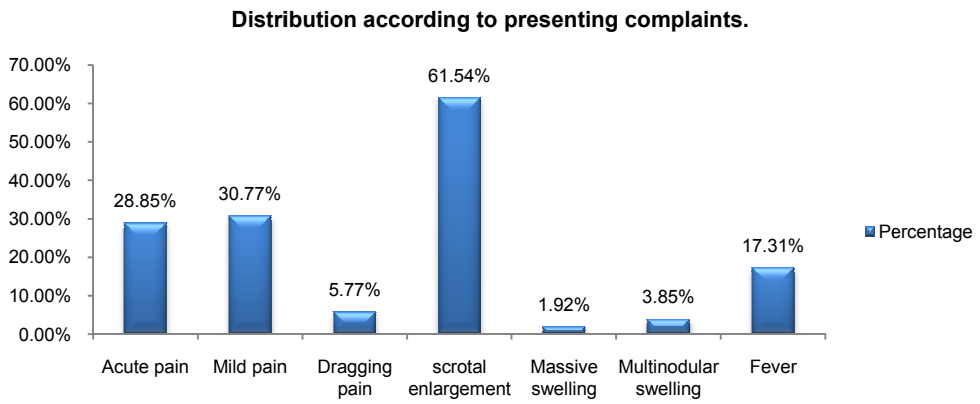

The most common presenting complaint was scrotal swelling. 61.54% presented with scrotal enlargement, while 3.85% complaint of multinodular swelling and 1.92% with massive swelling. Acute scrotal pain was the presenting complaint in 28.85% and mild pain was reported by 30.77% cases. 5.77% cases complaint of dragging pain.

Table 4: Distribution according to diagnosis

Diagnosis	No. of patients	Percentage
Acute epididymitis	8	15.38%
Acute epididymo-orchitis	3	5.77%
Hydrocele	10	19.23%
Hematocele	2	3.85%
Pyocele	1	1.92%
Epididymal cyst/	2	3.85%
Spermatocele	1	1.92%
Chronic epididymitis	16	30.77%
Elephantiasis	1	1.92%
Varicocele	3	5.77%
Scrotal calcinosis/	1	1.92%
sebaceous cyst	1	1.92%
Trauma	3	5.77%

Chronic epididymitis was diagnosed in 30.77% cases whereas acute epididymitis was diagnosed in 15.38% cases. Hydrocele was diagnosed in 19.23% cases. Acute epididymo-orchitis was diagnosed in 5.77% cases. In 5.77% cases scrotal sewing was due to trauma.

DISCUSSION

The present study was conducted in the department of surgery of RIMS medical college. Total 71 cases of scrotal lesion were diagnosed during the study duration. Out of them 52(73.24%) were confirmed to be extratesticular lesion. The findings were comparable with Rholl *et al.*[7] study, who observed 80% cases of extratesticular lesion in their study. It was seen that majority of the patients (40.38%) with extra testicular swelling were 21-30 years of age, followed by 31-40 years (19.23%) and 11-20 years (17.31%). The most common presenting complaint was scrotal swelling. 61.54% presented with scrotal enlargement, while 3.85% complaint of multinodular swelling and 1.92% with massive swelling. Acute scrotal pain was the presenting complaint in 28.85% and mild pain was reported by 30.77% cases. 5.77% cases complaint of dragging pain. The acute scrotum is a medical emergency and it is defined as scrotal pain, swelling and redness of acute onset. The differential diagnosis includes torsion, infection, trauma, tumor and rarer causes.[1,2] The diagnostic evaluation of scrotal lesions begins with proper history-taking. The patient should be asked about the exact temporal course of events, the intensity of the pain, and in particular, when the pain began and in the trauma what is the traumatic mechanism (blunt, penetrating, degloving, and electrical burn injuries to scrotal contents). Trauma often may result in hematoma, hydrocele, hematocele, testicular fracture, or testicular rupture. In very small child patients, this information can only be obtained from a parent. The physician must also ask any new systemic symptoms or diseases already known to be

present.[1,2,8] After complete clinical examination of each patient, sonography was performed. Color Doppler and FNAC were also performed whenever required for confirming the diagnosis. Scrotal abnormalities can be divided into three groups, which are extra-testicular lesion, intra-testicular lesion and trauma. Causes of scrotal pain include inflammation (epididymitis, epididymo-orchitis, abscess), testicular torsion, testicular trauma, and testicular cancer [9,10,11]. Total 46.15% cases were diagnosed to be suffering from epididymitis, out of them chronic epididymitis was diagnosed in 30.77% cases whereas acute epididymitis was diagnosed in 15.38% cases. Thus the epididymis was found to be involved in the maximum number of cases and similar findings were also observed by Rholl *et al*[7] and Mukherjee, *et al*[12]. Patients with acute epididymitis presented with fever, swelling and acute pain in scrotum whereas patients with chronic epididymitis presented with mild pain and swelling. On clinical evaluation 13 cases (25%) were diagnosed of hydrocele. Out of which two cases were confirmed to be of hematocele and one of pyocele on FNAC. Thus in the present study hydrocele was diagnosed in 19.23% cases. Similar findings were also observed by Mukherjee, *et al*.[12] Majority of the hydrocele cases were children and presented with painless scrotal swelling. According to Martin LC *et al*[13] virtually all hydroceles are congenital in neonates and infants and associated with a patent processus vaginalis, which allows peritoneal fluid to enter the scrotal sac.

CONCLUSION

Thus we conclude that majority of scrotal lesions were extra testicular origin. Epididymitis was the common extra testicular origin, out of which acute Epididymitis presents with fever, swelling, and acute pain whereas chronic epididymitis present with swelling and mild pain.

REFERENCES

1. McAndrew HF, Pemberton R, Kikiros CS, Gollow I: The incidence and investigation of acute scrotal problems in children. Pediatr Surg Int 2002, 18:435-437.
2. Nelson CP, Williams JF, Bloom DA: The cremasteric reflex: a useful but imperfect sign in testicular torsion. J Pediatr Surg 2003, 38:1248-1293.
3. Günther P, Rübben I: The acute scrotum in childhood and adolescence. Dtsch Arztebl Int 2012, 109(25):449-57 quiz 458. doi: 10.3238/ arztebl.2012.0449. Epub 2012 Jun 22.
4. Thinyu S, Muttarak M: Role of ultrasonography in diagnosis of scrotal disorders: a review of 110 cases. Biomed Imaging Interv J 2009, 5(1):e2. doi: 10.2349/biij.5.1.e2.
5. Dogra VS, Gottlieb RH, Oka M, *et al*: Sonography of the scrotum. Radiology 2003, 227(1):18-36.
6. Micallef M, Torreggiani WC, Hurley M, Dinsmore WW, Hogan B. The ultrasound investigation of scrotal swelling. Int J STD AIDS 2000 May;11(5):297-302.
7. Rholl KS, Lee JK, Ling D, Heiken JP, Glazer HS. MR imaging of the scrotum with a high‐resolution surface coil. Radiology 1987; 163:99‐103.
8. Hormann M, Balassy C, Philipp MO, Pumberger W: Imaging of the acute scrotum in children. Eur Radiol 2004, 14:974-983.
9. Mevorach RA: Scrotal trauma., WebMD Website.http://www.emedicine. com/med/topic2857.htm. Published April 15, 2002.
10. Deurdulian C, Mittelstaedt CA, Chong WK, Fielding JR: US of acute scrotal trauma: optimal technique, imaging findings, and management. Radiographics 2007, 27(2):357-369.
11. Dogra V, Bhatt S: Acute painful scrotum. Radiol Clin North Am 2004, 42(2):349-63.
12. Mukherjee S, Maheshwari V, Khan R, Rizvi SA, Alam K, Harris SH, *et al*. Clinico-radiological and pathological evaluation of extra testicular scrotal lesions. J Cytol 2013; 30:27-32.
13. Martin LC, Share JC, Peters C, Atala A: Hydrocele of the spermatic cord: embryology and ultrasonographic appearance. Pediatr Radiol 1996, 26:528-530.

Source of Support: None Declared
Conflict of Interest: None Declared