

A rare case of kimura's disease presenting as posterior auricular swelling

S Deivanayagam¹, Vinod Balaji^{2*}, Jawahar³, Yeshwanth Kumar⁴

^{1,3}Professor, ^{2,4}Resident, Department of Surgery, Saveetha Medical College, Thandalam, Chennai, Tamil Nadu, INDIA.

Email: drdeiva@yahoo.com, drvinodbalaji@yahoo.com, drkjawahar@gmail.com, yeshwanthprofo@gmail.com

Abstract

Kimura's Disease is a chronic inflammatory disorder of unknown etiology commonly seen among people who live in the Middle and Far East countries; characterised lymphatic follicles, vascular proliferation, and marked eosinophilic infiltration by histologically. It is mainly seen on the head and neck region. The lesion is benign but might be confused with malignant lesions. Kimura's Disease is often seen in the second and third decades of life. This disease is characterised by a blood and tissue eosinophilia, markedly elevated serum IgE levels, painless subcutaneous mass and regional lymphadenopathy on the head and neck region. In this report, we present a 14 yr old boy who was admitted to our hospital with bilateral post auricular swelling for 4 yr duration. Bilateral postauricular masses were excised under general anaesthesia and Kimura's disease was diagnosed by histopathological examination of these lesions.

Keywords: kimura's disease, swelling.

*Address for Correspondence:

Dr. Vinod Balaji, No: 3, 52nd Street, 7th Avenue, Ashoknagar- 600083, Chennai, Tamil Nadu, INDIA.

Email: drvinodbalaji@yahoo.com

Received Date: 16/07/2015 Revised Date: 25/07/2015 Accepted Date: 28/07/2015

Access this article online	
Quick Response Code:	Website: www.statperson.com
	DOI: 01 August 2015

disease presenting as bilateral posterior auricular swelling in young boy.

CASE REPORT

A 14 yr old boy presenting to our hospital with asymptomatic swelling behind both ear lobe of 4 yr duration. Swelling progressively increasing in size to attain present size. No H/o any sudden increase in size of swelling. Clinical examination revealed 3x2 cm painless subcutaneous mass in right posterior auricular region with no puncture or bony indentation. Similarly, 2x1 cm subcutaneous mass in left posterior auricular region (fig: 1). There was no enlargement of regional lymph nodes or salivary glands. Laboratory findings were within normal limits. A differential diagnosis of dermoid cyst, lipoma and pyogenic granuloma was given. Excisional biopsies (fig: 2) of the bilateral posterior auricular masses were performed and specimens were sent for histopathological examination (fig: 3). HPE revealed multiple lymphoid follicles with distinct germinal centre which clinched the diagnosis of kimura's disease (fig: 4). Post op was uneventful and the patient is under regular follow-up.

INTRODUCTION

Kimura disease typically presents as a painless mass or masses in the head and neck region, with occasional pruritus of the overlying skin. Renal disease, nephrotic syndrome in particular, is present in up to 20% of patients with Kimura disease. Less commonly, several reports in the literature have linked Kimura disease with a hypercoagulable state in patients without associated nephrotic syndrome. Herein we report a case of kimura's

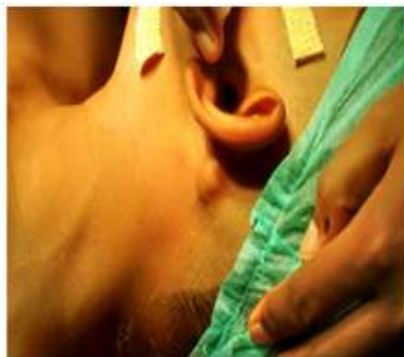

Figure 1: Pre-op pic of left posterior auricular mass

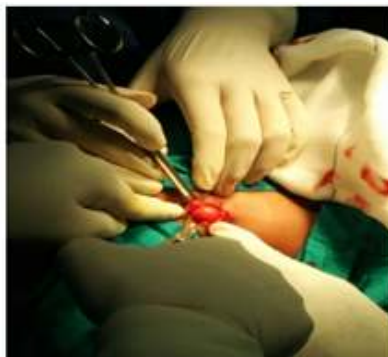

Figure 2: Intrap excision of the posterior auricular swelling

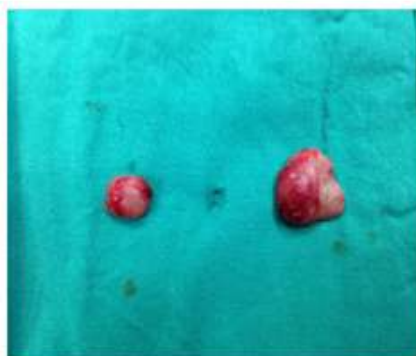

Figure 3: Post op pic of excised posterior auricular masses

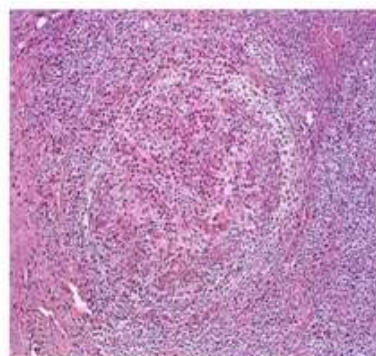


Figure 4: Histopathological pic of Kimuras disease

DISCUSSION

Kimura's disease is now recognised as a benign cause of painless localised lymphadenopathy of Asians, especially boys of Chinese and Japanese origin. Although the disease can become apparent at any age, most cases have been reported in the second and third decades of life. The clinical triad of subcutaneous nodules found in the head or neck, prominent peripheral eosinophilia, and highly increased IgE concentrations, particularly when seen in a young boy, is highly suggestive of Kimura's disease. Pathologically, nodular lesions usually affect the lymph nodes, though occasionally skin or salivary tissues are affected. Normal tissue architecture is usually preserved, but follicular hypertrophy of lymphatic tissue with infiltration of lymphocytes, histiocytes, and large numbers of eosinophils is typical. Germinal centres may be necrotic, with central eosinophilic abscesses. The pathophysiology of Kimura's disease is not understood at this time, but may relate to a disturbance in the normal rate of production of eosinophils and IgE, currently believed to be a product of an interaction between types 1 and 2 (Th1 and Th2) T helper cells. Such a derangement could result in excessive elaboration of eosinophilotropic cytokines such as interleukin 4. Patients with Kimura's disease have been shown to have

high levels of circulating eosinophilic cationic protein and major basic protein, with heavy concentrations of IgE in their tissues. Allergic or parasitic aetiologies for Kimura's disease have been actively sought, but not identified. The clinical course of Kimura's disease is benign. The subcutaneous masses are usually found in the head and neck region, sometimes affecting the parotid or minor salivary glands. Infrequently, axillary, inguinal, or epitrochlear nodes may be affected. Untreated, these masses tend to slowly enlarge and may eventually become disfiguring, as in our patient. Long term, patients seem to do well, although about 10% may develop a steroid responsive nephrotic syndrome. Three major therapeutic options exist for Kimura's disease. Resection of the tumour mass may be effective in permanently eradicating the mass if the entire lesion can be removed, but regrowth is common. Local irradiation has also been shown to be effective in shrinking lesions, but is generally not advocated in younger patients. Finally, systemic and intralesional corticosteroids have been shown to reduce the size of the lesion, but the tumour tends to recur when these drugs are discontinued. In selected patients it may be advisable to take a conservative approach, treating only if the mass continues to grow or causes significant deformity. The differential

diagnosis for Kimura's disease includes such entities as eosinophilic granuloma, Mikulicz's disease, acute non-lymphocytic leukaemia, Hodgkin's disease, follicular lymphoma, angioimmunoblastic lymphadenopathy, and angiolymphoid hyperplasia with eosinophilia. Except for angiolymphoid hyperplasia with eosinophilia, the clinical and histological features of these diseases easily distinguishes them from Kimura's disease. Angiolymphoid hyperplasia with eosinophilia is a chronic benign disorder associated with cutaneous nodules heavily infiltrated with eosinophils. It is found in older, mostly female patients, however, and lesions tend to be small and intracutaneous, rather than subcutaneous as in Kimura's disease. IgE concentrations are usually not increased in angiolymphoid hyperplasia with eosinophilia and there is often no peripheral eosinophilia. Paediatricians and surgeons need to be aware of Kimura's disease, especially in view of the growing number of susceptible children present in Western countries. Recognition of this disorder may allow doctors to limit the number of laboratory tests ordered and reduce concern about the possibility of malignant disease. Kimura's disease needs to be strongly considered in any patient, especially an Asian boy, who presents with a painless head or neck mass in association with marked eosinophilia and hyperimmunoglobulinaemia E.

CONCLUSION

Kimura's disease of bilateral posterior auricular subcutaneous tissue is rare. It is a chronic inflammatory disorder that can be confused with malignant tumour. Therapeutic surgical excision, radiation therapy, steroids can be used for management. Spontaneous recovery is rare and prognosis is good.

REFERENCE

1. Kimm HT, Szeto C. Eosinophilic hyperplastic lymphogranuloma, comparison with Mikulicz's disease. *Proc Chin Med Soc.* 1937. 329.
2. Kimura T, Yoshimura S, Ishikawa E. On the unusual granulation combined with hyperplastic changes of lymphatic tissues. *Trans Soc Pathol Jpn.* 1948. 37:179-80.
3. Ramchandani PL, Sabesan T, Hussein K. Angiolymphoid hyperplasia with eosinophilia masquerading as Kimura disease. *Br J Oral Maxillofac Surg.* 2005 Jun. 43(3):249-52.
4. Ohta N, Fukase S, Suzuki Y, Ito T, Yoshitake H, Aoyagi M. Increase of Th2 and Tc1 cells in patients with Kimura's disease. *Auris Nasus Larynx.* 2011 Feb. 38(1):77-82
5. Katagiri K, Itami S, Hatano Y, Yamaguchi T, Takayasu S. In vivo expression of IL-4, IL-5, IL-13 and IFN-gamma mRNAs in peripheral blood mononuclear cells and effect of cyclosporin A in a patient with Kimura's disease. *Br J Dermatol.* 1997 Dec. 137(6):972-7.
6. Hosoki K, Hirayama M, Kephart GM, *et al.* Elevated numbers of cells producing interleukin-5 and interleukin-10 in a boy with Kimura disease. *Int Arch Allergy Immunol.* 2012. 158 Suppl 1:70-4.
7. Sun QF, Xu DZ, Pan SH, *et al.* Kimura disease: review of the literature. *Intern Med J.* 2008 Aug. 38(8):668-72.
8. Kung IT, Gibson JB, Bannatyne PM. Kimura's disease: a clinico-pathological study of 21 cases and its distinction from angiolymphoid hyperplasia with eosinophilia. *Pathology.* 1984 Jan. 16(1):39-44.
9. Wang DY, Mao JH, Zhang Y, *et al.* Kimura disease: a case report and review of the Chinese literature. *Nephron Clin Pract.* 2009. 111(1):c55-61.
10. Thomas J, Jayachandran NV, Chandrasekhara PK, Rajasekhar L, Narsimulu G. Kimura's disease--an unusual cause of lymphadenopathy in children. *Clin Rheumatol.* 2008 May. 27(5):675-7.
11. Chen H, Thompson LD, Aguilera NS, Abbondanzo SL. Kimura disease: a clinicopathologic study of 21 cases. *Am J Surg Pathol.* 2004 Apr. 28(4):505-13. [Medline].
12. Rajpoot DK, Pahl M, Clark J. Nephrotic syndrome associated with Kimura disease. *Pediatr Nephrol.* 2000 Jun. 14(6):486-8. [Medline].
13. Jennifer Lee and Yeon-Sik Hong. Kimura Disease complicated with bowel infarction and multiple arterial thromboses in the extremities. *J Clin Rheumatol.* Jan 2014. 20:38-41.
14. Yoganathan P, Meyer DR, Farber MG. Bilateral lacrimal gland involvement with Kimura disease in an African American male. *Arch Ophthalmol.* 2004 Jun. 122(6):917-9.
15. Park SW, Kim HJ, Sung KJ, Lee JH, Park IS. Kimura disease: CT and MR imaging findings. *AJNR Am J Neuroradiol.* 2012 Apr. 33(4):784-8.
16. Bonfils P, Moya-Plana A, Badoual C, Nadéri S, Malinvaud D, Laccourreye O. Intraparotid Kimura disease. *Eur Ann Otorhinolaryngol Head Neck Dis.* 2013 Apr. 130(2):87-9.
17. Yadla M, Sriramnaveen P, Sivakumar V, Sandeep Reddy Y, Sridhar AV, Krishna Kishore C. Epitrochlear mass in a patient on maintenance hemodialysis-Kimura disease. *Hemodial Int.* 2012 Jan 26.
18. Li D, Li YJ, Zhan FH, Dang CJ. The false-positive finding of left pulmonary Kimura disease on 18F-FDG PET/CT. *Clin Nucl Med.* 2013 Jul. 38(7):569-72.
19. Sakamoto M, Komura A, Nishimura S. Hematoserological analysis of Kimura's disease for optimal treatment. *Otolaryngol Head Neck Surg.* 2005 Jan. 132(1):159-60.
20. Ohta N, Okazaki S, Fukase S, Akatsuka N, Aoyagi M, Yamakawa M. Serum concentrations of eosinophil cationic protein and eosinophils of patients with Kimura's disease. *Allergol Int.* 2007 Mar. 56(1):45-9.

Source of Support: None Declared
Conflict of Interest: None Declared