

# A cadaveric study of variations in branching pattern of brachial plexus

Smita K Balsurkar<sup>1\*</sup>, Surwase Ramdas G<sup>2</sup>, Ferozkhan J Pathan<sup>3</sup>, Ugale Mahesh<sup>4</sup>, Reddy Anand<sup>5</sup>

<sup>1,5</sup>Assistant Professor, <sup>2,3</sup>Associate Professor, <sup>4</sup>Professor, Department of Anatomy, MIMSR Medical College, Latur, Maharashtra, INDIA.

Email: [drsmitasantosh@gmail.com](mailto:drsmitasantosh@gmail.com), [r.surwase@yahoo.in](mailto:r.surwase@yahoo.in), [drferoz07@rediffmail.com](mailto:drferoz07@rediffmail.com), [dmsu1974@yahoo.com](mailto:dmsu1974@yahoo.com)

## Abstract

**Aims and Objectives:** The aims of present study are 1) to study the variations in branching pattern of the brachial plexus 2) to study the communication of median nerve with other nerves of upper limb. **Materials and Methods:** In present study 30 brachial plexuses from 15 well embalmed human cadavers were studied in anatomy department. In depth study was done on the communications of median with the musculocutaneous nerve and the different types were classified. Communication between ulnar nerve and median nerve was studied. **Results:** Out of 30 upper limbs, we found communication between musculocutaneous nerve and median nerve in 6 cases. In such cases, the communicating branch run from musculocutaneous nerve towards median nerve. Four upper limb shows communication between ulnar nerve and medial root of median nerve. **Conclusion:** It is concluded that knowledge of such variations is essential in evaluation of unexplained sensory and motor loss after trauma and surgical interventions to upper limb. Knowledge of these variations is important to anatomists, radiologists, anesthesiologists and surgeons.

**Keywords:** Brachial plexus, Communications, Median nerve, Musculocutaneous nerve, Ulnar nerve, Upper limb Variations.

## \*Address for Correspondence:

Dr. Smita K. Balsurkar, Assistant Professor, Department of Anatomy, MIMSR Medical College, Latur, Maharashtra, INDIA.

Email: [drsmitasantosh@gmail.com](mailto:drsmitasantosh@gmail.com)

Received Date: 14/07/2015 Revised Date: 28/07/2015 Accepted Date: 04/08/2015

## Access this article online

Quick Response Code:



Website:

[www.statperson.com](http://www.statperson.com)

DOI: 06 August 2015

## INTRODUCTION

The brachial plexus supplies the upper limb, and is formed by the ventral primary rami of C5-T1. It consists of roots, trunks, divisions and cords. The ventral rami of C5 and C6 unite to form the superior trunk, C7 becomes the middle trunk, and C8 and T1 form the inferior trunk. These three trunks just above or behind the clavicle bifurcate into anterior and posterior divisions. The anterior divisions supply the flexor compartment of upper limb and the posterior divisions supply the extensor compartment of upper limb. All of the posterior divisions form the posterior cord. The lateral cord is formed by the union of the anterior divisions of the superior and middle trunk. The medial cord is formed as a continuation of the

anterior division of the inferior trunk. The peripheral nerves arise from these cords. The lateral root of median nerve and musculocutaneous nerve arise from lateral cord while medial root of median nerve and ulnar nerve takes origin from medial cord of brachial plexus. Lateral root and medial root of median nerve join to form trunk of median nerve [Figure-1]. The median nerve is susceptible to variations and communications between the nerve and its adjacent nerves are common, those between the median nerve and musculocutaneous nerve have been described from nineteenth century<sup>1</sup>. Many authors have studied the communication between the two nerves thoroughly. Although the anastomosis between ulnar nerve and median nerve in the arm are rare, but reported by many authors. Such anastomoses have been also reported in the upper part of the forearm, rarely in the distal forearm<sup>2</sup>. Since the brachial plexus is a complex structure, variations in formation of roots, trunks, divisions and cords are common. The brachial plexus innervates skin and muscles of the upper limb and any injury at this level can lead to significant disability<sup>3</sup>. Knowledge of variations in anatomy is important to anatomists, radiologists, anesthesiologists and surgeons, and has gained more importance due to the wide use of computer imaging in diagnostic medicine. The knowledge of such communications is significant to interpret any

abnormal functioning of these nerves due to communications, and to avoid injury to the communicating branch while performing surgeries pertaining to shoulder and anterior compartment of arm<sup>4</sup>.

The present study deals with some of the common variations and some hitherto unknown variations of the brachial plexus.

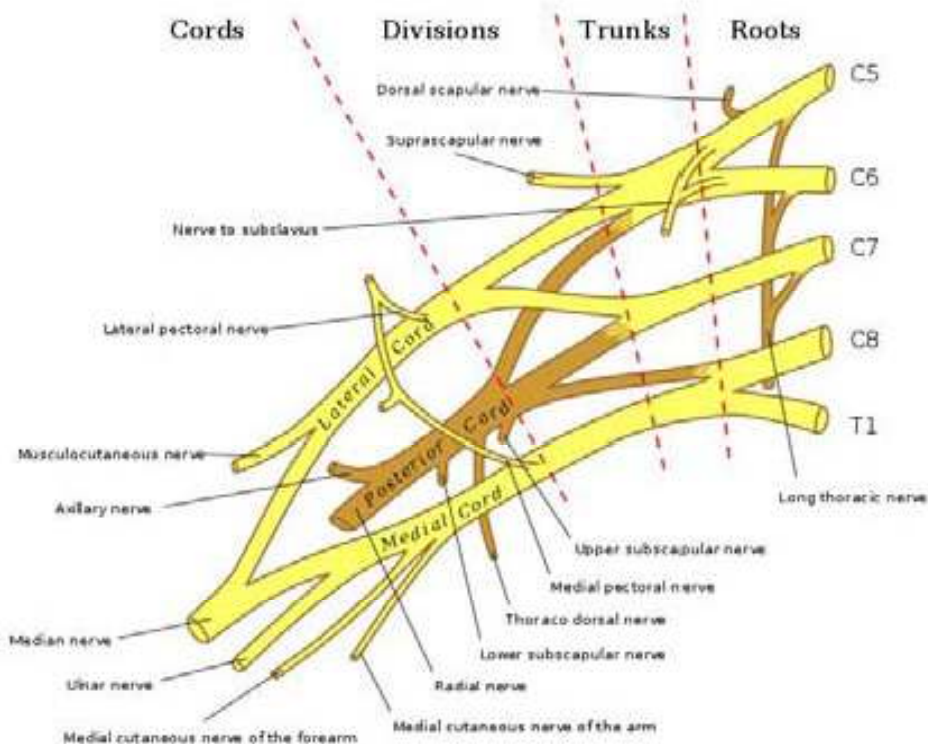


Figure 1: Showing Formation of Brachial plexus

**AIMS and OBJECTIVES**

Communication between the nerves of brachial plexus is commonly reported and this prompted us to conduct the study.

Aims and objectives of present study are:

1. To study the variations in branching pattern of the brachial plexus.
2. To study the communication of median nerve with other nerves of upper limb.
3. To study the significance of variations in branching pattern of brachial plexus.

**MATERIALS AND METHODS**

This study was conducted on 15 well embalmed human cadavers (30 upper limb specimens) from the dissection laboratory with an age range of 50 – 80 years. The cadavers were embalmed through femoral arterial perfusion of 4% formaldehyde solution and preserved in weak formalin solution for more than one year before dissection. The dissection was performed in dissection laboratories of Maharashtra institute of Medical science and research Medical College, Latur from August 2012 to

August 2014. Dissection was done according to Cunningham's Manual of practical Anatomy. The dissection of brachial plexus was done carefully and variation to normal usual pattern was noted, sketched and photographed.

**OBSERVATIONS AND RESULTS**

In present study, out of 30, there were communications between musculocutaneous nerve (MCN) and median nerve (MN) in six upper limbs [Table-1]. Aberrations were more on left side (4 cases) than right side (2 cases). In those cases anastamotic branch was observed running from the musculocutaneous nerve (MCN) towards the median nerve (MN), before piercing the caracobrachialis muscle [Figure-2].

Table 1: Communications between MCN and MN:

| Side of limb          | No. of cases | Percentage (%) |
|-----------------------|--------------|----------------|
| Right (R)             | 2            | 13.33          |
| Left (L)              | 4            | 26.66          |
| <b>Total (R+L=30)</b> | <b>6</b>     | <b>20</b>      |

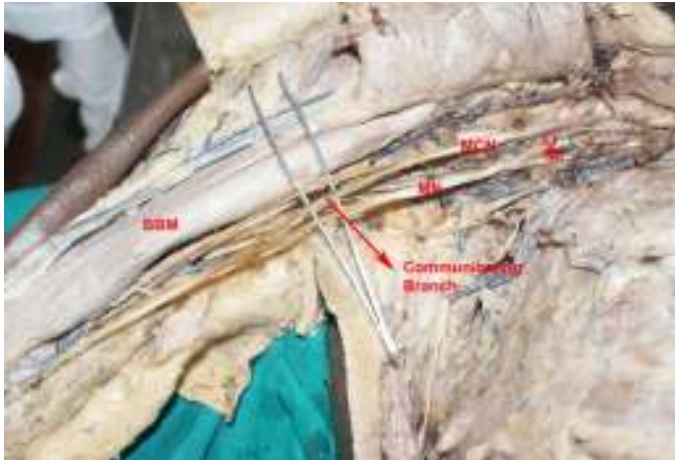


Figure 2: Communication between Musculocutaneous and Median Nerve

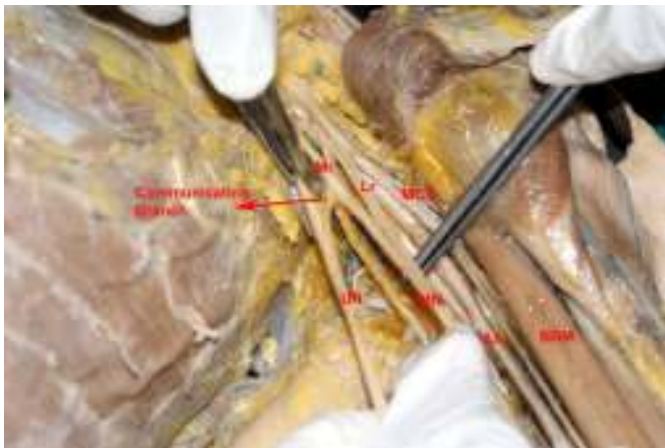

Figure 3: Communication between Ulnar and Median Nerve

In present study, there were communications between ulnar nerve (UN) and median nerve (MN) in 4 cases [Table-2]. Communicating branch was present in between the medial root of median nerve (MN) and ulnar nerve (UN). This communicating branch arose from the medial root of median nerve (MN) distal to its origin and run medially and slightly downwards to join the ulnar nerve (UN) distal to its origin [Figure-3].

**Table 2: Communication between UN and MN**

| Side of limb           | No. of cases | Percentage (%) |
|------------------------|--------------|----------------|
| Right (R)              | 2            | 13.33          |
| Left (L)               | 2            | 13.33          |
| <b>Total (R+L= 30)</b> | <b>4</b>     | <b>13.33</b>   |

## DISCUSSION

Variations in the formation and branching pattern of brachial plexus have been documented well by many authors. Accurate knowledge of these variations other than that quoted in classical text books is important for both medical and surgical aspects.

## Communications between median and musculocutaneous nerves

Communications between median and musculocutaneous nerves are very common, though not seen in all cases. Eglseder and Goldman,<sup>5</sup> noticed interconnections between the musculocutaneous nerve and median nerve in 36% of dissections. Venieratos *et al*,<sup>6</sup> found communications between the musculocutaneous and median nerves in 16 out of 79 cadavers. Connections between the musculocutaneous nerve and median nerve are well documented by Choi *et al* (24.6%),<sup>4</sup> and Loukas and Aqueelah (63.5%),<sup>7</sup>. Yoganandham Janani *et al*,<sup>8</sup> reported communication between median and musculocutaneous nerve proximal to the entry of musculocutaneous nerve into coracobrachialis muscle in 6.66 % cases. Venieratos *et al*,<sup>6</sup> found that musculocutaneous and median nerve communication is the most frequent of all the variations that could be observed in the brachial plexus. Anastomotic branch arising from the median nerve running distally to join with the branches of the musculocutaneous nerve was found by Saeed and Rufai,<sup>9</sup>. Such communications between median nerve and musculocutaneous nerve have been classified by many authors. These variations are Types I-V reported by Le Minor,<sup>10</sup>. In **Type I**, there are no connecting fibers between the musculocutaneous and median nerve as described in classic textbooks. In **Type II**, Although some fibers of the medial root of the median nerve unite with the lateral root of the median nerve and form the main trunk of median nerve, remaining medial root fibers run in the musculocutaneous nerve leaving it after a distance to join the main trunk of median nerve. In **Type III**, The lateral root of the median nerve from the lateral cord runs in the musculocutaneous nerve and leaves it after a distance to join the main trunk of median nerve. In **Type IV**, The fibers of the musculocutaneous nerve unite with the lateral root of the median nerve. After some distance, the musculocutaneous nerve arises from the median nerve. In **Type V**, The musculocutaneous nerve is absent. The fibers of the musculocutaneous nerve run within the median nerve along its course. In this type the musculocutaneous nerve does not pierce the coracobrachialis muscle. Venieratos and Anagnostopoulou,<sup>6</sup> also reported three types of communications between median and musculocutaneous nerves considering the coracobrachialis muscle as the reference point. According to their classification, there are three types of such communications. **Type 1:** Communication proximal to the entry of musculocutaneous nerve into coracobrachialis muscle. **Type 2:** Communication distal to the exit of musculocutaneous nerve from coracobrachialis muscle. **Type 3:** Musculocutaneous nerve did not pierce



coracobrachialis directly or through its branches but ran alongside the muscle and exhibited a communication between it and the median nerve. Beheiry,<sup>11</sup> added **Type 4** to the above classification. According to him, the communicating branch along with musculocutaneous nerve pierced the coracobrachialis muscle following which the communicating branch joined the median nerve. In present study, we found 6 cases (20%) of communication between median nerve and musculocutaneous nerve proximal to the entry of musculocutaneous nerve into coracobrachialis muscle. This correlates with the study of Yoganandham Janani *et al*,<sup>8</sup> and Choi *et al* (24.6%),<sup>4</sup>. This can be classified into type 1 according to Venieratos and Anagnostopoulou<sup>6</sup>.

#### Communications between median and ulnar nerves

In present study, we found communicating branch was present in between the medial root of median and ulnar nerve in 4 cases (13.33%). Further course of ulnar nerve is normal. Gupta M *et al*,<sup>12</sup> also reported a case showing communication between medial root of median nerve and ulnar nerve. The medial root of median nerve gave a communicating twig to the ulnar nerve which could be the fibers that medial root of median nerve received from the lateral root as described by Hollinshead<sup>13</sup>. He stated that ulnar nerve usually receives fibers from seventh cervical nerve by receiving a contribution from the lateral cord. Konstantin J. Kazakos *et al*,<sup>14</sup> and other many authors reported the communication between median and ulnar nerve in forearm and hand. There are many signaling molecules and transcription factors which are involved in the formation and division of nerves. Any abnormal expression of the genes or abnormal formation and separation of nerve trunks can result in improper branching of nerves. It is significant for the anatomists as well as surgeons and radiologists to have knowledge about such anatomical variations in order to avoid any damage to the peripheral nerves. Based on the fact that ontogeny repeats phylogeny, this communication can possibly be related to the single nerve trunk which represents the median nerve in the thoracic limb of lower vertebrates<sup>15</sup>.

#### CONCLUSION

Present study concluded that the median nerve is highly susceptible to variations. The knowledge of above mentioned variations can be of significance for physicians and surgeons apart from anatomists while examining a case of median nerve lesion proximal to a communication between the median nerve and musculocutaneous nerve as the functions of the median nerve can still be restored due to the fibers travelling via the communicating branch through musculocutaneous nerve. Thus precise knowledge of variations in musculocutaneous nerve and

median nerve may prove valuable in traumatology of the arm, as well as in plastic and reconstructive repair operations. The communication between median and ulnar nerve can also be of significant use to neurologists and orthopedic surgeons while examining cases with sensory loss over the distal part of the upper limb. So, knowledge of these variations is of clinical significance in anesthetic blocks, surgical approaches during internal fixation of humeral fracture from common anterior approach to avoid injury to these nerves and nerve entrapment syndromes involving different branches of brachial plexus.

#### LIST OF ABBREVIATIONS

1. C5-C8: Fifth to eighth cervical spinal nerves.
2. T1: First thoracic spinal nerve.
3. MCN: Musculocutaneous Nerve.
4. MN: Median Nerve.
5. Lr: Lateral root of Median Nerve.
6. Mr: Medial root of Median Nerve.
7. UN: Ulnar Nerve.
8. AA: Axillary Artery.
9. BBM: Bicep Brachii Muscle.

#### ACKNOWLEDGEMENTS

We are thankful to Dr. M. S. Ugale, Professor and Head of Dept. of Anatomy, MIMSR Medical college, Latur for giving permission to do the work and also thankful to other faculty members of this department for their co-operation. We are thankful to First year M.B.B.S students for their co-operation.

#### REFERENCE

1. Harris W. (1904): The True Form of the Brachial Plexus. *Journal of Anatomy and Physiology* 1904; 38 (4): 399-422.
2. Streib EW. (1979): Ulnar-To-Median Nerve Anastomosis In The Forearm: Electromyographic Studies. *Neurology* 1979; 29: 1534-1537.
3. Kerr AT (1918): The Brachial Plexus of Nerve in Man the Variation in Its Formation and Branches. *American Journal of Anatomy* 1918; 23: 285 – 295.
4. Choi D, Rodriguez-Niedenfuhr M, Vazquez T, Parkin I, Sanudo JR. (2002): Patterns of Connections between the Musculocutaneous and Median Nerves in the Axilla and Arm. *Clinical Anatomy*; 2002; 15:11–17.
5. Eglseder WA Jr, Goldman M. (1997): Anatomic Variations of the Musculocutaneous Nerve In The Arm. *American Journal Orthopedics* 1997; 26 (11):777-80.
6. Venieratos D, Anagnostopoulou S. (1998): Classification of Communications between the Musculocutaneous and Median Nerves. *Clinical Anatomy* 1998; 11 (5): 327-331.
7. Loukas M, Aqueelah H. (2005): Musculocutaneous and Median Nerve Connections Within, Proximal and Distal To the Coracobrachialis Muscle. *Folia Morphologica* 2005; 64: 101-108.

8. Yoganandham Janani, Hannah Sugirthabai Rajila Rajendran, Thotakura Balaji, Rajendran Sharmila Saran, Batmanabane Mounissamy (2014) : A Study On The Communications Of Median Nerve With Musculocutaneous And Ulnar Nerves. International Journal of Research in Health Science 2014; 2 (2):480-487.
9. Saeed M, Rufai, A. (2003) : Anastomotic Branch From The Median Nerve To The Musculocutaneous Nerve: a case report. Clinical Anatomy 2003; 16: 453-457.
10. Le Minor, J.M. (1990): A Rare Variant of the Median and Musculocutaneous Nerve in Man. Archives Anatomy Histology Embryology 1990; 73: 33 – 42.
11. Beheiry EE (2004): Anatomical Variations Of The Median Nerve Distribution And Communication In Arm. Folia Morphologica 2004; 63(3): 313-318.
12. Gupta M, Goyal N, Harjeet (2005): Anomalous Communications in the Branches of Brachial Plexus. Journal of the Anatomical Society of India 2005; 54 (1): 1-3.
13. Hollinshead, W. H. (1979): Textbook of Anatomy In: upper limb. 3<sup>rd</sup> edition. Oxford and IBH publishing co. Calcutta, India, p. 225:245.
14. Konstantin J. KAZAKOS, Anastasios SMYRNIS, Konstantin C. XARCHAS, Alexandra DIMITRAKOPOULOU, Dionysios-Alexandros VERETTAS (2005): Anastomosis Between The Median And Ulnar Nerve In The Forearm, An Anatomic Study And Literature Review. Acta Orthopædica Belgica, 2005; 71:29-35.
15. Chauhan R, Roy TS (2002): Communication between the Median and Musculocutaneous Nerve- A Case Report. Journal of Anatomical Society of India: 2002; 51(1): 72-75.

Source of Support: None Declared  
Conflict of Interest: None Declared