

Eumycotic mycetoma of metatarsals presenting with bone cyst

Rashmi K Patil^{1*}, Milind M Kesarkhane², S K Kittur³, Arunkumar G⁴

{¹Associate Professor, ²PG Student, ³Professor and HOD, Department of Pathology} {⁴Sr. Resident, Department of Orthopaedics}
Belagavi Institute of Medical Sciences, Belagavi-590001, Karnataka, INDIA.

Email: rashminimbal@rediffmail.com, milinds8308@gmail.com

Abstract

Mycetoma or 'Madhura foot' is a chronic infection of skin and subcutaneous tissue, fascia and bone. It is caused by true fungi (eumycetoma) or by filamentous bacteria (actinomycetoma). Since the treatment of these two etiologies is entirely different, a definite diagnosis after histopathological and microbiological examination is mandatory. We hereby present a rare case of eumycotic mycetoma involving right metatarsals with bone cyst formation.

Keywords: eumycetoma, *madurella mycetomatis*, metatarsal, cyst.

*Address for Correspondence:

Dr Rashmi K Patil, Associate Professor, Department of Pathology, Belagavi Institute of medical sciences, Belagavi-590001, Karnataka.

Email: rashminimbal@rediffmail.com

Received Date: 03/08/2015 Revised Date: 11/08/2015 Accepted Date: 13/08/2015

Access this article online

Quick Response Code:



Website:

www.statperson.com

DOI: 16 August 2015

INTRODUCTION

Mycetoma is a chronically discharging suppurative disease of skin, subcutaneous tissue and bone that is present worldwide and is endemic in tropical and subtropical region.¹ It may be caused by true fungi (eumycetoma) in 40% cases and by filamentous bacteria (actinomycetoma) in 60% cases. Most common cause of eumycetoma is black coloured fungi *Madurella mycetomatis*² Differentiation between two etiologic agents is important with regard to disease progression and treatment.

CASE REPORT

A 50 years old farmer presented with swelling over right foot since 3 years and associated seropurulent discharge since 6 months. Lesion was preceded by thorn prick at the last interdigital cleft. Patient was treated elsewhere with amputation of 5th toe one year back for similar complaints and had no details of diagnosis. On examination, swelling

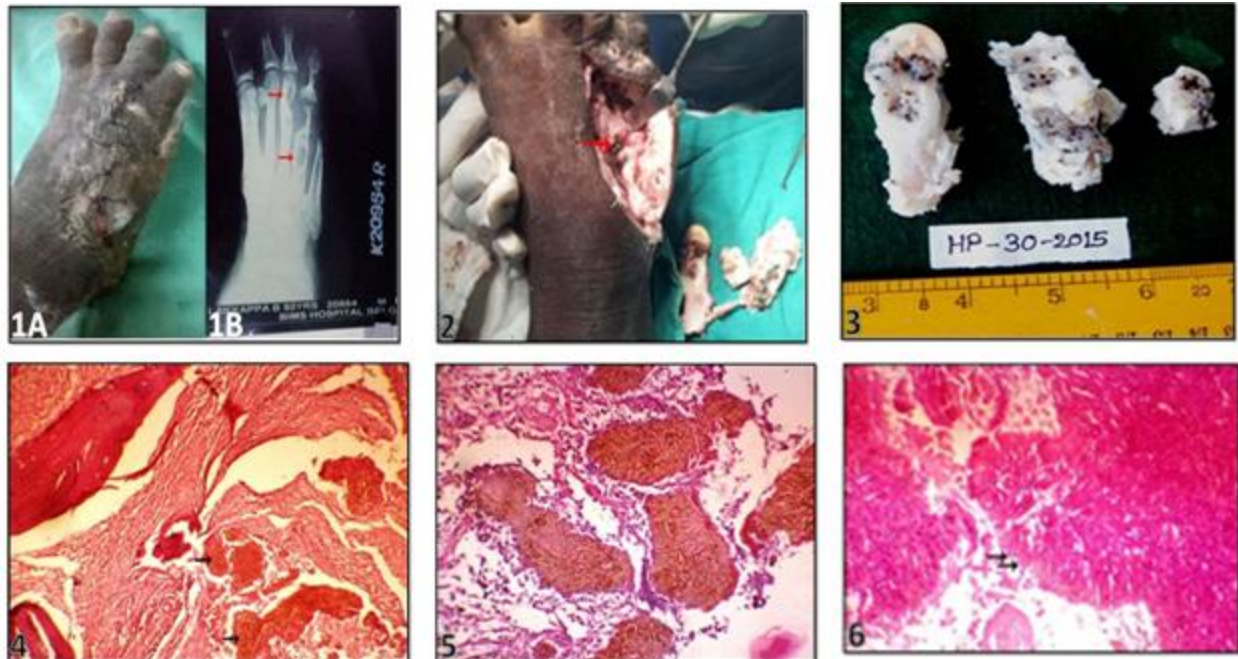
over dorsum of right foot with wound and multiple sinuses with discharging seropurulent fluid and black grains were seen ([Figure 1A](#)) Radiography showed osteolytic lesion in 3rd, 4th and 5th metatarsals with bone cyst formation ([Figure 2B](#)). General physical examination, blood and serum chemistry were unremarkable. No family history of tuberculosis. Skin biopsy from the lesion showed chronic non specific inflammation. Clinically diagnosis of chronic bacterial osteomyelitis was considered. 10% Potassium hydroxide (KOH) of grains showed mycelial clumps with hyphae. Gram stain and Ziehl-Neelsen stain showed no bacteria, this suggested eumycetoma. However skin biopsy from the lesion revealed chronic non specific inflammation. Amputation of 3rd, 4th and 5th metatarsals was done and submitted for histopathology.

Gross appearance

Three bony fragments with largest measuring 6x2x1 cm were seen. Cut surface of the bone showed multiple cyst filled with many black granules measuring 2 to 4 mm in diameter ([Figure 2 and Figure 3](#))

Microscopy

H and E stained sections showed cystic lesion the bone with many brown coloured colonies surrounded by mixed inflammatory cell infiltrate ([Figure 4 and 5](#)). Periodic acid Schiff stain (PAS) highlighted septate hyphae ([Figure 6](#)) favoring the morphological appearance of *Madurella mycetomatis*, however culture was negative. Post surgically patient was treated with flucanazole 150 mg twice a day. Patient was doing well after 5 months of follow up.



Legend

- Figure 1A:** Photograph of right foot with sinuses and wound
- Figure 1 B:** X-ray showing osteolytic changes and bone cyst (arrow)
- Figure 2:** Intraoperative photograph revealing many black granules within bone (arrow).
- Figure 3:** Photograph of amputated metatarsal bones showing cystic cavities filled with black granules and necrotic material.
- Figure 4:** Microphotograph of mycelial colonies (single arrow) seen within bone. (H and E 100x)
- Figure 5:** Microphotograph showing brown coloured colonies with intricate filaments in amorphous matrix (H and E 400x)
- Figure 6:** Microphotograph showing broad interlacing septate hyphae with rounded chlamydoconidia (arrow). (PAS 400x)

DISCUSSION

Mycetoma also known as ‘Maduramycosis’ or ‘Madura foot’ was described by John Gill in 1842 for the first time from south India². It is chronic localized infection caused by fungi (eumycotic agent) or actinomycetes residing as saprophytes in soil or plants, characterized by formation of aggregates of microcolonies of organisms within the abscess³. Penetrating injury forms important portal of entry for the organism as in our patient. The entity is frequently encountered in tropics and subtropics where habit of walking barefoot is common^{1,2,3}. Eumycotic mycetoma was more common in northern India; however recent trends show an increase in incidence of actinomycetoma.⁴ Foot is commonest site followed by upper extremity, perineum and scalp.⁵ Clinically diagnosis of mycetoma is based on the presence of sinus tracts discharging granules. *Madurella mycetomatis* is one of the most common causes of eumycetoma discharging characteristic black granules.^{2,3} Bone involvement is known to occur in eumycotic mycetoma with formation of cyst like cavities in bone and bone sclerosis mainly in the foot.⁶ Our patient had bone cyst and osteolytic lesion in the metatarsals. Diagnosis of eumycetoma is by

demonstrating septate hyphae of 2 to 6 μ m thick with amorphous matrix on HandE stain, highlighted by PAS stain. If the colonies are gram positive and shows filamentous bacteria less than 1 μ m thick, actinomycetes should be considered ruling out botromycosis which are gram positive cocci or bacilli.^{3,7} In our case, histology showed PAS positive septate hyphae with brown pigmented amorphous matrix and helped in narrowing the diagnosis of eumycotic agent possibly of *Madurella mycetomatis* inspite of no growth in culture. Culture of mycetoma usually is problematic due to stringent growth requirements, contaminated by other bacterial organisms and because patient usually presents late when the fibrosis predominates over the purulent discharge. Thus histology has a beneficial role and remains the only option in culture-negative cases.⁷ Actinomycosis is amenable to treatment by antibiotics. Prognostically, eumycetomas is only partially responsive to antifungal agent, has high rate of recurrence and surgical amputation may be the only effective treatment.⁸

CONCLUSION

Since mycetoma is relatively painless condition, it is often diagnosed at an advanced stage and has a high incidence of secondary bacterial infection causing disability as well as septicemia which may be fatal if untreated. This emphasizes the need for its correct diagnosis after meticulous clinical examination, assisted by histological and microbiological studies along with use of special stains.

REFERENCES

1. Davis JD, Stone PA, McGarry JJ. Recurrent mycetoma of the foot. *J Foot Ankle Surg.* 1999; 38:55–60. [\[PubMed\]](#)
2. Magana M, Mycetoma *Int J Dermatol.* 1984; 23:221–36. [\[PubMed\]](#)
3. Alam K, Maheshwari V, Bhargav S, Jain A, Fatima U, Haq EU (2009) Histological diagnosis of Madura foot

- (mycetoma): A must for definitive treatment. *J Glob Infect Dis* 1: 64-67. [\[PubMed\]](#)
4. Bakshi R, Mathur DR. Incidence and changing pattern of mycetoma in western Rajasthan. *Indian J Pathol Microbiol* 2008; 51:154-6. [\[PubMed\]](#)
 5. McGinnis MR. Mycetoma. *Dermatol Clin* 1996; 14:97-104. [\[Book\]](#)
 6. Prasad PVS, George RV, Paul EK, Ambujam S, Sethurajan S, Krishanasamy B, Rao LL (2002) Eumycetoma in the leg with a bone cyst in fibula. *Indian J Dermatol Venereol Leprol* 68: 174-175. [\[Researchgate\]](#)
 7. Chufal SS, Thapliyal NC, Gupta MK; An approach to histology based diagnosis and treatment of Madura foot. *J Infect Dev Ctries*, 2012; 6(9): 684-688. [\[PubMed\]](#)
 8. Welsh O, Salinas MC, Rodriguez MA. Treatment of eumycetoma and actinomycetoma. *Curr Trop Med Mycol* 1995; 6: 44-71. [\[Researchgate\]](#)

Source of Support: None Declared
Conflict of Interest: None Declared