

Bochdalek hernia in an adult

B Ananda Rama Rao^{1*}, N Rama Lakshmi², K Ashok Kumar Raju³, Datta Prasad⁴

¹Professor and Dean, ^{2,3,4}Jr. Resident, Department of General Surgery, SVS Medical College, Mahabubnagar-590002, Telangana, INDIA.

Email: anand1949@gmail.com, naduri_rama@yahoo.com, ashok.19987.doc@gmail.com

Abstract

Bochdalek hernia is a congenital anomaly in neonatal and postnatal patients and occurs in about one in 2,200 to 12,500 live births. Bochdalek hernias are congenital diaphragmatic defects resulting from the failure of fusion of posterolateral diaphragmatic foramina in utero which results in herniation of abdominal contents into thoracic cavity. It generally presents in neonatal to preschool age groups. Occurrence in adults is rare and usually asymptomatic. A rare case of a symptomatic Bochdalek hernia in an adult transverse colon as its content and with two perforations is reported.

Keywords: Bochdalek hernia, diaphragmatic defect, hernia.

*Address for Correspondence:

Dr. B Ananda Rama Rao, Professor and Dean, Department of General Surgery, SVS Medical College, Mahabubnagar-590002, Telangana, INDIA.

Email: anand1949@gmail.com

Received Date: 26/07/2015 Revised Date: 03/08/2015 Accepted Date: 14/08/2015

Access this article online

Quick Response Code:



Website:

www.statperson.com

DOI: 23 August 2015

is usually incidental and asymptomatic¹. Symptomatic Bochdalek hernia in adults are relatively rare and may lead to incarcerated bowel, intra abdominal organ dysfunction severe pulmonary disease². This is a case of Bochdalek hernia in adult which is symptomatic.

MATERIAL AND METHODS

A 36yr old male patient came to the casualty department with features of intestinal obstruction since two days for which conservative therapy relieved the symptoms. Suddenly patient developed chest pain and fever and he collapsed. Resuscitation was done. He again had symptoms of intestinal obstruction, bowel sounds were absent and rectum was empty rectal examination. Plain X ray abdomen showed multiple air fluid levels with bowel shadow in the chest. CT scan of chest and abdomen showed image as shown in figure^{1,2,3}.

INTRODUCTION

Congenital posterolateral diaphragmatic hernia, also referred to as Bochdalek's diaphragmatic hernia, is one of the most common congenital diaphragmatic hernias in infant and can result in severe respiratory distress, necessitating immediate surgery. This condition in adult

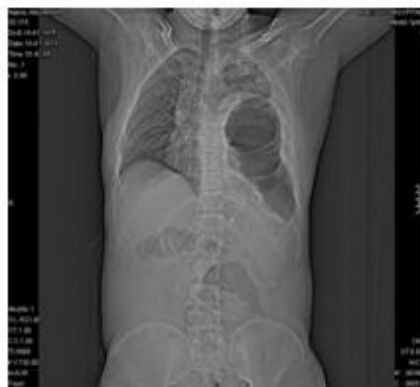

Figure 1

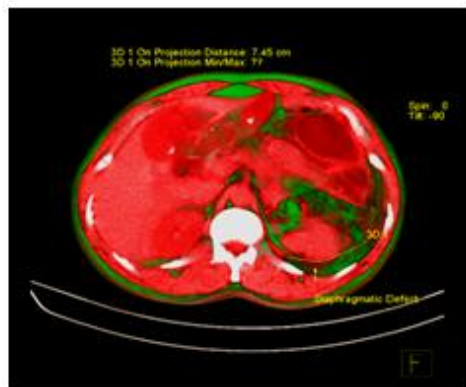

Figure 2

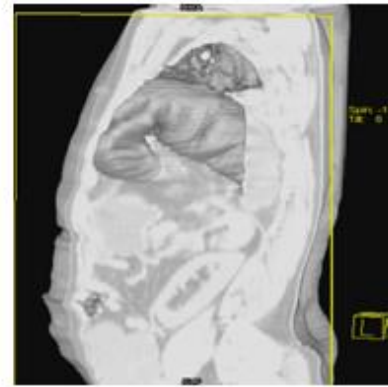


Figure 3

A diagnosis of Bochdalek hernia was made and immediately posted for surgery. Under GA double lumen endotracheal tube placed and left bronchus blocked. Lt thoracotomy was done. Thoracic cavity was filled with feces; transverse colon was distended and adherent to Lt lung. Two perforations were present in transverse colon 2*1.5cm and 1*1 cm. Abdomen was opened in midline. The herniated transverse colon is reduced into abdominal cavity by cutting and extending the rent in the diaphragm (fig 4,5). Resection and end to end anastomosis of transverse colon done, rent of diaphragm sutured from

thoracic side (fig 6), abdominal and chest tube drains were placed; wounds closed in layers. Recovery from anaesthesia was good. Postoperative period was stormy. Patient was kept under ventilator support. Three units of blood, albumin and five units FFP were transfused. Orals were allowed on 5th postoperative day, abdominal drains removed on 14th postoperative day. Thoracic cavity wash was done with saline through chest tube and it was removed on 19th postoperative day. By 21st day left lung was fully expanded.

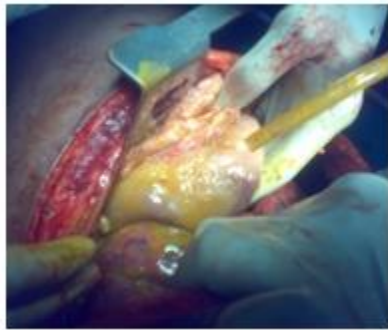

Figure 4

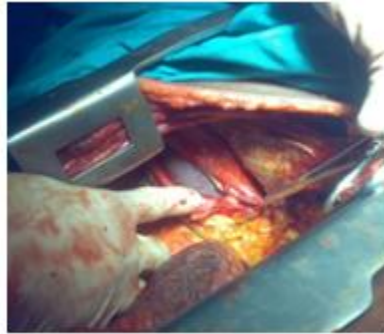


Figure 5

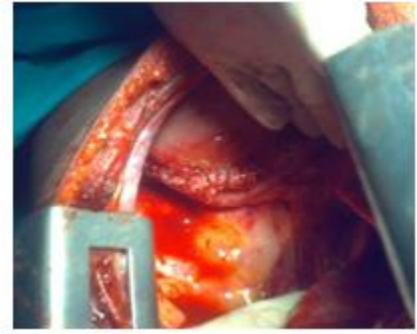

Figure 6

DISCUSSION

Bochdalek hernia is a congenital anomaly in neonatal and postnatal patients and occurs in about one in 2,200 to 12,500 live births. The foramen of Bochdalek is a 2cm x 3cm opening in the posterior aspect of the diaphragm in the foetus, through which the pleura-peritoneal canal communicates between the pleural and peritoneal cavities. This canal normally closes by the 8th week of gestation, failure or incomplete fusion of the lateral (costal) with the posterior (crural) components of the diaphragm leads to the development of Bochdalek hernia. Since the left canal closes later than the right, this type of hernia is found on the left side in 85% of cases³. The organs that most commonly herniate into the thorax through this defect are stomach, ileum, colon and spleen. The liver and the right kidney may herniate along with the bowel loops if the defect is on the right side. Bochdalek hernia is a congenital anomaly seen in neonatal and postnatal patients but it is rare in adults⁴. Most Bochdalek hernias are diagnosed in children who present with acute pulmonary symptoms⁵. In contrast to the acute presentation by infants with these hernias, most adults present with more chronic symptoms, such as chronic dyspnoea, chest pain and pleural effusion. Recurrent abdominal pain, postprandial fullness and vomiting are the most common abdominal symptoms in adults⁶. Some patients have no symptoms and the disorder is unexpectedly detected on chest X-ray. It may present in a complications of this hernia like strangulation of the

contents of the hernia, colon necrosis, hemothorax and tension pneumothorax. Long-term survival may be due to the persistence of a pleura-peritoneal sac, and the rupture of the sac in adult life may trigger the characteristic symptoms. The diagnosis of Bochdalek hernia can be made by conventional radiological methods like plain radiographs and barium studies. Ultrasonography also has a role to play in the antenatal diagnosis of this condition; a level 3 ultrasound examination is the criterion standard for reaching a diagnosis of congenital diaphragmatic hernia in utero. Features indicative of congenital diaphragmatic hernia are polyhydramnios, presence of intra thoracic stomach bubble, mediastinal and cardiac shift away from the side of herniation and rarely fetal hydrops. In the post natal evaluation of diaphragmatic hernia, ultrasonography can assist in delineating the diaphragm in its entirety and also in evaluating the viscera that has herniated into the thoracic cavity⁷. Computed Tomography is believed to be the most accurate method of diagnosing and evaluating the contents of these hernias especially the smaller ones⁸. CT with multiplanar reconstructions can accurately assess the thoracic cavity and also detect any other associated anomalies. In adults since the diagnosis is usually missed unless there is a high index of suspicion, CT has an increasingly important role to play. Management of a Bochdalek hernia includes reducing the abdominal contents and repairing the defect through a laparotomy or thoracotomy. Successful laparoscopic and thoracoscopic

repairs of Bochdalek hernias have both been described. Right-sided defects are traditionally dealt with by a thoracic or thoraco-abdominal approach because of the presence of the liver. For left-sided hernias some advocate a transthoracic approach while others suggest a transperitoneal approach⁹.

CONCLUSION

People with a Bochdalek hernia may not have any symptoms and the disorder may be detected unexpectedly, or the symptoms and expressions may vary from mild to serious complications. Hence a careful examination, strong index of suspicion and imaging studies like Computed Tomography are needed to reach a correct diagnosis. The treatment of Bochdalek hernia is operative and patients generally do not have any recurrence and remain asymptomatic.

REFERENCE

1. Thomas S, Kapur B. Adult Bochdalek hernia: clinical features, management and results of treatment. *Jpn J Surg* 1991; 21:114-9.

2. Mullins ME, Stein J, Saini SS, Mueller PR. Prevalence of incidental Bochdalek's hernia in a large adult population. *AJR Am J Roentgenol.* 2001; 177:363-366.
3. Nyhus L, Condon R. *Hernia.* 4th ed. Philadelphia, Pa: JB.Lippincott Co; 1995: 555-66.
4. Yamaguchi M, Kuwano H, Hashizume M, Sugio K, Sugimachi K, Hyoudou Y: Thoracoscopic treatment of Bochdalek hernia in the adult: report of a case. *Ann Thorac Cardiovasc Surg* 2002,8:106-108
5. Kocakusak A, Arikan S, Senturk O, Ycel AF: Bochdalek's hernia in an adult with colon necrosis. *Hernia* 2005, 9:284-287.
6. Kanazawa A, Yoshioka Y, Inoi O, Murase J, Kinoshita H: Acute respiratory failure caused by an incarcerated right-sided adult Bochdalek hernia: report of a case. *Surg Today* 2002, 32:812-815.
7. Oldham KT, Colombani PM, Foglia RP: Congenital diaphragmatic hernia. In: *Surgery of Infants and Children: Scientific principles and practice.* Philadelphia, Pa: JB Lippincot; 1997:883-95.
8. Shin MS, Mulligan SA, Baxley WA, Ho KJ. Bochdalek hernia of diaphragm in the adult. Diagnosis by computed tomography. *Chest* 1987; 92:1098-1101.
9. Rout S, Foo FJ, Hayden JD, Guthrie A, Smith AM: Right-sided Bochdalek hernia obstructing in an adult: case report and review of the literature. *Hernia* 2007, 11:359-362.

Source of Support: None Declared
Conflict of Interest: None Declared