

# Origin of inferior phrenic arteries from coeliac trunk: A case report

Manoj Borkute<sup>1</sup>, Gopal Bagal<sup>2\*</sup>

<sup>1</sup>Assistant Professor, Department of Anatomy, Seth G.S. Medical College and K.E.M. Hospital, Mumbai, Maharashtra, INDIA.

<sup>2</sup>Associate Professor, Department of Anatomy, A.C.P.M Medical College, Dhule-424001, Maharashtra, INDIA.

Email: [drgopalbagal@gmail.com](mailto:drgopalbagal@gmail.com)

## Abstract

The inferior phrenic arteries constitute a pair of important vessels, supplying multiple organs including the diaphragm, adrenal glands, esophagus, stomach, liver, inferior vena cava, and retroperitoneum. The knowledge of the arterial anatomic variations is very important for the clinical, radiological and surgical diagnosis. Regarding inferior phrenic arteries which irrigate the diaphragm, it is known that they vary in relation to their origin. Infrequently, both inferior phrenic arteries can arise in the form of common trunk from the aorta or from a coeliac trunk. It employs the most frequent origin of extrahepatic arterial blood source in hepatocellular carcinoma. Due to very less information concerning the inferior phrenic arteries and their importance in the arterial supply and growth of hepatocellular carcinoma, these arteries have received increased attention in the recent years. Awareness of the arterial variations in the upper GIT region, such as shown in our case, is very important during surgical and radiological procedures pertaining to the liver and adjacent viscera.

**Keywords:** Coeliac trunk, Inferior phrenic arteries, Hepatic artery, Hepatocellular carcinoma.

## \*Address for Correspondence:

Dr. Gopal Bagal, Department of Anatomy, Associate Professor, A.C.P.M Medical College, Dhule-424001, Maharashtra, INDIA.

Email: [drgopalbagal@gmail.com](mailto:drgopalbagal@gmail.com)

Received Date: 06/08/2015 Revised Date: 14/08/2015 Accepted Date: 20/08/2015

Access this article online	
Quick Response Code:	Website: <a href="http://www.statperson.com">www.statperson.com</a>
	DOI: 23 August 2015

## INTRODUCTION

The arterial supply for the foregut derivatives in the abdomen is provided by the branches of the coeliac trunk. Variations in the vascular pattern of the coeliac trunk and its branches should be considered while planning surgical interventions on the abdominal part of esophagus, stomach, duodenum, liver, pancreas, gall bladder and spleen. Abdominal variations of the coeliac trunk are important for surgeon undertaking different surgeries on the abdominal region, including liver transplantation<sup>1</sup>. Clinician should be aware of the variations in the vascular pattern of the coeliac trunk before performing angiographic examinations. The coeliac artery also known as the coeliac trunk or coeliac

axis is a ventral branch of abdominal aorta. It is a short wide branch about 1.25 cm long, that arises from the aorta at the level of T12-L1 vertebrae immediately below the aortic hiatus of the diaphragm. The coeliac axis and its branches supply the derivatives of foregut. Coeliac trunk variations have been reported in the various literatures. The prevalence of normal branching pattern of coeliac axis into hepatic, splenic and left gastric arteries have been reported by Malnar *et al* as 72%<sup>2</sup>, Song *et al*. 89%<sup>3</sup>, Ugure *et al*. 89%<sup>4</sup> and Bergman *et al*. 86%. The inferior phrenic artery (IPA) is the most common source of extra-hepatic collateral blood supply for hepatocellular carcinoma (HCC) and frequently supplies HCCs located in the bare area of the liver<sup>5</sup>. Other pathologic conditions including hemoptysis, diaphragmatic or hepatic bleeding due to trauma or surgery, and bleeding caused by gastroesophageal problems (eg, Mallory-Weiss tear or gastroesophageal cancer) may be related to the IPA<sup>6</sup>. Each artery ascends and diverge from one another anterior to the crura of the diaphragm, near the medial border of the suprarenal gland and then run obliquely upward and laterally upon its under surface. The left phrenic passes behind the esophagus and runs forward on the left side of the esophageal hiatus. The right phrenic passes posterior to the inferior vena cava. and then along

the right side of the diaphragmatic opening for inferior vena cava. Near the back part of the central tendon each vessel divides into medial and lateral branches. The medial branch curves forward, and anastomoses with its fellow of the opposite side in front of the central tendon, and with the musculophrenic and pericardiophrenic arteries. The lateral branch approaches the thoracic wall and anastomoses with the lower posterior intercostal and musculophrenic arteries. The lateral branch of the right phrenic gives off a few vessels to the inferior vena cava; and the left one, some branches to the esophagus. Although descriptions of the right inferior phrenic artery (RIPA) and left inferior phrenic artery (LIPA) are typically very brief, they have received increased attention in recent years because of the involvement of the right (most frequently) or left inferior phrenic arteries in the arterial supply and growth of hepatocellular carcinoma (HCC). There are few publications concerning the role and detailed anatomy of the Inferior phrenic artery (IPA) with respect to their involvement in HCC. Modern anatomy textbooks offer few details of the anatomy of the inferior phrenic arteries. Considering the importance of RIPA in HCC and other hepatic neoplasms including the metastatic diseases of liver, interventional radiologists or oncologists are benefitted from the knowledge of common variations in origin of these vessels and their respective frequencies of occurrence. An unresectable HCC can be treated by transcatheter embolization of not only the right or left hepatic arteries, but also by embolization of a RIPA, if involved.

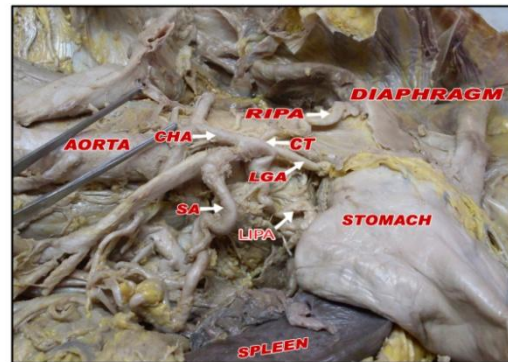
## MATERIAL AND METHOD

This variation was found during routine dissection of abdomen in a 50 years old adult male cadaver in the department of Anatomy. The cadaver was embalmed through carotid arterial perfusion of formaldehyde solution and preserved in a weak formalin solution before dissection. The dissection was performed in the dissection hall of a reputed medical institute of Maharashtra. Routine manual dissection was done to open the abdomen following the instruction of Cunningham's manual. After removal of the lesser omentum, the proximal part of abdominal aorta and its branches were traced out. Later, after the removal of stomach and pancreas, the origin of Inferior phrenic artery was confirmed.

## OBSERVATION

During the routine dissection it was seen that, both the right and left inferior phrenic arteries (RIPA and LIPA) took its origin from the coeliac trunk instead of taking origin from abdominal aorta in a 50 year old male cadaver. Further distribution of right and left phrenic

artery was normal. There was no other vascular anomaly present in this cadaver. (figure)



**Figure 1:** Photograph of abdomen showing the origin of inferior phrenic arteries from coeliac trunk.

CT-coeliac trunk, CHA-common hepatic artery, LGA-left gastric artery, RIPA- right inferior phrenic artery, LIPA- left inferior phrenic artery, SA- splenic artery.

## DISCUSSION

The knowledge of the arterial anatomic variations is very important for clinical, radiological and surgical diagnosis. Regarding inferior phrenic arteries, which irrigate the diaphragm, it is known that they vary in relation to their origin. Vascular variations are constantly observed in dissection of adult cadavers. In a CT scan study of Gokan *et al*<sup>7</sup> it was found that in 46% of cases RIPA was arising from aorta and in 52% of cases LIPA was arising from coeliac trunk. They also noted alternative origins (left gastric, hepatic, superior mesenteric, and spermatic), stating that such origins occurred with <4% frequency on either the right or left side. In another study conducted by Pulakunta T *et al*<sup>8</sup> in a 32 cadavers found the origin of the inferior phrenic arteries from coeliac trunk in two specimens (6.25%), one from the left gastric artery (3.125%) and one from the right renal artery (3.125%) out of the 32 cadavers. In the remaining 28 specimens it had its normal origin from the abdominal aorta. Loukas *et al*<sup>9</sup> studied 300 cadavers and observed that the origin of right IPA from: a) coeliac trunk in 40% of the specimens; b) aorta in 38%; c) renal in 17%; d) left gastric in 3%; and e) hepatic artery proper in 2% of the specimens. The origin of left inferior phrenic artery was from: a) coeliac trunk in 47%; b) aorta in 45%; c) renal in 5%; d) left gastric in 2%; and e) hepatic artery proper in 1% of the specimens. Out of 68 cadavers studied, Piao DX *et al*<sup>10</sup> mentioned the majority of the origin of inferior phrenic arteries from the aorta (61.6%) and the origins from either renal, left gastric or middle adrenal arteries were also observed. Pick and Anson<sup>11</sup> studied the inferior phrenic artery origins using 200 cadavers and noted that most common

sources were aorta and coeliac artery (45.1 and 47.8%, respectively). They reported that <7% originated variably from the renal (5.8%), left gastric (2.3%) or hepatic

arteries (0.3%). Following table shows the percentage of various origins of IPA in different studies. (Table.1)

**Table 1:** Comparison of the percentage of various origins of Inferior phrenic artery in various studies

Source of origin of IPA	Pulkana <i>et al.</i> (32 cadavers)	Pick and Anson (200 cadavers)	Piao <i>et al.</i> (68 cadavers)	Gwon (383 cadavers)	B.Akhilandeswari <sup>12</sup>
Aorta	87.5 %	45.1 %	61.6 %	38.6 %	53.125 %
coeliac trunk	6.25 %	47.8 %	28.2 %	39.7 %	28.125 %
Renal artery	3.125 %	5.8 %	10.19 %	15.4 %	15.625 %
Others	LGA- 3.125%			LGA-3.7 % SMA-0.3 % HA-2.1 % Opp. IPA-0.3 %	LGA-3.125 %

**Table 2:** Comparison of the percentage of various origins of right and left inferior phrenic artery in the various studies

Source of origin	Gokan 16-cadavers		Loukas 300-cadavers		Basile 200 cadavers		B.Akhilandeswari 32 cadavers		S.Thamke 30 cadavers	
	RIPA	LIPA	RIPA	LIPA	RIPA	LIP A	RIPA	LIP A	RIPA	LIPA
Aorta	31.25	31.25	38	45	49	47.5	56.25	50	94.5	97.2
Coeliac trunk	37.5	50	40	47	41	44	18.75	37.5	-	-
Renal artery	12.5	18.75	17	5	5.5	1	18.75	12.5	-	-
Others			LGA-3 HA-2	LGA-2 HA-0.5	LGA-4 HA-0.5		SMA-6.25	0	LGA-1 case HA-1 case	LGA-1case

RIPA-Right inferior phrenic artery, LIPA-Left inferior phrenic artery, LGA-Left gastric artery, HA-hepatic artery. In a study of Rossi and Cova 1904, Adachi, 1928 and Pick and Anson, 1941 inferior phrenic artery was arising more frequently from the coeliac axis. However Quain in 1844; Descomps in 1910; and Lipshutz in 1917 commented that the inferior phrenic artery arises more commonly from the aorta than from coeliac trunk.

**Embryological basis**

During fetal development coeliac trunk and inferior phrenic artery are derived from six pairs of ventral splanchnic branches<sup>13</sup>. These branches span and disappear, however the persistence of longitudinal channels between these primitive vessels may lead to vascular variations. Inferior phrenic artery is said to be formed by the persistent superior artery of irregular series of arterial vessels called Rete arteriosus urogenitale.

**CONCLUSION**

Modern surgical techniques depend in part on knowledge of both the normal and the anomalous arterial blood supply. The inferior phrenic artery is a major source of collateral or parasitized blood supply to hepatocellular carcinoma, second only to hepatic artery. This is useful to evaluate the efficacy and safety of transcatheter oily

chemoembolization therapy (TOCE) via the inferior phrenic artery (IPA). The knowledge of this type of variation shows that surgeons must be cautious to avoid unintentional sectioning of small caliber arteries, as it may occur during the coeliac artery decompression in the compression syndrome of the coeliac trunk by the median arcuate ligament.

**REFERENCES**

1. Munshi I.A, Fusco D, Tashjjan D, Kirkwood J.R, Polya J, Wait R.B: Occlusion of an Aberrent Right Hepatic Artery, Originating from the Superior Mesentric Artery, Secondary to Blunt Trauma: J. Trauma.2000; 48: 325-326.
2. Malnar D, Klasan G.S, Miletić D, et al.:Properties of the Coeliac trunk--Anatomical Study: Coll. Antropol. 2010; 34: 917-21.
3. Song S.Y, Chung J.W, Yin Y.H, et al.: Coeliac Axis and Common Hepatic Artery Variations in 5002 Patients: Systematic Analysis with Spiral CT and DSA: Radiology.2010; 255: 278-88.
4. Ugurel M.S, Battal B, Bozlar U, et al.: Anatomical Variations of Hepatic Arterial System, Coeliac Trunk and Renal Arteries: An Analysis with Multidetector CT Angiography:Br. J. Radiol. 2010; 83: 661-71.
5. Tannabe N, Iwasaki T, Chida N: Hepatocellular Carcinomas Supplied by Inferior Phrenic Arteries: Acta Radiol.1998; 39: 443-6.

6. Hieda M, Toyota N, kakizawa H, et al.: The Anterior Branch of the Left Inferior Phrenic Artery Arising from the Right Inferior Phrenic Artery: An Angiographic and CT study. *Cardiovasc Intervent Radiol.* 2009; 32: 250-4.
7. Gokan T, Hashimoto T, Matsui S, Kushihashi T, Nobusawa H, Munechika H: Helical CT Demonstration of Dilated Right Inferior Phrenic Arteries as Extrahepatic Collateral Arteries of Hepatocellular Carcinomas: *J. Comput. Assist Tomogr.* 2001; 25: 68-73.
8. Pulakunta T, Potu B.K, Gorantla V.R, Rao M.S, Madhyastha S, Vollala V.R: The Origin of the Inferior Phrenic Artery: A study in 32 South Indian cadavers with a Review of the Literature: *J. Vas. Bras.* 2007; 6: 3.
9. Loukas M, Hullett J, Wagner T: Clinical Anatomy of the Inferior Phrenic Artery: *Clin Anat.* 2005; 18(5): 357-65.
10. Piao D.X, Ohtsuka A, Murakami T: Topology of Abdominal Arteries, with Special Reference to Inferior Phrenic Arteries and their esophageal branches: *Acta Med Okayama.* 1998; 52: 189-96.
11. Pick J.W, Anson B.J: The Inferior Phrenic Artery: Origin and Suprarenal Branches: *Anat Rec.* 1940; 78: 413-27.
12. Akhilandeswari B, Ranganath P: Variation in the Origin of Inferior Phrenic Artery: A Cadaveric Study: *J. Anat. Soc. India.* 2013; 62: 6-9.
13. Cavder S, Sehirii U, Pekin b: Celiacomesenteric trunk: *Clin. Anat.* 1997; 231-4.

Source of Support: None Declared  
Conflict of Interest: None Declared