Case Report

# Endometrial stromal nodule with divergent differentiation

Jenita Christiana[1], Prathipa K[2*], Uma R[3], Arunkumar N[4], Meharajbanu O A[5]

[1]Associate Professor [2,3,4,5]Assistant Professor, Department of Pathology, Government Thiruvarur Medical College, Vilamal, Thiruvarur – 610004, Tamil Nadu, INDIA.
**Email:** prathipa_krishnamurthy@yahoo.com

## Abstract

Endometrial stromal nodule (ESN) is the least common tumour among the spectrum of endometrial stromal tumours which behaves in a benign fashion and has the best prognosis. Even though they are benign, hysterectomy has been considered as the treatment of choice to determine the margin of the tumor and to differentiate from invasive stromal sarcoma for prognostic and therapeutic consideration. We report a case of a 50 year old woman who presented with abdominal pain and post-menopausal bleeding. This case is presented owing to the rarity of the lesion and for their prognostic significance over endometrial stromal sarcomas.
**Keywords:** Endometrial stromal nodule, hysterectomy, CD10.

**[*]Address for Correspondence:**
Dr. Prathipa K., Assistant Professor, Department of Pathology, Government Thiruvarur Medical College, Vilamal, Thiruvarur – 610004, Tamil Nadu, INDIA.
**Email:** prathipa_krishnamurthy@yahoo.com
Received Date: 02/08/2015 Revised Date: 10/09/2015 Accepted Date: 23/09/2015

| Access this article online | |
|---|---|
| Quick Response Code: | Website: www.statperson.com |
| | DOI: 08 October 2015 |

## INTRODUCTION

Mesenchymal tumors of the uterus with cytological and architectural features reminiscent of endometrial stromal cells are classified as endometrial stromal tumours[1] (EST).They constitute the least common neoplasms of the uterine corpus with an annual incidence of about 2/million women[2] and account for less than 5% of uterine tumours. Recent WHO classification of tumors of the breast and female genital organs divide the uterine stromal neoplasms into three groups namely, benign endometrial stromal nodule (ESN), low grade endometrial stromal sarcoma (LGESS) and undifferentiated endometrial sarcoma (UES)[3,4,2,1,5]. Endometrial stromal nodule is a rare benign neoplasm accounting for one fourth of EST[1]. It is composed of well differentiated endometrial stromal cells arranged as a circumscribed nodule with smooth non invasive margins. Endometrial stromal nodule is an indolent tumour and needs to be distinguished from other stromal sarcomas owing to their indolent biological behavior.[1]

## CASE REPORT

A 50 year old woman presented with abdominal pain and post menopausal bleeding. Complete blood count and other haematological investigations were within normal limits. Abdominal ultrasound showed a heterogeneous well circumscribed mass measuring 7x4cm in the myometrium. She underwent total abdominal hysterectomy.

### GROSS

We received total abdominal hysterectomy specimen measuring 5x4x4.5cm.Cut section of the uterus showed an intramural nodule measuring 3.5x2cm without any apparent connection with the endometrium. Grossly the nodule shows yellow to tan solid areas along with cystic areas filled with haemorrhagic material [Figure1].

### MICROSCOPY

Histopathology shows a circumscribed neoplasm composed of round to ovoid cells with scant to moderate amount of cytoplasm, finely granular dispersed chromatin, exhibiting mild atypia interrupted by evenly distributed spiral arterioles like blood vessels of uniform calibre showing focal whorling of neoplastic cells around them [Figure 2,3 and 6]. Areas of hemorrhage and cystic

How to site this article: Jenita Christiana, Prathipa K, Uma R, Arunkumar N, Meharajbanu O A. Endometrial stromal nodule with divergent differentiation. *International Journal of Recent Trends in Science and Technology.* October 2015; 16(3): 533-536 http://www.statperson.com (accessed 12 October 2015).

degeneration are seen. Mitotic figures ranging about less than 3/10 hpf have been observed. Areas of tongue like projections two in number and satellite nodules of less than 3 in number are noted within 3mm from the main border of the tumor. Focal areas of smooth muscle differentiation and sex cord differentiation also have been observed [Figure 4 and Figure 5]. Immunohistochemistry revealed CD10 positivity in the tumour cells and satellite nodules [Figure 7 and Figure 8].


Figure 1

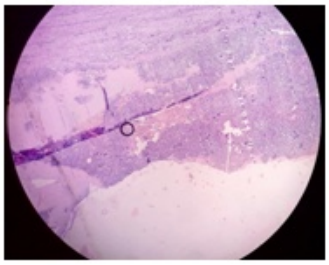

Figure 2

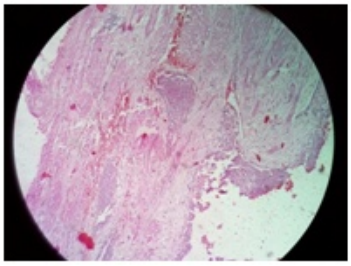

Figure 3

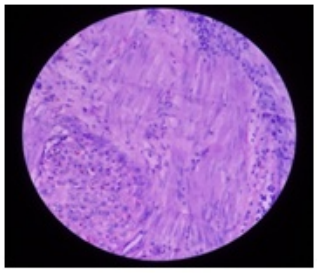

Figure 4

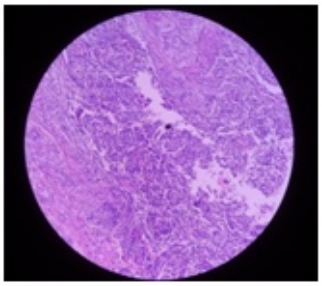

Figure 5

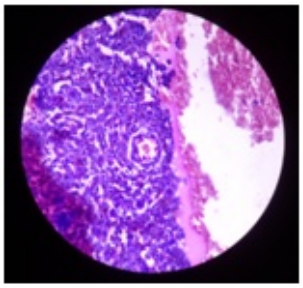

Figure 6

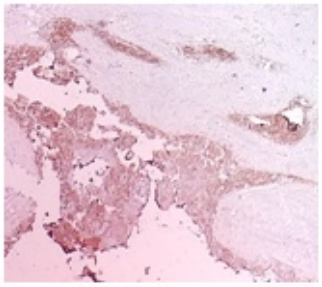

Figure 7

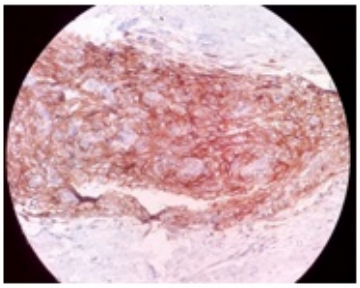

Figure 8

**Figure 1:** Cut surface of the specimen - Circumscribed nodule showing yellow to tan solid areas along with cystic areas filled with haemorrhagic material.
**Figure 2:** Low power view shows stromal nodule with well demarcated margin
**Figure 3:** Low power view shows satellite nodules and tongue like projections.
**Figure 4:** High power view shows tumour cells with smooth muscle differentiation
**Figure 5:** Low power view shows tumour cells with areas of sex cord differentiation
**Figure 6:** High power view shows sheets of tumour cells exhibiting focal whorling around the spiral arterioles.
**Figure-7 and 8:** CD 10 positivity in the tumour cells and satellite nodules.

## DISCUSSION

Benign endometrial stromal nodule is a rare mesenchymal tumor that accounts for about one fourth of the endometrial stromal tumors[6,7]. ESN are known to occur primarily in the perimenopausal and postmenopausal age groups. In a review of 60 women with endometrial stromal nodule by Tavassoli and colleagues, the median age was 47 yrs[8]. Rola *et al* in their studies have reported the incidence to be in the range of 31 to 86 years. Clinically the presentation is varied and nonspecific as majority of them present with bleeding, abdominal discomfort or pain and anaemia. Our case too was an old female in perimenopausal age group with abnormal bleeding and vague dull abdominal pain. Fidili *et al* reported a painless abdominal mass without abnormal bleeding[6]. Macroscopically, the tumour is a solitary well delineated round fleshy nodule with yellow to tan cut surface and median tumour diameter of 4cm ( range 0.8 to 15cm )[1,4]. About two thirds are purely intramural without any apparent connection with the endometrium[6]. Rarely the tumours are cystic with areas of necrosis and hemorrhage. Likewise in our case, the tumour was about 3.5x2cm with an intramural location along with cystic area and foci of hemorrhage as observed and reported by Henry J Norris. By definition, endometrial stromal nodules are circumscribed stromal tumours composed of cells with uniform nuclei, scanty cytoplasm and occasional mitoses having resemblance to stromal cells of normal proliferative phase endometrium. These cells appear to whorl around the prominent vessels that resemble the spiral arterioles of non- neoplastic endometrium. Epithelial or sex cord like differentiation are observed as cords, trabeculae and glandular configuration[1,4]. In our case, we had foci of sex cord differentiation in the form of cords in accordance with the literature. Aloui *et al* reported that endometrial stromal nodule with focal sex cord like differentiation tend to relapse and metastasize.[6] In the report of 5 cases by

Clement and Scully, three had recurrence and two died. Pei Hui *et al*[11] in their study have observed smooth muscle differentiation in 17 cases of endometrial stromal nodules. They have done Human Androgen Receptor Gene (HUMARA) clonality analysis revealing a consistent loss of right AR allele indicating a monoclonal proliferation of these tumours whereas leiomyoma indicate a randomized allelic loss. Currently little knowledge exists regarding the behavior of these lesions with smooth muscle differentiation and it seems to be dictated by the endometrial stromal component as per literature.[11] Elagoz etal[1], AlouiFdili FZ – etal[6], Ryokok *et al* and SafiaRana *et al* [2]have described cases of ESN with well circumscribed smooth and expansible margin. The most important single criteria for the diagnosis of ESN is the finding of a non- infiltrative border of the tumor. However as per the literatures quoted by Patricia Baher *et al*[4] and Rola H Ali *et al*, focal irregularities in the form of lobulated or finger like projections that are not >3mm and are not >3 in number may be seen. Elagozer al [1]in their report of 5 cases of endometrial stromal tumours have observed one neoplasm that had two tongue like projections and detached satellite nodules expanding into or lying within the adjacent myometrium and these foci were less than 3mm beyond the main border of the tumour. Likewise in our case, we had observed two tongue like projections and nodules of less than 3 in number and within 3mm in largest dimension. Endometrial stromal tumour with limited infiltration is an entity recently described as a tumour that does not fulfill the criteria for an endometrial stromal nodule ( having <3 tongues or nodules at the most 3mm in the largest dimension) and does not have an overt permeative growth of low-grade ESS or the associated vascular invasion.[4]Diagoni *et al* had observed three such cases in their clinicopathologic study of 50 cases and has recommended that these tumors should be diagnosed as endometrial stromal tumours with limited infiltration and separated from conventional ESN and ESS till the knowledge of their behaviour is established.[1]It is very difficult to predict the progression of these tumors as studies with long term follow-up are scarce. Patricia Baheretal[4] had highlighted that currently these tumors are best diagnosed as low grade ESS with an explanatory note stating that the tumour is not as overtly invasive as a typical low grade ESS and for this reason the tumor may be considered to behave in a more benign fashion. Differential diagnosis of ESN comprises of low grade endometrial stromal sarcoma and cellular leiomyoma. ESN is a grossly well delineated tumour with expansile growth at its margins while LGESS has an infiltrating margin with myometrial invasion and metastasis beyond the uterus with or without recurrence. Microscopic appearances of ESN and LGESS are similar. Myometrial and vascular invasion are the two utmost important features to distinguish between these tumors[13]. Hence, a confident diagnosis could be made on a hysterectomy specimen with extensive sampling rather than a curettage specimen. Another important differential diagnosis is cellular leiomyoma which has overlapping gross features with ESN as both are yellow or yellow tan with soft consistency. Helpful histological clues in favour of leiomyoma are fascicular growth of spindle cells, cleft like spaces representing compressed vessels or large thick muscular blood vessels in contrast with the spiral arterioles of ESN. Since both ESN and cellular leiomyoma are benign entities, distinguishing between the two entities in hysterectomy specimen doesn't carry any prognostic significance. However in curettage specimen, there arrives a need, since cellular leiomyoma can be managed conservatively whereas in the case of ESN hysterectomy should be done to further categorize the tumor.[4] It is important to remember that stromal nodule may have areas of smooth muscle differentiation underscoring the importance of correlation of morphological findings with immunohistochemical results.

Ancillary diagnostic techniques like immunohistochemistry with the panel of antibodies help in distinction of these entities. Cellular leiomyomas express caldesmon[12] and desmin[13,14] whereas CD10 expression is a feature of stromal cells.[1,2,14] The common acute lymphoblastic leukemia antigen (CALLA or CD10) functions as a cell surface enzyme that acts to reduce cellular response to peptide hormones by regulating local peptide concentration. Thus many hormone sensitive and peptide sensitive cells and their corresponding neoplasms express CD10 antigen including normal endometrial stroma and stromal neoplasms. ESN with sex cord like differentiation shows preferential staining for CD117[1], EMA[1], Inhibin,[6,14] CD99[6,4]. ESN with smooth muscle differentiation showed positivity for SMA, caldesmon and desmin[11].

## CONCLUSION

ESN is an uncommon benign mesenchymal tumour with non specific clinical presentation. Diagnosis can be established based on the morphology in light microscopy. Hormonal therapy has been successful in decreasing the size of tumor thereby allowing for conservative management incase of young females who desire to preserve fertility[11,15]. In such cases diagnostic imaging or hysteroscopy may be used to follow up tumour growth[2]. Since majority of women are beyond child bearing age, hysterectomy is usually required to permit thorough evaluation. The margins of the tumour must be

established to differentiate from invasive stromal tumours.[2,6] ESN is a benign tumor with excellent prognosis when a definitive diagnosis is established.

## REFERENCES


1. Sahande Elagoz, Fügen Kıvanc, Handan Aker, Sema Arici, Hatice Ozer Tevfik Güvenal, Ömür Erden. Endometrial stromal tumors – a report of 5 cases. Aegean Pathology Journal. 2005(2): 140–145.
2. Safia Rana, Zeeba Jairajpuri, RashmiTiwari. Endometrial Stromal Nodule. Iranian Journal of Pathology.2013; 8 (2):110 – 114.
3. F. Z. Fdili Alaoui, H. Chaara, H. Bouguern, M. A.Melhouf, H. Fatemi, A. Belmlih, and A. Amarti. Endometrial Stromal Nodule: Report of a Case. Hindawi Publishing Corporation Case Reports in Medicine. 2011; Article ID 260647, 5 pages.
4. Patricia Baker, Esther Oliva. Endometrial stromal tumours of the uterus: a practical approach using conventional morphology and ancillary techniques. J Clin Pathol. 2007; 60:235–243.
5. Tavassoli FA, Devilee P (Editors) (2003) World Health Organization Classification of Tumours. Pathology and Genetics of Tumours of the Breast and Female Genital Organs. IARC Press: Lyon 2003.
6. F. A. Tavassoli and H. J. Norris. Mesenchymal tumors of the uterus. VII. A clinicopathological study of 60 endometrial stromal nodules.Histopathology.1981;5(1) :1–10.
7. Kanji RYUKO, Kentaro TAKAHASHI and Kohji MIYAZAKIA, Case of Endometrial Stromal Nodule. ShimaneJ. Med. Sci.,14;27-2B, 1se5/96.
8. Weiwei Feng, Anais Malpica, Ivar Skaland, Einar Gudlaugsson, Stanley J. Robboy, Ingvild Dalen, Keqin Hua, Xianrong Zhou, Jan P. A. Baak. Can Proliferation Biomarkers Reliably Predict Recurrence in World Health Organization 2003 Defined Endometrial Stromal Sarcoma, Low Grade? Oct 2013; 8(10) :e75899.
9. RolaH Ali, Marjan Rouzbahman. Endometrial stromal tumors revisited: an update based on the 2014 WHO Classification. J Clinical Pathol. 2015; 68(1):325-332.
10. HenryJ.Norris, ID and HerbertB.TayloMRD. A clinical and pathological study of 53 Endometrial stromal tumors –JCP.
11. Pei Hui and George Fedoriw. Recurrent endometrial stromal tumors with smooth-muscle differentiation and a protracted clinical course. Nature clinical practice oncology. Nov 2005;2 (11)
12. Diagoni A, Oliva, Clement PB, Young RH. Endometrial stromal nodules and endometrial stromal tumors with limited infiltration. Am J SurgPathol. 2002; 26 (5): 567-81.
13. Oliva E, Young RH, Clement PB, Scully RE. Myxoid and fibrous endometrial stromal tumors of the uterus: a report of 10 cases. Int J Gynecol Pathol 1999; 18:310–9.
14. Peiguo G. Chu, M.D., Ph.D., Daniel A. Arber, M.D., Lawrence M. Weiss, M.D., Karen L. Chang, M.D.Division of Pathology, City of Hope National Medical Center, Duarte, California Utility of CD10 in Distinguishing between Endometrial Stromal Sarcoma and Uterine Smooth Muscle Tumors:An Immunohistochemical Comparison of 34 Cases Mod Pathol 2001;14(5):465–471.
15. Schilder JM *et al.* (1999) Hormonal treatment of an endometrial stromal nodule followed by localexcision.ObstetGynecol 93: 805–807.


Source of Support: None Declared
Conflict of Interest: None Declared