Original Article

A study of retrohepatic segment of inferior vena cava and hepatic vein openings

D Malar

Associate Professor, Department of Anatomy, JSS Medical College, JSS University, Mysore, Karnataka, INDIA.
Email: malarjan2519@gmail.com

Abstract

The retrohepatic segment of inferior vena cava and hepatic vein openings were studied in 30 adult livers. Altogether 322 hepatic vein openings were observed .The openings were classified into large, medium and small according to the size of the opening. The position of the ostia was studied by dividing the posterior wall of retrohepatic segment of inferior vena cava into 16 areas. The large openings were right, left and middle hepatic veins. The large openings showed different pattern of combinations. The anatomical knowledge of retrohepatic segment of Inferior vena cava and hepatic vein openings are important in preoperative evaluation, in liver resections and transplantation procedures.

Keywords: Retrohepatic segment, Inferior vena cava, hepatic vein openings and preoperative evaluation.

*Address for Correspondence:
Dr D. Malar, Associate Professor, Department of Anatomy, JSS Medical College, JSS University, Mysore, Karnataka, INDIA.
Email: malarjan2519@gmail.com
Received Date: 30/10/2015 Accepted Date: 30/10/2015

Access this article online	
Quick Response Code:	Website: www.statperson.com
	DOI: 04 November 2015

INTRODUCTION

The hepatic veins drain blood from the liver into Inferior vena cava. The tributaries arise within the parenchyma of the liver. The hepatic veins are arranged as superior and inferior groups. The superior groups are large in size and commonly referred to as the right, middle and left hepatic veins. The lower groups vary in number and are small veins draining directly into Inferior vena cava[1]. Knowledge regarding the openings of hepatic veins into the retrohepatic segment of inferior vena cava is essential in selective venography, locating the membrane obstruction in Budd-chiari syndrome, and determining hepatic circulation[2,3]. Keeping in view of the applied importance, the present study was undertaken to provide information on the gross anatomy of retrohepatic segment of inferior vena and ostia venae hepaticae.

MATERIALS AND METHOD

Thirty apparently healthy livers from adult cadavers were dissected and studied. The length of the retro hepatic segment was measured. This was followed by opening the posterior wall of Inferior vena cava (IVC) to measure the openings of hepatic veins. The internal wall of retro hepatic segment of IVC was divided into 16 areas, consisting of four rows and four columns, which were used for recording sites of the openings of hepatic vein.

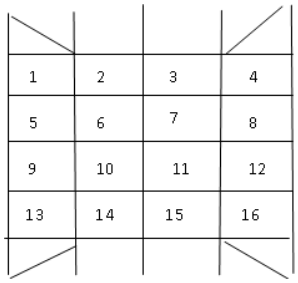

Figure 1: Division of the retro hepatic segment of IVC into 16 areas

Number of ostia venae hepaticae was noted. Out of 16 areas, openings in area 1, 2, 3, 4 were classified as superior openings; openings in areas from 5-16 were classified as inferior openings. On the basis of measurement of the widest diameter, the openings were classified as Large sized openings (wider diameter 1cm and >1cm), medium sized openings (wider diameter 0.5-1cm), Small sized openings (wider diameter <0.5cm).

How to site this article: D Malar. A study of retrohepatic segment of inferior vena cava and hepatic vein openings. *International Journal of Recent Trends in Science and Technology* November 2015; 17(1): 47-49 http://www.statperson.com (accessed 06 November 2015).

RESULT

The average length of the retrohepatic segment of inferior vena cava was 7.4 cms, the range being 5 to 9 cms. The Inferior vena cava was totally encircled by pons hepatis in 2 cases (6.5%). In 30 livers from the adult cadavers, altogether 322 ostia venae hepaticae were observed. An average of 10.7 Ostia was observed per liver. There were 63 large openings (19.56%), 66 medium sized openings (20.49%), and 193 small sized openings (59.93%).In the superior area (1-4) there were 53 large openings, 12 medium sized openings, and 11 small sized openings. In the Inferior area there were 10 large openings, 55medium sized openings and 182 small openings. The superior large openings were 53 (16.5%) and the inferior large openings were 8 (2.4%). The wider diameter of Right hepatic vein (RHV) - 2cm, Middle hepatic vein (MHV) and Left hepatic vein (LHV)-1.2cm, Joined LHV and MHV-1.9cms.The diameter of Inferior large opening (ILO) was 1.5 and medium sized openings (MO) was 0.9cms

Table 1: Location and number of hepatic venous openings

	SLO				ILO				MO				SO			
Present study	8	21	20	4					3	3	4	2	3	2	1	5
					3				1	6	3	4	14	28	9	10
							2	1	3	13	3	4	5	28	19	12
							2	2	-	2	8	7	5	19	24	9

In the present study, we observed different combinations of right, left and middle hepatic veins**.** The right (60%), left (20%) and middle hepatic veins (20%) opened separately into the inferior vena cava. Middle hepatic and left hepatic vein join to form a short trunk in 60% cases. The right, left and middle hepatic veins join to form a single large opening in 16.7% cases. Among the inferior large openings, right hepatic vein openings was 23.3%,followed by caudate veins 10% and a single large opening 3.3%.

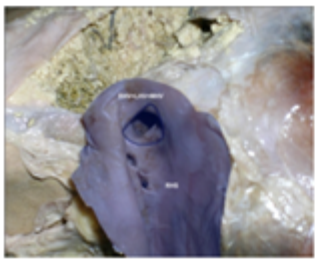

Figure 1: luminal aspect of RHS of IVC showing a single superior large opening. RHV, MHV and LHV form a common trunk
Figure 2: Specimen showing 2 SLO LHV with MHV forms common trunk.RHV drains separately
Figure 3: Specimen showing 3 superior large openings. RHV, MHV and LHV drain separately into IVC

DISCUSSION

In the present study the average length of the retrohepatic segment of inferior vena cava was 7.4 cms, the range being 5 to 9 cms. The Inferior vena cava was totally encircled by pons hepatis in 2 cases (6.5%) similar to the value found by other authors[4]. Altogether 322 hepatic vein openings were observed in 30 livers. The large openings were right hepatic, left hepatic and middle hepatic veins. Right hepatic vein opened both in the superior and inferior area of the retrohepatic segment[2,4,5]. The superior and inferior large openings are of great clinical significance during hepatic pressure measurement and in liver surgery[2]. In the present study the combination of patterns of drainage of hepatic veins into inferior vena cava showed variations. Left hepatic vein, middle hepatic vein and right hepatic vein had individual ostia in the superior area (20%).In 16.7% left hepatic, middle hepatic and right hepatic veins formed short common trunk which drained into inferior vena cava. The other pattern of drainage observed was left hepatic vein along with middle hepatic vein forming a common trunk; right hepatic vein draining individually, this was observed in 60%[2,4,6]. The knowledge of various types the hepatic venous drainage pattern is important in preoperative planning of live donor liver transplantation[7] The wider diameter of RHV- 2cm, MHV and LHV-1.2cm, Joined LHV and MHV-1.9 cms. The diameter of ILO was 1.5 and MO was 0.9cms. The diameter of Right hepatic vein was higher than the combined diameter of the left hepatic and middle hepatic vein[4]. The anatomical knowledge of large hepatic veins is important in liver resection[8]. The medium sized and small openings have gained great

importance in caudate lobectomy for bile duct cancer and split liver[9]. The openings of hepatic veins into retrohepatic segment of Inferior vena cava are not only structures playing a part in controlling the hepatic circulation, but are also of importance during catheterization, to determine the hepatic and sinusoidal pressure and selective hepatic venography. Hepatic venous blood sampling is done quite frequently, to collect blood from segments for biochemical analysis, cytological studies and to confirm lesions in particular segment. Moreover they are also relevant during resection of parts of diseased liver and during the removal of a long segment of Inferior vena cava at the time of liver transplantation. This segment of Inferior vena cava is invariably approached by surgeons while operating in the donors as well as in recipients. Hence the knowledge is invaluable.

CONCLUSION

Although operative techniques have become standardized, the more serious complication is venous hemorrhage during and after surgery. Hence a prior knowledge of the possible anatomical variations can avert inadvertent traumas and unforeseen bleeding to a greater extent. The surgeons should systematically consider each venous anomaly or variation as a part of review of the CT scan prior to surgery. The presence or absence of variations may help in modifying the criteria adopted for the management by the surgeons.

ACKNOWLEDGEMENT

I am grateful to Dr. G. Saraswathi for her unfailing support and professional insight in the preparation of this article. I also thank the staff members of department of anatomy for assisting in the study.

REFERENCE

1. Williams PL, Bannster LH, Martin, Berry, *et al*. Cardiovascular system. Grey's Anatomy.38th edn. London: Churchill living stone, 1996; 1600-1602.
2. Camargo AMSR, Teixeira GG, Ortale JR. Anatomy of ostia venae hepaticae and retrohepatic segment of Inferior vena cava. J.Anat 1995 May; 188: 59-64.
3. Sagoo MG, Agnihotri G. The Retrohepatic segment of inferior vena cava and the ostia venae hepaticae in a northwest Indian population. Braz.J.Morphhol.Sci., 2010 Jan;26(3-4):141-144.
4. Change RWH, Shan-Quan S, Yen WWC. An applied anatomical study of the ostia venae hepaticae and retrohepatic segment of inferior vena cava .J.Anat, 1989; 41-47.
5. Sahni D, Harjeet, Chawla YK, Indarjit. Gross anatomy of the retrohepatic segment of the inferior vena cava in northwest Indians. Indian J Med.Res., 2006 July; 124:63-70.
6. Nakamura S, Tsuhiharu T. Surgical anatomy of hepatic veins and the inferior vena cava. Surgery, Gynecology and Obstetrics. 1981Jan; 152:43-50.
7. Radtke A, Schroeder T, Sotiropoulos GC, Molmenti E, Schenk A , Paul A *et al*.Anatomical and physiological classification of hepatic vein dominance applied to liver transplantation.Eur J Med Res,2005 May; 10;187-194.
8. Singh D, Agnihothri G, Singh S, Singh R. Patterns of tributaries of major hepatic veins by dissection and radiology. Anatomy journal of Africa, 2012 Sep; 1(1):17-19.
9. Yu HC, Lee H, Jin ZW, Cho BH. Anatomical study of the ostia venae hepaticae in the Korean cadaver. Journal of korean surgical society, 2003; 64(4):321-326.

Source of Support: None Declared
Conflict of Interest: None Declared