Original Article

Large Hurthle cell adenoma in a 50 yrs old case of multinodular goitre

Y Harshita*, B Gowtham Reddy*, Md. Jawed Akther**

*Postgraduate, **Professor, Department of General Surgery, Mamata Medical College, Khammam- 507002, Telangana, INDIA.
Email: dr_mdjawedakther@yahoo.com

Abstract

Hurthle cell tumours of thyroid are rare neoplasms accounting for less than 5% of all thyroid tumours. We present the case of an 80 year old male with large multinodular goiter in euthyroid state for past 50 years. Initial FNAC impression was papillary carcinoma of thyroid with hurthle cell change. Right hemithyroidectomy was performed and histopathological examination of resected specimen showed features of Hurthle cell adenoma without capsular & vascular invasion. Post operative period was uneventful and patient was discharged with an advice for regular follow up.

Key Word: Multi Nodular Goitre, 50yrs, Large Hurthle cell adenoma.

Address for Correspondence:
Dr. Md. Jawed Akther, Professor, Department of General surgery, Mamata Medical College, Khammam- 507002, Telangana, INDIA.
Email: dr_mdjawedakther@yahoo.com
Received Date: 25/09/2015 Revised Date: 02/11/2015 Accepted Date: 28/11/2015

Access this article online	
Quick Response Code:	Website: www.statperson.com
	DOI: 10 December 2015

INTRODUCTION

An 80 year old male patient presented to the surgical OPD with complaints of swelling in front of the neck for the past 50 years. Swelling initially small in size, gradually progressed with a recent rapid increase in size, associated with pain, dysphagia, odynophagia and loss of appetite for 1month. Examination of the neck revealed a multi nodular goiter with a 7x5cm swelling in the right. lobe and 3x2 cm swelling in the isthmus. Swelling was firm in consistency, with restricted mobility in vertical direction and associated tracheal deviation to left. No regional lymph nodes were found (Fig.1).

Blood picture was normal. Ultrasonography of neck revealed enlarged right lobe thyroid gland measuring 95x45x65mm as lobulated mixed echoic mass. Major neck vessels were normal without any cervical nodes. USG abdomen, Barium swallow, indirect laryngoscopy, Thyroid function tests were within normal limit. Initial FNAC showed features suggestive of papillary carcinoma of thyroid with hurthle cell change. Repeat FNAC showed scanty cellularity with abundant areas of only necrosis and no specific pathology was noted (Fig.2). Right hemi thyroidectomy was performed under general anaesthesia. Intra operative diagnosis was Multinodular goitre with chronic thyroid abscess (Fig.3). Specimen was sent for histopathological examination (Fig.4).

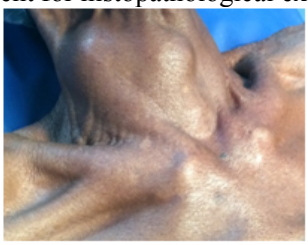

Figure 1: MNG rt. lobe & isthmus

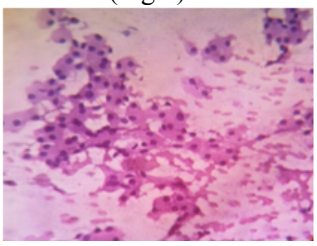

Figure 2: FNAC - scanty cellularity with areas of necrosis

How to site this article: Y Harshita, B Gowtham Reddy, Md. Jawed Akther. Large Hurthle cell adenoma in a 50 yrs old case of multinodular goitre. *International Journal of Recent Trends in Science and Technology.* December 2015; 17(2): 76-78. http://www.statperson.com (accessed 12 December 2015).

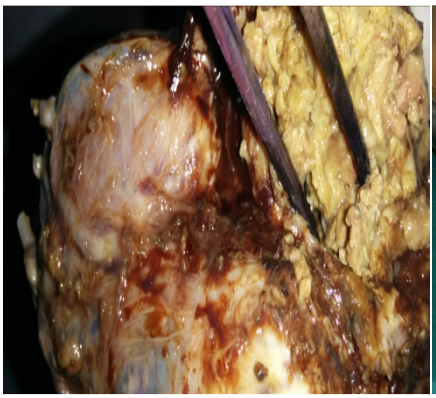

Figure 3: MNG with chronic thyroid abscess

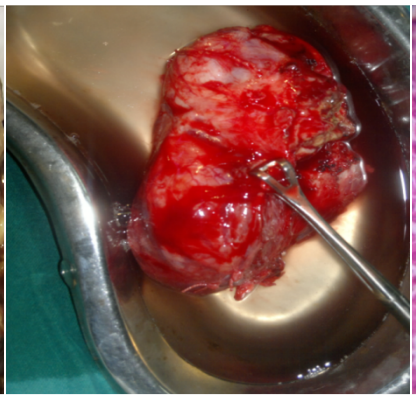

Figure 4: Rt. hemithyroidectomy specimen

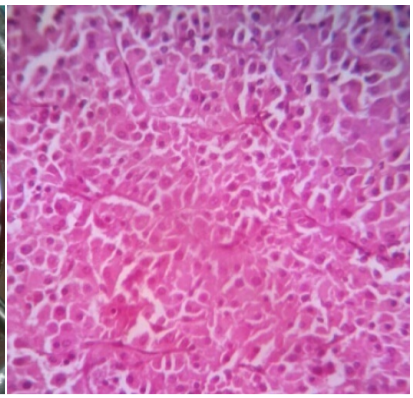

Figure 5: H/P Hurthle cell adenoma

Histopathological examination of resected specimen gave the impression of multinodular goitre measuring 9x4x6cm with cut section showing nodules of varying sizes, largest measuring 4x4cm with large area of necrosis and a calcified focus on gross examination (Fig.3, Fig.4). Microscopic examination showed features of Hurthle cell tumour of uncertain malignant potential with areas of massive necrosis without capsular or vascular invasion or any evidence of papillary carcinoma (Fig.5).

DISCUSSION

Hurthle cells are also called oxyphil cells because they are composed predominantly of thyroglobulin producing, mitochondria rich thyroid epithelial cells which confer the granular, pink cytoplasm. These tumors are rare and Hurthle cell neoplasms represent less than 5% of all thyroid tumours[1]. Hurthle cells, apart from forming thyroid neoplasms, as in this patient, are associated with benign thyroid conditions like goitres and thyroiditis where they represent oncocytic metaplastic changes. Majority of the tumours of Hurthle cells are benign, as seen in this patient, and are called Hurthle Cell Adenomas. However, many are malignant (up to 40%) and are called Hurthle cell carcinomas (HCCs). Hurthle cell tumours are interesting phenomena, not only because of the enduring debate about the true nature but also because HCCs are particularly aggressive; thereby making more vital, the task of differentiating the HCAs from the carcinomas[4]. This differentiation impacts the operative intervention since majority of surgeons recommend thyroid lobectomy for HCAs while advocating total thyroidectomy for HCCs[5]. Several authors have reported tumours initially diagnosed as HCAs which later recurred or metastasized[3].

The scenario of a multifocal HCA is not supported by antecedents in literature. In a series by Chen *et al*., no patient with HCA had bilateral disease[5]. However, they found on the other hand that 16% of those with HCC had bilateral foci which required total thyroidectomy. One patient with HCA in his series had contralateral tumour which turned out to be follicular variant of papillary thyroid cancer.

In this case, prior to surgery, an attempt was made to establish the character of the tumour by FNAC. While several studies have shown that FNAC reliably recognizes Hurthle cell neoplasms, it cannot differentiate adenoma from carcinoma with certainty[6]. Tumour size has been suggested by some workers to be predictive of malignancy[3]. In this case, the tumour was above the accepted 4 cm threshold yet had histological features consistent with benign disease. Some have suggested that tumors of this type should be placed in an intermediate category[7]; this would imply some latent malignant potential. It is however more plausible that a long tumor growth period and late presentation allowed this adenoma to attain a large size without any features of HCCs.

CONCLUSION

Hurthle cell neoplasms are rare tumours. Their biology is confounding and behaviour is unpredictable. Tumour size of Hurthle cell neoplasm is an important preoperative index for predicting benignity. This index impacts on the choice doing either a total or hemithyroidectomy. While HCCs grow to comparatively larger sizes, late presentation however, may allow for large size in adenomas and may compound the paradigm of tumour size as predictor of malignancy. More studies that include diligent follow up of all thyroid specimen to histology are however required. Imaging modalities like ultrasound and plain radiography show nonspecific features and are thus unhelpful in preoperative distinction between HCA and carcinoma.

REFERENCES

1. Stojadinovic A, Hoos A, Ghossein RA, Urist MJ, Leung DH, Spiro RH, et al. Hurthle cell carcinoma: A 60 year experience. Ann Surg Oncol 2002;9:197-203.

2. Chen H, Udelsman R. Hurthle cell adenoma and carcinoma. In: Clark OH, Duh QY, editors. Textbook of Endocrine Surgery. Philadelphia: WB Saunders;1997.
3. Thompson NW, Dunn EL, Batsakis JG, Nishiyama RH. Hurthle cell lesions of the thyroid gland. Surg Gynecol Obstet 1974;139:555-60.
4. Paphavasit A, Thompson GB, Hay ID, Grant CS, Van Heerden JA, Ilstrup DM,et al. Follicular and Hurthle cell thyroid neoplasms: Is frozen section evaluation worthwhile? Arch Surg 1997;132:674-8.
5. Chen HY, Benjamin LB, Chen MF. Hurthle cell tumor. Int Surg 1996;81:168-70.
6. Azadian A, Rosen IB, Walfish PG, Asa SL. Management considerations in Hurthle cell carcinoma. Surgery 1995;118:711-5.
7. Arganini M, Behar R, Wu TC, Straus F 2nd, McCormick M, DeGroot LJ, et al. Hurthle cell tumors: A twenty five year experience. Surgery 1986;100:1108-15.

Source of Support: None Declared
Conflict of Interest: None Declared