Case Report

A rare case of unruptured nonviable pregnancy in the rudimentary horn of unicornuate uterus: A case report

Dulewad S S[1*], Sirsam S S[2], Pampatwar A D[3], Tayde P M[4]

[1,3]Assistant Professor, [2]Associate Professor, [4]Resident, Department of Obstetrics and Gynaecology, Dr.S. C. G. M. College, Nanded, Maharashtra, INDIA.

Email: sdulewad@gmail.com

Abstract

Pregnancy in a non-communicating rudimentary horn is an extremely rare form of ectopic gestation. The rudimentary horn may or may not communicate with the uterine cavity with the majority of cases being non-communicating. The patient exhibits features of acute abdomen and carries a high risk of maternal death. we reported a case of unruptured nonviable pregnancy of 11 weeks of gestational age presented with 3 months of amenorrhoea ,pain in abdomen. we done laparatomy by removing rudimentary horn. Even modern scans remain elusive whereas laparatomy remains the confirmatory procedure for the diagnosis. Because of the varied muscular constitution in the thickness and distensibility of the wall of the rudimentary horn, pregnancy is accommodated for a variable period.

Keywords: Unicornuate uterus, noncommunicating rudimentary horn, pregnancy.

***Address for Correspondence:**

Dr. Dulewad S S, Assistant Professor, Department of Obstetrics and Gynaecology, Dr. S. C. G. M. College, Nanded, Maharashtra, INDIA.

Email: sdulewad@gmail.com

Received Date: 02/06/2015 Revised Date: 20/07/2015 Accepted Date: 31/08/2015

Access this article online	
Quick Response Code:	Website: www.statperson.com
	DOI: 16 February 2016

INTRODUCTION

Pregnancy in a noncommunicating rudimentary horn of a unicornuate uterus is rare.1 The incidence varies between 1/76,000-1/1,50,000 pregnancies. Pregnancy occurs following transperitoneal migration of sperms or zygote. Variable thickness of rudimentary horn musculature, dysfunctional endometrium and poor distensibility of the myometrium lead to rupture of the rudimentary horn. This complication is usually seen in the second trimester, resulting in hemoperitoneum and hemorrhagic shock. We report a case ofunrupturednon viable pregnancyin noncommunicating rudimentary horn with unicornuate uterus at 11 weeks gestational age 1.

CASE REPORT

The 25-year-old, primigravida mother was referred to our. Hospital with pain in abdomen. There was one episode of fever, 2 days prior to the admission associated with pain in abdomen, which was not associated with the leaking and bleeding per vagina.. At presentation, she looked well, with a pulse rate of 88bpm and a BP of 120/80 mm of Hg. Her height was 152 cm and her weight was 63 kg respectively. Her uterine height corresponded to 18-20 weeks. we sent patient for ultrasonography. Ultrasonography showed a bicornuate uterus with non viable gestation in the left horn, which corresponded to 11 weeks of the gestational age and empty horn on the right side. Her Hb was 9g/dl. She and her realatives were made aware about the condition, counselled and patient was prepared for a caesarean section. The findings at surgery were: a slightly bulky uterus; there was pregnancy in the left rudimentary horn of the uterus which was attached to the cornu of the uterus. The cavity of the horn did not communicate with the uterine cavity. The left fallopian tube was of normal length and it was attached to the rudimentary horn. The left ovary was normal and it was attached by its ligament to the rudimentary horn. The right tube and the ovary were normal. Intra-operative photograph showing the anterior view of the uterus with the rudimentary horn attached to its left superior border. The left tube, the ovarian ligament and the round ligament were clamped cut and transfixed. The rudimentary horn was excised and the foetus was

How to site this article: Dulewad S S, Sirsam S S, Pampatwar A D, Tayde P M. A rare case of unruptured nonviable pregnancy in the rudimentary horn of unicornuate uterus: A case report. *International Journal of Recent Trends in Science and Technology*. February 2016; 18(1): 220-222. http://www.statperson.com (accessed 20 February 2016).

extracted from the horn. The mother's post-operative recovery was normal. She was discharged on the 7th post operative day and was given a 6 weeks follow-up appointment.

Figure 1: Showing pregnancy in non communicating horn of uterus

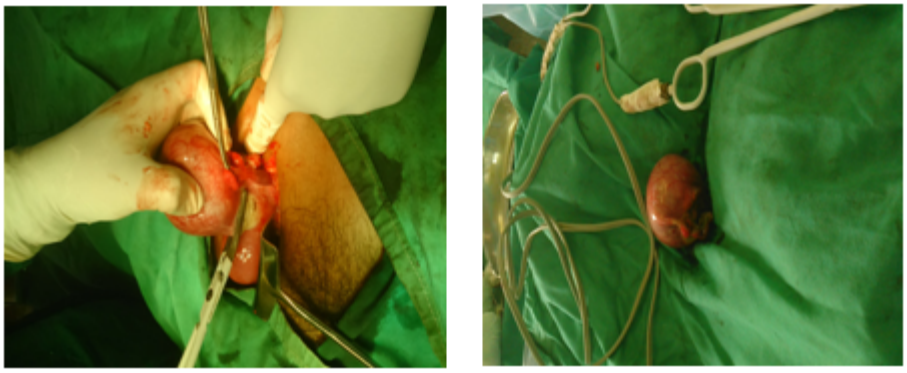

Figure 2 and 3: Showing removal of non communicating horn of uterus

Figure 4: Showing pregnancy in horn of uterus

DISCUSSION

Difficulty in diagnosis of RHP during early pregnancy is quite common as there are no definite signs to distinguish this abnormal implantation from normal intrauterine pregnancy. sonographic evaluation is very important. Accurate diagnosis is possible only after laparotomy. Magnetic resonance imaging may have a major contribution to the diagnostic evaluation when pregnancy in a rudimentary horn is suspected and if ultrasonography is inconclusive. The management of rudimentary horn pregnancy is laparotomy and surgical removal of the pregnant horn to prevent rupture and recurrences. The fallopian tube on the side of the rudimentary horn must be removed in order to avoid tubal pregnancies. There are instances of modern techniques for management of rudimentary horn pregnancy like laparoscopic excision of rudimentary horns. Medical management with methotrexate provides another treatment option and it can be a useful adjunct to surgical intervention, provided beta-hCG level is not more than 6000 mIU/ml.[2]

CONCLUSION

A rudimentary horn with a unicornuate uterus results from the failure of the complete development of one of the mullerian ducts and incomplete fusion with the contralateral side. Pregnancy in a non-communicating rudimentary horn
occurs through the transperitoneal migration of the sperm or the fertilized ovum . It is associated with intrauterine growth retardation, intraperitoneal haemorrhage and uterine rupture[1]. Pregnancy in a rudimentary horn carries a grave risk to the mother. There is a need for an increased awareness on this rare condition and to have a high index of suspicion, especially in developing countries where the possibility of an early detection before the rupture is unlikely[3]. Early diagnosis and early interventions will avoid maternal morbidity and mortality. These patients are advised to be screened for urinary tract anomalies with preoperative intravenous pyelography. A complete USG examination should be performed on the aspect of the pregnancy and the pelvic anatomy. If USG remains inconclusive, the use of magnetic resonance imaging is suggested. It is easy to miss this condition both clinically and radiologically. Above case highlights the need for high index of suspicion to diagnose rudimentary horn pregnancy.[4] It is recommended by most that immediate surgery be performed whenever a diagnosis of pregnancy in a rudimentary horn is made even if unruptured[5] someone truly said" Stitch in time saves nine".

REFERENCES

1. Shukla P, Bhargava M, Shukla P. Rupture of Term Noncommunicating Rudimentary Horn of Uterus. Indian Journal of Clinical Practice. 2013;23(11):745-747.
2. P N, S P, A J, NM M. Unruptured Pregnancy In Rudimentary Horn Of Unicornuate Uterus. JPGO. 2015;2(3).
3. Dhananjaya B, Shobha U, Nanda S, Nandagopal K, Anitha M. A Rare Case of Pregnancy in the Rudimentary Horn of Unicornuate Uterus (on Table Diagnosis) Which had a Successful Outcome: A Case Report. Journal of Clinical and Diagnostic Research. 2011;5(7):1461-1463.
4. I U. Non-communicating Rudimentary Uterine Horn Pregnancy. J Nepal Med Assoc. 2011;51(184):199-202.
5. Okonta P, Abedi H, Ajuyah C, Omo-Aghoja L. Pregnancy in a noncommunicating rudimentary horn of a unicornuate uterus: a case report. Cases Journal. 2009;2:6624.

Source of Support: None Declared
Conflict of Interest: None Declared