Original Article

Developmental dysplasia of hip - Sonographic findings

Bhaskar Raj[1], Gopinath Menon[2], Jeyaanth P V[3], P M Venkata Sai[4*]

{[1]Associate Professor, [3]Intern, [4]Professor and HOD, Department of Radiology and Imaging Sciences}, {[2]Professor, Department of Orthopedic surgery}, Sri Ramachandra Medical College, Sri Ramachandra University, Porur, Chennai – 600116, Tamil Nadu, INDIA.
Email: venkatasai_25@yahoo.com

Abstract

High resolution ultrasound has gained increasing popularity over conventional x- rays as an aid in the diagnosis of developmental dysplasia of hip. Technical advances have improved image quality. This study was conducted to evaluate the accuracy and reliability of high resolution ultrasound in diagnosing congenital developmental dysplasia. Seven hundred neonatal hips (both sides) were screened for developmental dysplasia using high end ultrasound machines with a 10 – 12 Mhz high frequency linear array transducer. High resolution ultrasound was found to be very useful in detecting developmental dysplasia of hip at very early stages thus preventing deformity of hips.

Keywords: Developmental dysplasia, high resolution ultrasound, neonatal hip.

***Address for Correspondence:**
Dr. P. M. Venkata Sai, Professor and HOD, Department of Radiology and imaging sciences, SRMC&RI, (SRU), Porur ,Chennai-600 116, Tamil Nadu, INDIA.
Email: venkatasai_25@yahoo.com

Received Date: 10/01/2016 Revised Date: 20/02/2016 Accepted Date: 14/03/2016

Access this article online	
Quick Response Code:	Website: www.statperson.com
	DOI: 16 March 2016

INTRODUCTION

Developmental dysplasia of hip is a congenital condition which is seen in 1 in 1000 babies born with dislocated hip or hip instability. 10 in 10,000 neonates born with clinically apparent hip subluxation or dysplasia. DDH is predominantly seen in first born child with predilection to female sex. The prevalence of DDH in females born in breech position has been estimated to be as high as 1 case in 15 persons in some studies. (Ramsey PL, 1976) The risk of subsequent members of a family having DDH when one family member had DDH was 36% when there was one affected parent and child, 12% when there was one affected parent and no affected children, and 6% when both parents were normal and had one affected child with DDH (Wynne-Davies, 1970) Oligohyadramnios and breech (because of sustained hamstring forces) are also etiological factors for developmental dysplasia of hip. Other musculoskeletal disorders of intrauterine malpositioning or crowding, such as metatarsus adductus and torticollis, have been reported to be associated with DDH. (Kumar SJ, 1982)The neonate hip is a difficult joint to image with standard radiographic positioning because the hip is composed primarily of cartilage. Moreover positioning the neonate for standard radiographs is also difficult. High resolution ultrasound shows the soft tissue anatomy of the hip and relationship of the acetabulum with the femoral head as well. R. Graf pioneered the use of high resolution ultrasound in evaluation of the infant hip. He recommended a lateral ultrasound imaging with the transducer placed over the greater trochanter. The transducer has to be placed perpendicular to the greater trochanter to visualize the acetabular cavity, unossified femoral head cartilage within the acetabular cavity and chondrosseous border. The hyaline articular cartilage of the hip has little echo, adjacent muscles has moderate echo and fibrocartilaginous labrum, chondrosseous border has strong echo. In this study, role of high resolution ultrasound in early detection of developmental dysplasia is stressed upon.

MATERIALS AND METHODS

700 neonates underwent high resolution hip ultrasonography study on both sides. The inclusion

How to site this article: Bhaskar Raj, Gopinath Menon, Jeyaanth P V, P M Venkata Sai. Developmental dysplasia of hip - Sonographic findings. *International Journal of Recent Trends in Science and Technology*. March 2016; 18(2): 354-357. http://www.statperson.com (accessed 18 March 2016).

criteria were first born, breech, family history of developmental dysplasia, knee or ankle congenital abnormalities and click heard on clinical examination. The exclusion criteria were proximal femoral deficiency and phocomelia. All clinical examinations were carried out by the authors including Barlow and Otholani's test. High resolution ultrasound examination performed at 2 days of neonatal period. The equipment used were GE Logic P5 with paediatric hip angle measuring soft ware. Prof. R. Graf classification is followed. In its simplest form, class I hips are normal. Class II hips are either immature or somewhat abnormal. Class III hips are subluxated and Class IV hips are dislocated. Neonatal hip that were stable (normal) on initial examination were reexamined clinically and with high resolution ultrasound at 2 weeks and 2months of age, while those with unstable (immature or somewhat abnormal)hips were reexamined at 2 weeks,2 months and 6 months of age. Total seven hundred neonates both hips were examined in mid aceatabular region on both sides.

Findings

Anatomical land marks to be identified before a hip sonogram are acetabular cavity, acetabular labrum, bony ilium, femoral head and chondro-osseous junction. In developmental dysplasia, femoral head slides out of the socket in the superior-posterior direction leads to deformity.

Class I: Normal. The cartilaginous acetabular roof encloses the femoral head holding it firmly in the socket.

Class II: Immature or somewhat normal .Bony acetabular roof is deficiently developed. The bony rim is rounded and the cartilaginous portion of the acetabular roof seems proportionately larger.

Class III: Subluxation. The bony socket is poorly developed. The bony rim is flattened and the cartilaginous acetabular roof is displaced upwards. Femoral head will be dislocated. Perichondrium slops cranially it is class III.

Class IV: Dislocation. The cartilaginous acetabular roof is pushed downwards by the displaced femoral head towards the original acetabulum. Perichondrium is horizontal or dips caudally and then rises towards the bony acetabular roof it is class IV. Two angles emerge from the measurement lines. Alpha and beta angles are not dependent on either the position of the baby or projection. Bony alpha angle quantifies the bony actabulum and cartilaginous beta angle quantifies the cartilaginous acetabular roof. A smaller alpha angle indicates a shallower bony acetabulum. A smaller beta angle indicates a better cartilaginous acetabulum. As the femoral head dislocated, the alpha angle decreases and the beta angle increases.

Table 1: Based on sonographic angles of the hip, Graf Classification system of DDH

Class	Alpha angle	Beta angle	Description
I	> 60	< 55	Normal
II	43 – 59	54 – 77	Delayed ossification
III	< 43	> 77	Everted labrum Lateralisation
IV	Unmeasurable	Unmeasurable	Dislocated

I: Normal. Nofurther evaluation.
II: Monitored and follow up
III &IV: Must be treated

Ultrasonographic Appearances

Bone is highly reflective seen as a bright echo with an acoustic shadow behind it. Hyaline cartilage will appear as hypo echoic / anechoic and the sinusoidal vessels may be seen as faint serpiginous echoes. Hyaline cartilage is found in femoral head and cartilaginous portion of the acetabular roof. The labrum is the most peripheral part of the acetabulum, the fibrocartilaginous labrum is highly echogenic on ultrasound. The labrum is always in contact with the femoral head. Chondrosseous border of femoral head is not in contact with the labrum highly suggestive of developmental dysplasia of hip. The bony alpha angle which quantifies the bony socket and the cartilage beta angle which quantifies the cartilaginous acetabular roof.

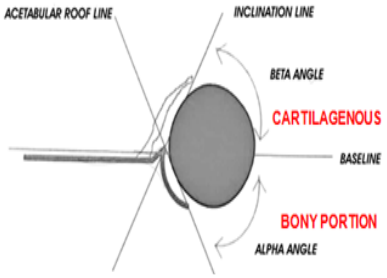

Figure 1a

Base Line: Along the straight lateral margin of ilium.

Inclination Line: Connects osseous convexity to labrum.

Roof Line: Connects lower edge of acetabular roof medial to osseous convexity.

αAngle: Angle between the acetabular roof line and baseline

Figure 1 b

Figure 2a

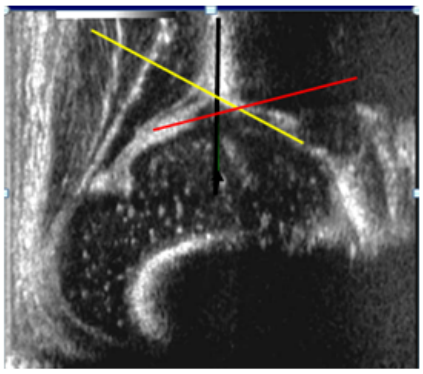

Figure 2 b

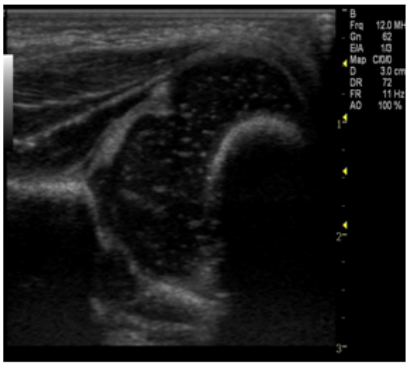

Figure 3a: TYPE I – NORMAL α - 600 β - 55°

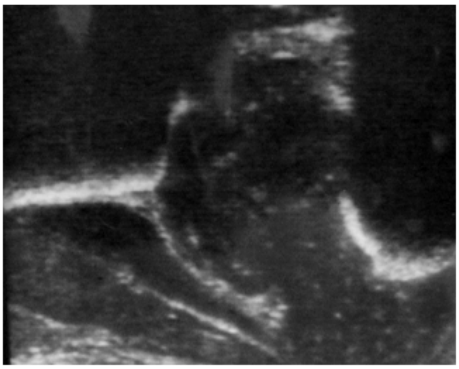

Figure 3b: Type Ii A – Physiological Immaturity A – 50 – 60o B - 55 - 77o Less Than 3 Months Old

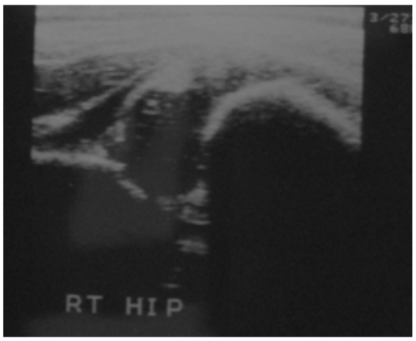

Figure 3c: Type Ii B – Delayed Ossification A – 50 – 600B - 55 – 77o More Than 3 Months Old

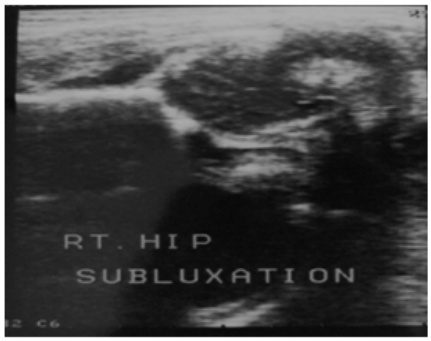

Figure 3d: Type Ii C – Subluxation A – 43 -49o Beta - 55 - 770

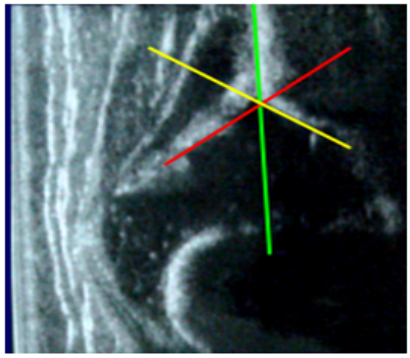

Figure 3e: Type Iii – Dislocation A – Less Than 430 B - More Than 770

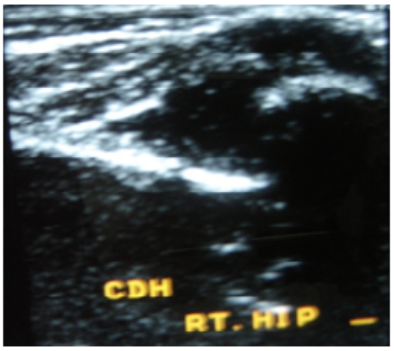

Figure 3f: Type Iv –High Dislocation A And Beta Angle Not Measurable

DISCUSSION

The neonatal hip is a difficult joint to image with proper positioning by standard radiographic techniques because the hip joint is primarily composed of cartilage in the neonatal period. High resolution ultrasound shows the relationship of femoral head and acetabulum very well in mid coronal plane. Most of the current research supports the concept that high resolution ultrasound is a more sensitive indicator of abnormality of the infant hip than conventional radiography. The study by F.Nili et al, suggest that ultrasonographic screening does pick up clinically silent hips without increasing the rate of treatment for minor abnormalities that would resolve spontaneously **(Nili, 2005)**. Graf pioneered the use of ultrasonography in the evaluation of the infant hip. He emphasizes that the probe should be perpendicular to the acetabulum and cut in the centre of the acetabulum. In our study also linear transducer kept perpendicularly and in mid coronal plane both hip joints are evaluated. A strict standardized technique for investigation of infant hip and interpretation of the sonograms has made infant hip ultrasound reproducible, reliable and independent of examiner skill and experience. Ultrasound characteristics of the different tissues of the infant hip joint are studied in mid coronal plane.

CONCLUSION

High resolution ultrasound is a valuable adjunct to the detection of neonatal hip abnormalities. It is also very useful in detecting early treatment failures. It is important to note that a negative result on ultrasonography does not preclude later abnormalities.

REFERENCES

1. Congenital dislocation of the hip. Use of the Pavlik harness in the child during the first six months of life. Ramsey PL, Lasser S, MacEwen GD. 58(7):1000-4, Oct 1976, J Bone Joint Surg Am.
2. Acetabular dysplasia and familial joint laxity: two etiological factors in congenital dislocation of the hip. A review of 589 patients and their families. Wynne-Davies, R. 4, 1970, Journal of Bone and Joint Surgery, British, Vol. 52, pp. 704–716.
3. The incidence of hip dysplasia with metatarsus adductus. Kumar SJ, MacEwen GD. 164, April 1982, Clin Orthop Relat Res, pp. 234-5.
4. Detecting Hip Joint dysplasia in High risk group infants. Nili, F et. al. 2, September 2005, MJIRC, Vol. 8.
5. Hip utrasonography in infants and children. Karnik A. Indian J Radiol Imaging 2007;17:280-9
6. The use of sonography in screening for developmental dysplasia of the hip. J S Donaldson et. al. American Journal of Roentgenology. 1994; 162: 399-400.

Source of Support: None Declared
Conflict of Interest: None Declared