Original Article

A study of rhinolith as detected by ct scan paranasal air sinuses at tertiary health care centre

Anil G Joshi

Professor and HOD, Department of Radio-Diagnosis, Bharati Vidyapeeth and Deemed University, Medical College and Hospital, Sangli.
Email: dranilgjoshi@gmail.com

Abstract

Introduction: Rhinoliths are calcareous concretions around calcinated intranasal foreign bodies within the nasal cavity. They are commonly seen in the anterior part of the nasal cavity. The incidence of adult rhinolith is very low. Rhinoliths are generally single, exogenous or endogenous, unilateral, and asymptomatic. **Aims and Objectives:** To Study Rhinolith as Detected by CT Scan Paranasal Air Sinuses at tertiary health care center. **Methodology**: It was a retrospective study of 2860 CT scans of paranasal sinuses during the period of June 2013 to August 2015 was done to detect Rhinoliths. The observations of CT scan were made and the results were statistically analyzed. **Result:** The majority of the Patients were from 30-40 age group i.e. 50.00% followed by 20-30-33.33% and 40+- 16.67%. Majority of the Patients were Female i.e. 66.67% followed by Male 33.33%. **Conclusion:** Rhinoliths are quite rare cases of the nose, which may show clinical and radiological similarities with each other and benign and malignant diseases of the region so in the nose diseases clinical suspicion of a rhinolith should always be considered, in order to lead to the right diagnosis.
Keywords: Rhinolith, CT Scan Paranasal Air Sinuses.

Address for Correspondence:
Dr. Anil G Joshi, Professor and HOD, Department of Radio-Diagnosis, Bharati Vidyapeeth and Deemed University, Medical College and Hospital, Sangli, 416 416, Maharashtra, INDIA.
Email: dranilgjoshi@gmail.com
Received Date: 16/03/2016 Revised Date: 14/04/2016 Accepted Date: 08/05/2016

Access this article online	
Quick Response Code:	Website: www.statperson.com
	DOI: 12 May 2016

INTRODUCTION

Rhinoliths are calcareous concretions around calcinatedintranasal foreign bodies within the nasal cavity. They are commonly seen in the anterior part of the nasal cavity. The incidence of adult rhinolith is very low. Rhinoliths are generally single, exogenousor endogenous, unilateral, and asymptomatic. Rhinoliths usually present in the third decade of life and rarely occur in children with females more commonly affected than male[3]. They are mixture of 90% inorganic material and 10% organic substances incorporated into the lesion from nasal secretions. Computerized tomography provides better images to evaluate this condition and its relationship with adjacent structures. The first recorded case of rhinolithiasis was reported by Barthdin in 1654. The most common site of rhinoliths is in the middle of the lower nasal duct and the majority of cases are unilateral. Rinolithiasis may be presented with no symptoms [2,3] for many years until the gradual growth of the rhinoliths leads to nasal obstruction, and may be often misdiagnosed as rhinitis or sinusitis. The symptomatic rhinolithiasis is characterized by nasal discharge, obstruction, epistaxis and erosion of the nasal septum and the medial wall of the maxillary sinus and perforations of the hard palate[2,5]. The rinolithiasis incidence reported in the literature is relatively rare. The most extensive study is of Polson *et al* in 1943 [6], in which 495 cases are reviewed. In this study, there is a predominance of females in sex, while age of onset ranges from 6 months to 86 years. Although rhinoliths can occur at any age, they are more common in children and young adults[4]. The mechanism of creation is believed to be the deposition of magnesium, iron and calcium and phosphorus around a core, which can be endogenous or exogenous origin[7,8]. The intrinsic nuclei include intranasal thick secretions, blood clots, epithelial debris, bone fractures of the visceral skull and ectopic teeth[9]. Exogenous nuclei, which are the most common, include foreign bodies placed in the nose, usually during

How to site this article: Anil G Joshi. A study of rhinolith as detected by ct scan paranasal air sinuses at tertiary health care centre. *International Journal of Recent Trends in Science and Technology* May 2016; 19(1): 73-76. http://www.statperson.com (accessed 14 May 2016).

childhood. The presence of foreign body leads to a local inflammatory reaction and the subsequent deposition of salts and minerals around the core[10, 11]. Other factors that appear to play a role in the formation of rhinolithsis nasal obstruction and nasal secretions due to acute and chronic rhinitis and paranasal sinusitis [5]. Rhinoliths are usually asymptomatic masses in the anterior half of the nasal cavity, showing a brownish-gray color and a coarse and crumbly texture. As they grow in size, symptoms of nasal obstruction and completeness are caused, such as seropurulentsecretion, usually unilateral, epistaxis, persistent sinusitis, headache, olfactory dysfunctions and epiphora[2,10]. Extension into the surrounding tissues may cause displacement and perforation of the nasal septum, perforation of the hard palate and thus oronasal or oromaxillary fistulas, and expansion into the maxillary sinuses[10,11]. In such cases, nasal malignancies should be excluded. In many patients, the diagnosis follows accidentally other radiological examinations[12]

AIMS AND OBJECTIVES

To Study Rhinolith as Detected by CT Scan Paranasal Air Sinuses at tertiary health care centre.

METHODS AND MATERIALS

The retrospective study of 2860 CT scans of paranasal sinuses during the period of June 2013 to August 2015 was done to detect Rhinoliths. 5 mm. thick direct coronal sections of paranasal sinuses were obtained on multislice, spiral CT scan and sections were analyzed in all axis. The detail history of all the patients was noted. The observations of CT scan were made and the results were statistically analyzed.

RESULT

There were six cases in our study these are:

CASE 1

A 36-year-old female presented with left nasal blockage for last one year. The symptom became gradually worsened. It was associated with intermittent nasal discharge. There was no history of pain, epistaxis, trauma or foreign body insertion in the nose. Computed tomography (CT) images showed a hyperdense oval shaped mass ranging 25 × 15 mm in size with a hypodense nucleus. The mass was situated in left middle and inferior turbinates extending anteriorly in the left nasal cavity. No evidence of sinus encroachment or osseous destructions was noticed (image no.1)

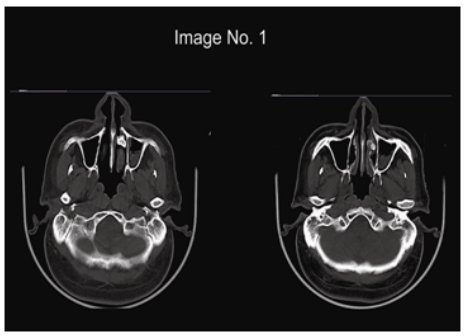

Figure 1:

CASE 2

A 32-year old male presented to the ENT Department of our hospital, with a history of chronic nasal obstruction. The patient admitted frequent episodes of purulent rhinorrhea, epistaxis and headache. The axial/coronal CT scan of the nasal cavity, obtained to exclude bony destruction, revealed a large, dense, space-consuming lesion measuring between one and a maximum of three cm in diameter located in the inferior and middle meatus on the left, and presenting fairly well defined margins. (image no.2).

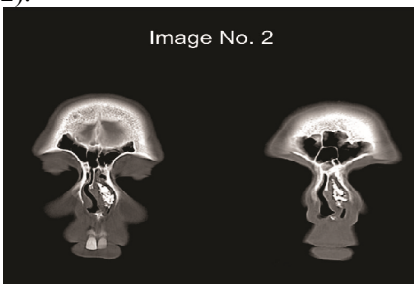

Figure 2:

CASE NO. 3

A 32 year old female presented with complains of prolonged runny nose with foul smell, and at times bloody nasal discharge for the last five years. There were no constitutional symptoms. There was no history of trauma, foreign body insertion or any systemic illness- The CT Scan showed a calcified lesion in left inferior turbinate (image no. 3).

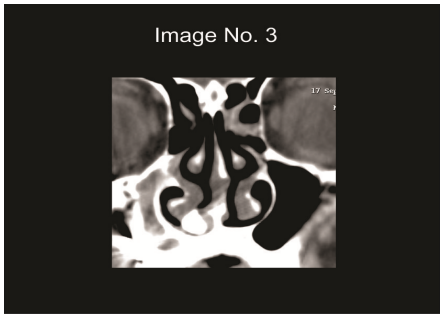

Figure 3:

CASE 4:

A 44 year old female presented with repeated attacks of sinusitis - CT scan revealed an irregular hyperdense calcified lesion extending from left maxillary sinus through ostium into the nasal cavity destroying adjacent bones of maxillary sinus wall (image no. 4)

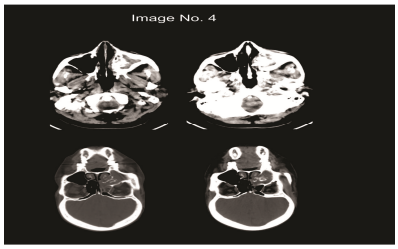

Figure 4:

CASE 5:

A 24 year old female presented with repeated attacks of nasal blockage - CT scan revealed an irregular hyperdense calcified lesion adjacent to inferior turbinate in the ostium of Rt. nasal cavity (image no. 5)

Figure 5:

CASE 6

A 28 year old male presented with headache and common cold - CT scan revealed an irregular hyperdense calcified lesion in Rt. nasal cavity adjacent to middle turbinate partially blocking nasal cavity (image no. 6)

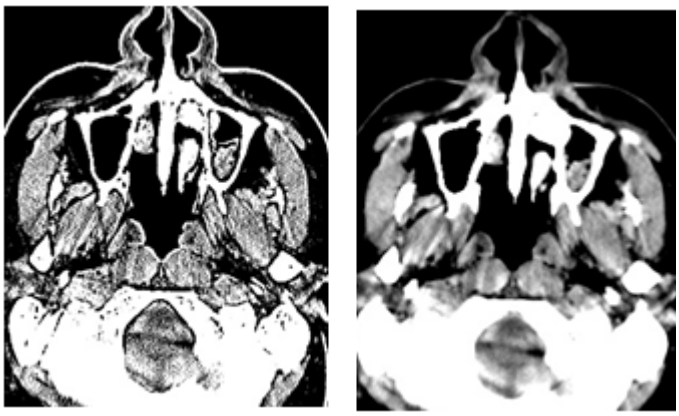

Figure 6:

Table 1: Age wise distribution of the Patients

Age	No.	Percentage
20-30	2	33.33%
30-40	3	50.00%
40+	1	16.67%
Total	**6**	**100.00%**

The majority of the Patients were from 30-40 age group i.e. 50.00% followed by 20-30-33.33% And 40+- 16.67%.

Table 2: Sex wise distribution of the Patients

Sex	No.	Percentage
Male	2	33.33%
Female	4	66.67%
Total	**6**	**100.00%**

Majority of the Patients were Female i.e. 66.67% followed by Male 33.33%.

DISCUSSION

Rhinolithiasis was first described by Bartholin in 1654. The rhinolith is a mineralized mass located inside the nasal cavity, resulting from total orpartial calcification of an intranasal foreign body [13]. The typical symptoms of rhinoliths include pain, unilateral nasal obstruction and epistaxis. Other symptoms include crusting, swelling of nose or face,anosmia, epiphora, ozena and headache[14] Complications consist of ipsilateral otitis media,bacterial or fungal sinusitis, septalperforation, palatal perforation, fistulous tract formation and recurrent dacryocystitis[14,15]. Rhinoliths are thought to be formed by the gradual accretion of calcium and mineral saltsaround an intranasal nidus. As the size of rhinoliths increases very slowly and they are relatively inert, they are initially symptomless and cause minor symptoms[16] CT has been used to determine the size and location of rhinoliths, as well as to identify associated sinusitis and complications. This advanced imaging method presents high sensitivity and specificity for identifying calcifications and foreign bodies, and can be applied most effectively for the diagnosis of rhinoliths. In addition, the advantage of this exam is the non-superimposition of adjacent structures, and calcifications in the head and neck can be differentiated from bone and normal cartilage.

CONCLUSION

Rhinoliths are quite rare cases of the nose, which may show clinical and radiological similarities with each other andbenign and malignant diseases of the region so in the nose diseases clinical suspicion of a rhinolith should always be considered, in order to lead to the right diagnosis.

REFERENCES

1. Orhan K, Kocyigit D, Kisnisci R. Rhinolithiasis: An uncommon entity of the nasal cavity. Oral Surg Oral Med Oral Pathol Oral RadiolEndod 2006; 101:e28-32.
2. Carder HM, Hiel JJ (1966) Asymptomaticrhinolith: a brief review of the literature and case report. Laryngoscope 76: 524-530.
3. Varley EWB (1964) Rhinolith: an incidental finding. Br J Oral Surg 2: 40-43.
4. Dib GC, Tangerina RP, Abreu CE, Santos RP, Gregorio LC. Rhinolithiasis as a cause of oronasal fistula. Rev Bras Otorhinolaryngol (Eng Ed). 2005; 71:101-103.
5. Celikkanat S, Turgut S, Ozcan I, Balyan FR, Ozdem C (1997) Rhinolithiasis. Rhinology 35:39-40.
6. Polson CJ (1943) Onrhinoliths. J LaryngolOtol 58: 79-116.
7. Orhan K, Kocyigit D, Kisnisci R, Paksoy CS. Rhinolithiasis: an uncommon entity of the nasal cavity. Oral Surg Oral Med Oral Pathol Oral RadiolEndod.2006; 101: 28-32.
8. Mustafa A, Nishori S. Rhinolith caused from the undetected foreign body: A case report. Kosova Journal of Surgery. 2008; 2(1):32-35.
9. Appleton SS, Kimbrough RE, Engstrom HIM (1988) Rhinolithiasis: a review. Oral Surg 65: 693-698.
10. Eliachar I, Schalit M (1970) Rhinolithiasis: report of eight cases. Arch Otolaryngol 91: 88-90.
11. Flood TR (1988) Rhinolith: an unusual cause of palatal perforation. Br J Oral Maxillofacial Surg 26: 486-490.
12. Varley EWB (1964) Rhinolith: an incidental finding. Br J Oral Surg 2: 40-43.
13. Hsiao JC, Tai CF, Lee KWl. Giant rhinolith: A case report. Kaohsiung J Med Sci 2005; 21:582-5.
14. Keck T, Liener K, Strater J, Rozsasi A. Rhinolith of the nasal septum. Int. J Pediatrhinolaryngol 2000; 53; 225-228.
15. Royal SA, Gardner RE. Rhinolithiasis: An unusual pediatric nasal mass. PediatrRediol 1998; 28:54-55.
16. Carder HM, Hiel JJ (1966) Asymptomaticrhinolith: a brief review of the literature and case report. Laryngoscope 76: 524-530

Source of Support: None Declared
Conflict of Interest: None Declared