

Role of endovascular treatment in lower limb ischemia

Prashant G Pote^{1*}, Shivraj Ingole², Meenakshi Gajbhiye³, Sharad Malvadkar⁴, Shariq⁵ Gayatri Autkar⁶

^{1,5,6}JR III, ^{2,4}Associate Professor, ³Professor and HOD, Department of Radiodiagnosis, GGMC and JJ hospital, Mumbai, Maharashtra, INDIA.

Email: drprashantpote@gmail.com

Abstract

Aim: Our study aimed at evaluation of efficacy of endovascular treatment in terms of primary patency rate and limb salvage rate in lower limb peripheral vascular diseases along with evaluation of technical and clinical success rate and complications occurring during endovascular treatment. **Material and Methods:** This study was carried out in total of 50 patients referred to our department with symptoms of limb ischemia were evaluated by Duplex scan and CT angiography. Patients with TASC category A and B lesions were treated by endovascular treatment like angioplasty and stenting as when required under 'Artis Zee Siemens biplaner DSA machine'. Post procedure patient were followed up at 6 months. Follow up was be done by duplex ultrasound scan. **Results:** We observed steady rise in number of patients operated with increase in age. Maximum patient were between 60-70 years (30%) followed by those in their 5th decade (22%). Diabetes was the most commonly encountered risk factor accounting for 56% patients. 54% patients showed the second most common association in the form of smoking. Hypertension was related to 40% patients. Total 56% patients (n=28) underwent angioplasty without stenting while 44% (n=22) patients required additional treatment in the form of stent placement. Most of the patients operated were from category B in both aortoiliac (n=7) and femoro-popliteal (n=14) groups. For infrapopliteal lesions the mode of treatment was only angioplasty without stent placement was done. Most complication are seen in the treating infrapopliteal lesions (n=6). Overall spasm of vessels was most common complication followed by puncture site hematoma and distal embolisation. A primary patency rate of 70% was observed. Limb salvage rate came to 78.0%. Aorto-iliac stenting had better outcome (77%) in primary patency vs. femoro-popliteal stent outcomes (69%). In femoro-popliteal lesions; stenting had a better outcome (69%) as compared to plasty alone (62%). **Conclusion:** Endovascular re-vascularisation procedure are effective and safe procedure. Angioplasty has dramatically improved the patient's symptoms and healing those non healing ulcer, thus improving the quality of life.

Keywords: DSA, angiography, endovascular, angioplasty, stent, aortoiliac, femoro-popliteal, infrapopliteal, limb salvage, primary patency.

*Address for Correspondence:

Dr. Prashant G Pote, JR III, Department of Radiodiagnosis, GGMC and JJ hospital, Mumbai, Maharashtra, INDIA.

Email: drprashantpote@gmail.com

Received Date: 14/04/2016 Revised Date: 11/05/2016 Accepted Date: 10/06/2016

Access this article online

Quick Response Code:



Website:

www.statperson.com

DOI: 12 June 2016

INTRODUCTION

Peripheral arterial disease is one of the manifestations of systemic atherosclerosis. It is important to remember the significant association of coincident coronary artery disease, which is the major cause of mortality in these patients. Remarkable technological advances in the past

decade have shifted revascularization strategies from traditional open surgical approaches toward lower-morbidity percutaneous endovascular treatments. The procedure has greatest value for dilatation of vascular lesions which avoids surgery and its attendant risks. However, endovascular treatment and surgery are complementary to one another. Endovascular treatment complements the traditional therapy of peripheral vascular disease, which remains reconstructive surgery. The availability of stents, more than any other advance, has fuelled the growth of catheter-based procedures by improving the safety, durability, and predictability of percutaneous revascularization. Endovascular therapy offers several distinct advantages over open surgical revascularization but for selected lesions. It is performed with local anaesthesia, which enables the treatment of patients who are at high risk for general anaesthesia. The

morbidity and mortality from catheter-based therapy is extremely low, especially compared with open surgical revascularization. So after successful percutaneous revascularization, patients are ambulatory on the day of treatment, and unlike after vascular surgery, they can often return to normal activity within 24 to 48 hours of an uncomplicated procedure. In addition these endovascular therapies generally do not preclude or alter subsequent surgery and may be repeated if necessary.

MATERIAL AND METHODS

A total of 50 patients referred to our department with symptoms of limb ischemia were evaluated by Duplex scan and CT angiography. Patients with TASC category A and B lesions were treated by endovascular treatment like angioplasty and stenting as when required under Artis Zee Siemens biplaner DSA machine. Post procedure patient were followed up at 6 months. Follow up was be done by duplex ultrasound scan.

OBSERVATIONS AND RESULTS

Table 1: Patient’s distribution according to age group

Age Groups	Frequency	Percent
<40	9	18%
40-50	7	14%
50-60	11	22%
60-70	15	30%
70-80	8	16%
Total	50	100.00%

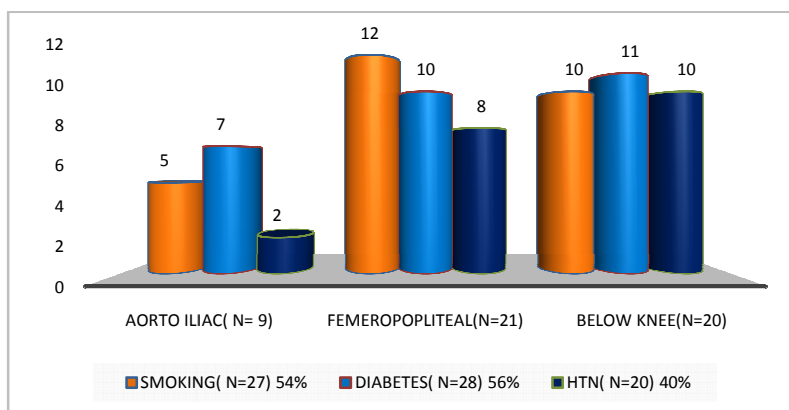


Figure 1: Patient’s distribution according to location and risk factors

Table 2: Distribution of cases according to type of procedure

Treatment	Aorto-iliac (AI)			Femoropopliteal (FP)			Infrapopliteal (IP)
	A	B	C	A	B	C	
Angioplasty without stenting (N=28), 56%	0	0	0	1	6	1	20
Angioplasty with stenting (N=22), 44%	1	7	1	2	8	3	0

Table 3: Incidence of complications

Complication	AI	FP	IP
Puncture Site Hematoma (N=3) 6%	0	2	1
Spasm (N=4) 8%	1	1	2
Distal Embolisation (N=3) 6%	1	0	2
Dissection (N=1) 2%	0	0	1
Vessel Rupture (N=0) 0%	0	0	0
Stent Migration (N=0) 0%	0	0	0

Table 4: Primary patency and limb salvage rates

	Aorto-iliac (N=9)		Femoropopliteal (N=21)		Infrapopliteal (N=20)	
	Angioplasty without stent (0)	Angioplasty with stent (9)	Angioplasty without stent (8)	Angioplasty with stent (13)	Angioplasty without stent (20)	Angioplasty with stent (0)
Primary patency at 6 months; (N=35), 70%		77% (7)	62% (5)	69% (9)	70% (14)	
Limb salvage (N=39), 78%		77% (7)	62% (5)	76% (10)	85% (17)	

DISCUSSION

We evaluated 50 patients presenting with either severe claudication or tissue loss and angioplasty with or without stenting was performed in our department. It includes 37 males and 13 females. Smoking (54%) and diabetes (56%) were the main risk factors followed by hypertension (40%) in our study. 64% (n=32) patients underwent angioplasty without stent placement while total 36% (n=18) patients were treated by primary stenting. Total primary patency rate was found 70% and limb salvage rate reached up to the 78% at 6 months follow-up. In the study performed by Scheinert *et al*¹ total 873 patient with critical limb ischemia were operated. In the group of iliac artery stenting primary patency rate of 94% is determined. Stent placement versus angioplasty without stenting also favored primary stent placement by demonstrating a 4-year patency rate of 94% for the stent group versus 69% for the angioplasty without stenting group.¹ In our study primary patency rate for primary stent placement was 77% for aorto-iliac patients. In the same study they obtained clinical success in 91% by use of a combination of provisional stent placement with or without thrombolytic therapy for thrombotic occlusions in femoropopliteal subgroup. The rate of limb salvage and freedom from target-vessel revascularization was 88%. In our study limb salvage was 76% with stent against 62% when only angioplasty with no stent was used as a method of treatment for femoropopliteal group. Use of additional therapy or combination with thrombolytic has shown better limb salvage rate in their study. Thrombolysis was not included as part of treatment in our study. Scheinert *et al* demonstrated procedural success rates for below-knee intervention in limb-salvage patients range from 60% for occlusions to >90% for more ideal lesions. Henry *et al*² performed analysis on 310 patients with use of stent in primary angioplasty and follow-up patients for 2-4 years. Immediate procedural success was achieved in 309 patients with just 1 case failure. In our study technical failure rate was 2%. In only one patient we could not dilate the vessel wall due to extensive calcification of vessel wall hence procedure was abandoned. In their study angiography performed at 6 months in 299 patients revealed restenosis rates of 0.5% in iliac lesions, 11% in superficial femoral artery (SFA) lesions, and 20% in popliteal lesions. Survival analysis revealed 4-year primary patency rates of 86% +/- 4.1 for iliac artery lesions, 65% +/- 7.5 for SFA lesions. In our study this primary patency rate was 77% in aorto-iliac and 69% in femoro-popliteal group. Both the study results are comparable though the difference in actual rate appears to be largely due to smaller sample size in our study. In another study done by Jamsen *et al*³ on 100 patient only infrainguinal vessels were operated. They

observed 65% primary patency rate after 3 years. In Sullivan *et al*'s⁴⁸ study on 288 patients on iliac artery achieved 84% primary patency rate at 24 months of observation. So they concluded that PTA and stenting of the iliac arteries is associated with reasonable angiographic, hemodynamic, and clinical success. Vorweck *et al*⁴ came up with another study on 109 aortoiliac vessels and found primary patency of 85% at 2 years. In our study primary patency was 77%. Silva *et al*⁵ performed another study of profundoplasty on 31 patients. The achieved procedural success rate was 91% and limb salvage rate was 94%. Soder HK *et al*⁶ evaluated 72 patients of infrapopliteal disease and concluded primary patency rate of 84% in stenosis and 61% in occlusion. Limb salvage was 80% at 18 months. In our study we observed 70% primary patency rate and limb salvage in 85%. However stenosed and occluded vessels were not studied separately. So Soder HK *et al*⁶ concluded that infrapopliteal PTA is a feasible primary treatment of chronic critical limb ischemia with moderate primary angiographic and clinical success, a low complication rate, and a cumulative limb salvage rate comparable with surgical technique. Dorros *et al*⁷ did study on 111 patients with tibioperoneal involvement. A successful PTA was achieved in 152/168 (90%). Those with restenosis or progressive disease have undergone 2nd PTA. Angiographic and clinical success was achieved in 42 patients undergoing second PTA (96%). So they reached to the conclusion that angioplasty can be successfully utilized in patients with symptomatic obliterative disease of the tibioperoneal vessels with excellent success, a low risk of complications, and good clinical improvement. In our study 20 patients underwent angioplasty for below knee disease. Primary patency was seen in 14 (70%) cases. We faced varied complication during procedure. Most of them were non-limiting and did not extend patient's stay in hospital. Commonly encountered problems were puncture site hematoma (3), spasm of vessels (4), and distal embolization (3). The puncture site hematoma was found related to high femoral puncture and in hypertensive patients and was tackled successfully with manual pressure. Spasm of artery was self-limiting and subsided on its own. Only 1 case of dissection was found. In the study by Soder HK *et al*⁶, 2.8 % cases of pseudoaneurysms were encountered. Contrast induced renal failure (4%), distal embolization (4%), dissection (2%) and groin hematoma (2%) were reported complication in Dorros *et al*⁷ study on tibioperoneal vessel percutaneous revascularization. In addition to life style modifications, an optimal medical treatment, including at least one antiplatelet regimen and a meticulous control of the cardiovascular risk factors, the lower limb revascularization is an essential step by

treating CLI patients. There are two different way to improve distal blood perfusion: the surgical and the endovascular approach. The aim of these procedures is to improve ischemic rest pain or to allow an ischemic ulcer to heal, finally avoiding major amputation i.e. to achieve the limb salvage. Among patients with both inflow and outflow (infrainguinal) disease, the ACC/AHA guidelines as well as the TASC II guidelines recommended that inflow lesions be addressed first, whether surgery or percutaneous intervention is performed⁸. After this has been accomplished, revascularization of outflow disease is warranted if there is persistent infection, ischemic ulcers, or gangrenous lesions, and the ABI remains less than 0.8.⁹ Until recently, the surgical options (e.g. femoropopliteal or femoro tibial bypasses) were the only available approach in order to improve foot perfusion. These kind of limb-saving interventions are associated

with an increased risk of morbidity and mortality, especially in this particular CLI patients' subset (i.e., elderly and sick patients), and despite a relatively disappointing long-term patency rate of the performed intervention, surgery was very often proposed as first line treatment. Accordingly, to BASIL trial¹⁰ has showed that in 450 patients presenting with a CLI due to an infra-inguinal arterial disease who were eligible for either procedure (surgical or endovascular), at 30 days, there was no difference in mortality between the two groups, but surgery was associated with a significantly higher rate of morbidity (57 versus 41%). Furthermore, there was no difference in the primary end point (survival without amputation) at one year (71% with endovascular versus 68% with surgery) and three years (52% versus 57%), with only a higher rate of re-intervention in the endovascular group (26% versus 18%).¹⁰

CASE I

55 yrs. /male Chronic Smoker and diabetic on treatment C/o rest pain in both legs since 2 months.

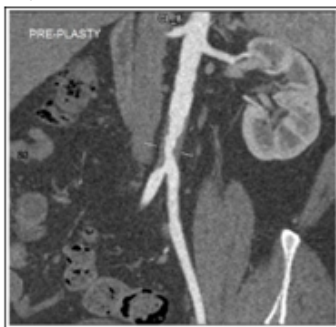

Figure 1a

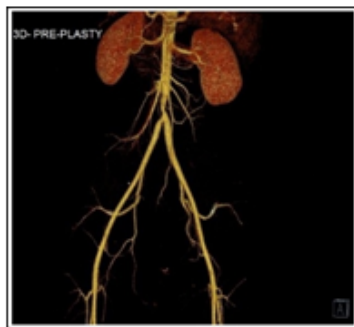

Figure 1b

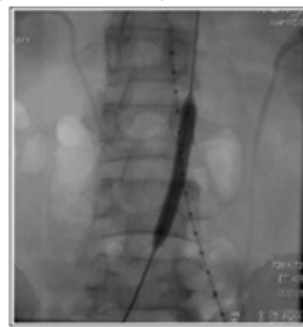

Figure 1c

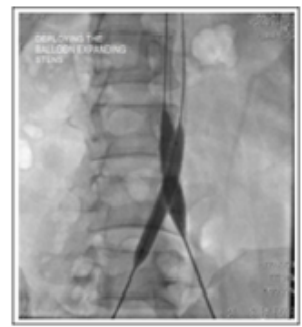

Figure 1d

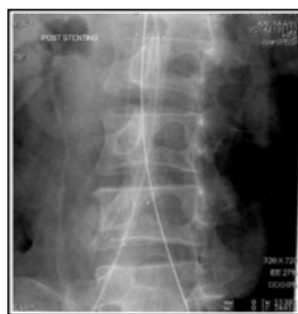

Figure 1e

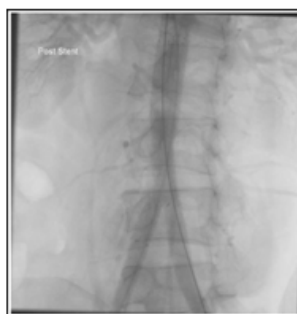

Figure 1f

Figure 1a: Coronal MIP image of CT angiogram and **Figure 2b:** 3D reformatted image showing short segment stenosis involving aorta extending into the bilateral iliac arteries.

Figure 1c and d: The lesion was dilated with "MUSTANGTM Over-The-Wire balloon (12mmX40MM) 120 cm" placed in both the common iliac arteries.

Figure 1e and f: Boston Scientific Epic Stent (10mm X 100mm) 120cm" were deployed in both the CIA with their proximal end opened into the aorta above the stenotic lesion (KISSING STENTS)

CASE II

70yrs/Female DM2+ Tobacco + Blackish left 1st and 2ndtoes since 1 month.

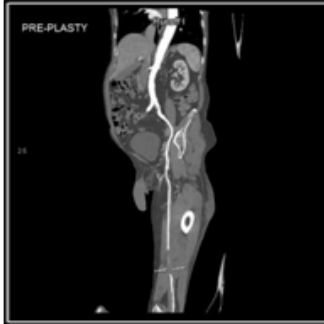

Figure2a

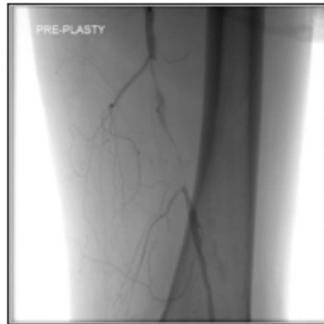


Figure2b

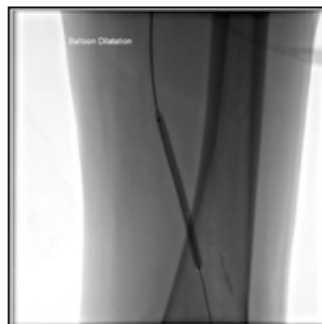

Figure 2c

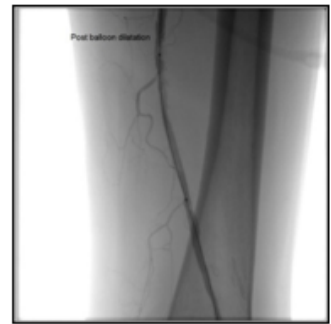


Figure d

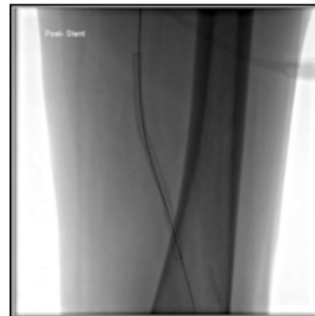


Figure 2e

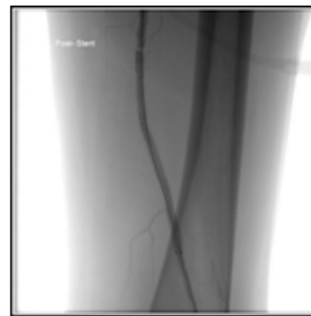

Figure 2f

Figure 2a: CT angiography and DSA angiogram **Figure 2b:** Shows high grade stenosis due to atherosclerotic plaque in mid superficial femoral artery.

Figure 2c) The lesion is crossed with Amplatz super stiff guide wire (0.035 inch x 260 cm) and dilated with “MUSTANGTM Over-The-Wire balloon (5mm X 80mm) 135 cm”. **Figure 3d:** Restored flow immediate post balloon dilatation

Figure2e and f: Epic TM Over-The-Wire Self Expanding Stent (6mmX120mm) 120 cm deployed across the lesion. Post stenting angiogram showing optimum flow across the stent.

CASE III

48yrs/ Female Diabetic and hypertensive Blackening of great toe since 3 months.

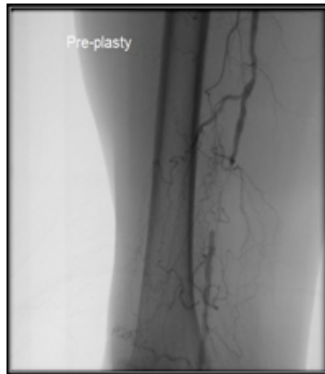


Figure 3 a

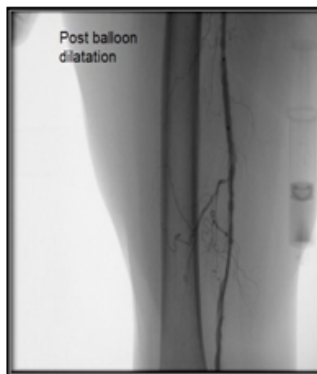

Figure 3b

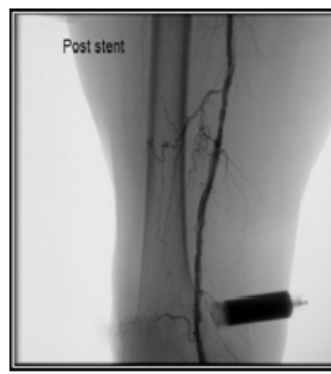


Figure 3c

Figure 3a: DSA angiogram shows TASC B lesion in mid SFA.

Figure 3b: The lesion was crossed and opened with “Cordis OPTA PRO balloon (6mm x 80mm)”.

Figure 3c: Post stenting angiogram shows optimum flow across the lesion. “Cordis SMARTR CONTROLTM NITINOL STENT (6mm X 60mm) was used for this patient.

CASE IV

54yrs/ Male, Diabetic and tobacco chewer. Rest pain since 2 months

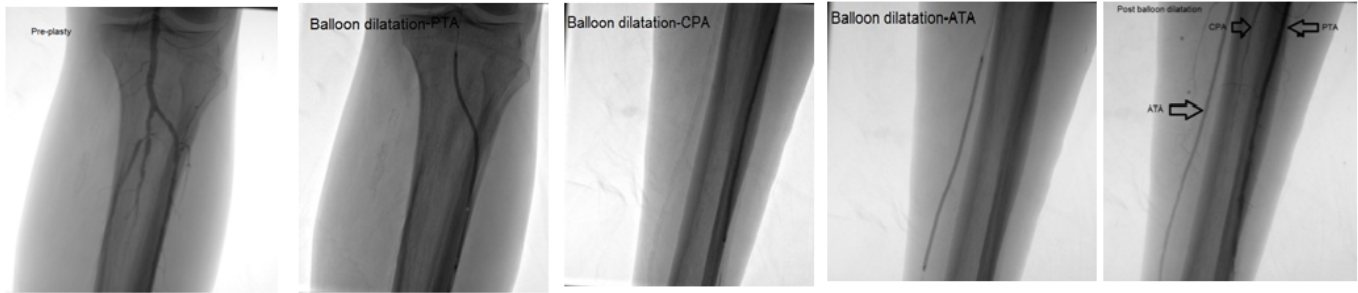


Figure 4a

Figure 4b

Figure 4c

Figure 4d

Figure 4e

Figure 4a: DSA angiogram shows multisegmental stenosis involving the infrapopliteal vessels (ATA, PTA and CPA) with poor distal contrast opacification.

Figure 4 b, c, d: These tandem lesions were treated with “AVIATOR™ PLUS (4mm x 20mm) and BLUE™ (6mm X 15 mm)” dilatation as shown in above images.

Figure 4e: Post dilatation angiogram showing adequate contrast of ATA and PTA.

CONCLUSION

1. Atherosclerosis, DM, hypertension and smoking are the major risk for peripheral vascular disease.
2. Angioplasty has dramatically improved the patient’s symptoms and healing those non healing ulcer, thus improving the quality of life.
3. Endovascular re-vascularisation procedure are effective and safe procedure and patient can be ambulatory on the same day of procedure.
4. The procedure can be repeated in those patients who develop recurrence and also maintains surgical option for extremity revascularization.

REFERENCES

1. Scheinert, D., et al., Stent-supported recanalization of chronic iliac artery occlusions. *Am J Med*, 2001. 110(9): p. 708-15.
2. Henry, M., et al., Palmaz stent placement in iliac and femoropopliteal arteries: primary and secondary patency in 310 patients with 2-4-year follow-up. *Radiology*, 1995. 197(1): p. 167-74.
3. Jamsen, T., et al., The final outcome of primary infrainguinal percutaneous transluminal angioplasty in

100 consecutive patients with chronic critical limb ischemia. *J VasIntervRadiol*, 2002. 13(5): p. 455-63.

4. Vorwerk, D., et al., Aortic and iliac stenoses: follow-up results of stent placement after insufficient balloon angioplasty in 118 cases. *Radiology*, 1996. 198(1): p. 45-8.
5. Silva, J.A., et al., Percutaneous profundaplasty in the treatment of lower extremity ischemia: results of long-term surveillance. *J EndovascTher*, 2001. 8(1): p. 75-82.
6. Soder, H.K., et al., Prospective trial of infrapopliteal artery balloon angioplasty for critical limb ischemia: angiographic and clinical results. *J VasIntervRadiol*, 2000. 11(8): p. 1021-31.
7. Dorros, G., et al., Below-the-knee angioplasty: tibioperoneal vessels, the acute outcome. *CathetCardiovascDiagn*, 1990. 19(3): p. 170-8.
8. Hirsch, A.T., et al., Peripheral arterial disease detection, awareness, and treatment in primary care. *JAMA*, 2001. 286(11): p. 1317-24.
9. Bernstein, E.F., et al., Toe pulse reappearance time in prediction of aortofemoral bypass success. *Ann Surg*, 1981. 193(2): p. 201-5.
10. Adam, D.J., et al., Bypass versus angioplasty in severe ischaemia of the leg (BASIL): multicentre randomised controlled trial. *Lancet*, 2005. 366(9501): p. 1925-34.

Source of Support: None Declared
Conflict of Interest: None Declared