Original Article

Prospective analysis of functional outcome of bicondylar tibial plateau fractures treated by fixation with locking compression plates

M Kannan

Associate Professor, Department of Orthopaedics, Government Thiruvarur Medical College, Thiruvarur, Tamil Nadu, INDIA.
Email: drkannanortho@rediffmail.com

Abstract

Introduction: High energy tibial plateau fractures (Schatzker type V, VI) are associated with severe soft tissue injury and this complicates the treatment of this injuries. Surgical approach depends upon the site of soft tissue injury and timing of surgery depends upon the degree of soft tissue injury. The optimal treatment of Schatzker type V, VItibial plateau fractures remains controversial and challenging due to highly demanding surgical procedure and perioperative complications. In our study we have primarily used lateral locking compression plating in the treatment of bicondylartibial plateau fractures. **Materials and Methods:** Our study was a prospective study, conducted at the Department of Orthopaedics, Government Mohan Kumaramangalam Medical College and Hospital, Salem between May 2012 and August 2015.Anteroposterior and lateral views of x ray films were taken and 3D-CT scans were taken routinely to assess three dimensional fracture geometry. Functional assessment was done using **Knee Society Score**. Radiological assessment was performed taking into account two parameters: Medial proximaltibial angle and Articular step off. **Results:** We studied 27 patients with proximal tibial fracture who were treated with locking compression plate. Majority of cases were Schatzker type VI (85.18 %) compared to type V.In our series > 90 % cases fixed by MIPPO technique to avoid soft tissue damage and enhance the biological bone healing.In our series we have done primary bone grafting for 5 cases only. Most of our cases well united without bone grafting. In our cases majority of cases (> 80%) united between 12-16 weeks (average 13.7 weeks). In our study the clinical outcome of most of the patients (19) was excellent, which was based upon Knee society score. 06 patients had good and two patients with fair results. **Conclusion:** Early mobilization is possible with LCP because of absolute stability given by the implant and this contributes to better knee range of motion. Medial condyle coronal fracture and small posteromedial fragment should be buttressed by posteromedial plating. Not all bicondylar fractures are same, treatment should be precise to individual fracture pattern. Bicondylartibial plateau fractures treated with locking compression plate have an excellent to good functional outcome with very minimal wound complications.

Keywords: Tibial plateau fractures, Schatzker types, Locking Compression Plates, Knee Society Score.

***Address for Correspondence:**
Dr. M. Kannan, Associate Professor, Department of Orthopaedics, Government Thiruvarur Medical College, Thiruvarur, Tamil Nadu, INDIA.
Email: drkannanortho@rediffmail.com
Received Date: 17/06/2016 Revised Date: 13/07/2016 Accepted Date: 07/08/2016

Access this article online	
Quick Response Code:	Website: www.statperson.com
	DOI: 14 August 2016

INTRODUCTION

Intra articular fractures of tibial plateau more common in recent days. These fractures resulting from direct axial compression and indirect coronal forces. The injuries span a wide spectrum, ranging from low energy unicondylar fractures to high energybicondylar and comminuted fractures. High energy tibial plateau fractures (Schatzker type V, VI) associated with severe soft tissue injury and this complicates the treatment of this injuries. Surgical approach depends upon the site of soft tissue injury and timing of surgery depends upon the degree of soft tissue injury. The optimal treatment of Schatzker type V, VItibial plateau fractures remains

How to site this article: M Kannan. Prospective analysis of functional outcome of bicondylar tibial plateau fractures treated by fixation with locking compression plates. *International Journal of Recent Trends in Science and Technology* August 2016; 20(1): 118-124 http://www.statperson.com (accessed 16 August 2016).

controversial and challenging due to highly demanding surgical procedure and perioperative complications. The goals of treatment of high energy tibial plateau fractures are to restore anatomical articular congruity, mechanical alignment restoration, joint stability with minimal soft tissue dissection to allow for early mobilization and establishment of good function. The treatment options for high energy tibialplateau fractures are POP immobilization, hybridexternal fixator, open reduction and internal fixation etc., High energy Tibial plateau fractures initially treated with dual plating were associated with long term complications like wound problems, implant irritation and implant exposure. Newer methods for the treatment of high energy tibial plateau fractures are lateral locking plates and Hybrid external fixation. Posteromedial buttress plating for bicondylartibialplateau fractures has been associated with posteromedial fragment. In our study we have primarily used lateral locked plating in the treatment of bicondylartibial plateau fractures. However, in cases with extensive medial comminution or when a postero-medial fracture fragment is present, dual plating is occasionally used.

MATERIALS AND METHODS

Our study was a prospective study, conducted at the Department of Orthopaedics, Government Mohan Kumaramangalam Medical College and Hospital, Salem between May 2012 and August 2015. Total of 27 patients were studied and evaluated during the study period.

Inclusion Criteria

- Age > 18 years
- Schatzker type V and VI tibial plateau fractures
- Closed fractures
- Grade I compound fractures

Exclusion criteria

- Age < 18 years
- Grade II and III compound fractures
- Associated with vascular injury/ compartment syndrome
- Pathological fractures

Preoperative management

Patients were given adequate analgesia on reception in casualty. The injured limb was temporarily immobilized in Thomas splint and patients were shifted for x ray. Anteroposterior and lateral views were taken. Manual traction was used where appropriate. CT scans were taken routinely to assess three dimensional fracture geometry. Skeletal traction was applied to all patients in the form of calcaneal pin traction and weights applied with Bohler Braun splint. Ice fomentation was encouraged in the initial two days. Skin over fracture was closely watched. Those presenting with severe soft tissue edema or blisters were taken up for surgery only after the appearance of ―wrinkle sign. In case of severe soft tissue injury knee spanning external fixator was used upto the period of definitive surgery. Soft tissue tension and distal neurovascular status checked periodically to rule out compartment syndrome. Anti –edema measures were instituted for all of our patients. The patient was suitably anaesthetized-regional or general according to the patient. Surgery was performed in supine position with the leg support. Anterolateral, posteromedial and anteromedial approaches were used for fixation. Recommended A-O technique of fracture fixation was used.

Surgical Procedure

Under spinal anaesthesia, patient was placed in supine position, with leg support providing knee flexion. In case of shortening and overriding of fracture fragments, reduction was achieved with femoral distractor. Temporarily the reduced fragments were fixed with K wires. Bicondylar fractures without coronal fracture in medial condyle were managed with lateral locking plate. Anterolateral approach was used for application of lateral locking plate. The lateral fracture was approached through anterolateral approach. For MIPPOtechnique curvilinear incision was made in between the Gerdy's tubercle and anterior to the head of fibula. Fascia was incised in line with the skin incision. Fracture site was exposed and indirect reduction of fracture was done and temporarily fixed with K wires. Articular reduction maintained with reduction clamp. Extra periosteal plane were created using blunt dissector. Locking compression plate was introduced extra periosteally, plate position was checked under C-arm in both AP an Lateral views. Plate was temporarily fixed with proximal and distal K wire to avoid helicopter effect. First screw was applied proximally parallel to the articular surface. Depressed fragments were elevated and void was filled with bone grafting or bone substitutes. Distal most screw was applied through mini incision. K wires were removed, other screws were applied to the plate.

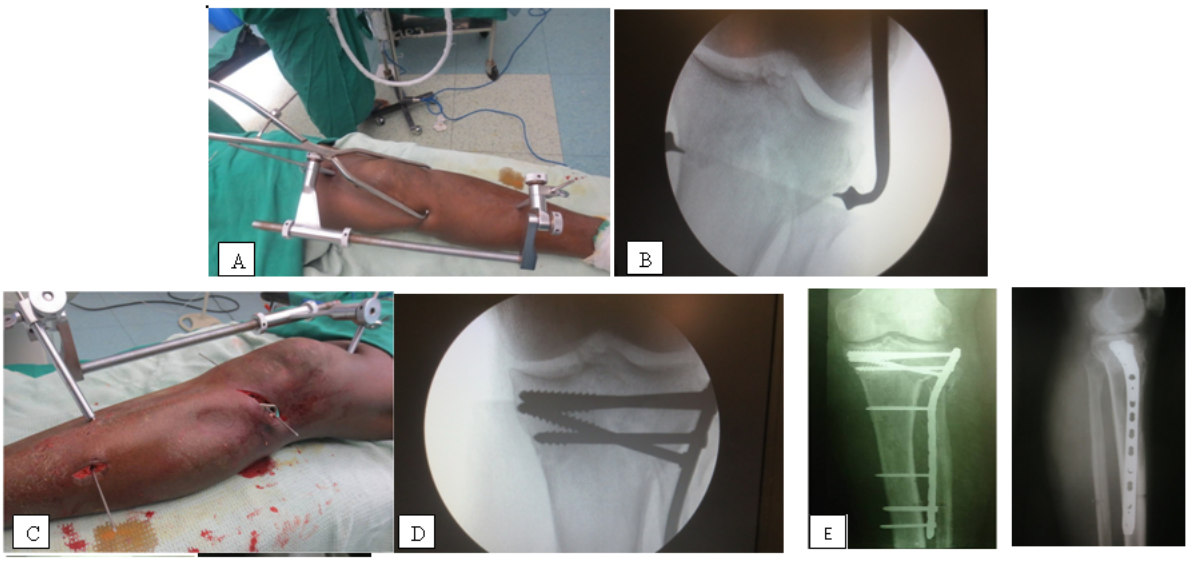

Figure 1: Fixation by MIPPO technique AandB) Reduction of fracture using femoral distractor and reduction clamp C) Insertion of LCP by MIPPO and temporary K wires fixation D) After proximal screws fixation E) Post op X Ray films

For open reduction incision was started from 5 cm above the joint line and extended distally up to the fracture site. To expose the fracture site clearly part of the iliotibial band released from Gerdy's tubercle. Further procedure as same as MIPPO technique. Medial condyle fracture in coronal plane and posteromedial fragment not reduced with lateral locking plate were addressed through posteromedial approach and fixed with 3.5 mm locking reconstruction plate.

POST OPERATIVE PROTOCOL

Patients were maintained in a well padded dressing postoperatively. Slabs were not used for immobilization. Drain was removed on second postoperative day. Antibiotics were used for 5 days. Suture removal was done on 12th postoperative day. Patients were discharged on non weight bearing crutch walking. Knee mobilization was encouraged as soon as the patient was able to tolerate motion. 90 degrees active knee flexion was achieved in all cases within 10 days post surgery.

FOLLOW UP

The first follow up was usually between 4-6 weeks and later on patients were followed up at regular interval of 4-6 weeks till complete fracture union. Partial weight bearing was started after 8 weeks when the fracture showed union. Full weight bearing was achieved only after solid fracture union usually between 12-14 weeks. Further follow up was done once every 3 months.

Assessment

Functional assessment was done using Knee Society Score. Radiological assessment was performed taking into account two parameters: 1.Medial proximal tibial angle: measured between proximal tibial knee joint orientation line (drawn connecting the concave surfaces of both tibial plateaus) and the mechanical axis of tibia and 2). Articular step off : measured in plain x ray

OBSERVATIONS AND RESULTS

We studied 27 patients with proximal tibial fracture who were treated with locking compression plate. In our study most of the patients belong to 41-50 years. Out of 27 cases incidence in > 40 years was 81% (Age range between 23-75 years, average age being 51.25years). In our study more common mode of injury is road traffic accidents (89%) compared to accidental fall. It indicates the high energy nature of bicondylartibial plateau fractures. Majority of cases were Schatzker type VI (85%) compared to type V (15%).In our series 12 cases (44.44%) had posteromedial fragment of which 4 patients had posteromedial fragment in coronal plane. Associated injuries are fracture shaft of femur and patella in 1 case, fracture shaft of femur alone in 1 case, fracture both bones forearm in 1 case, fracture neck of femur in 1 case and 23 patients had no other associated injuries. Usually we have used calcaneal pin for skeletal traction. Preoperative external fixator was used for four patients admitted with tense compartment and blebs over the leg. Surgery was delayed until appearance of wrinkle sign. Temporary external fixator enhances the soft tissue healing potential and reduces deep infection(Damage control orthopaedics).[16] In our series > 90 % cases (25 out of 27 cases) were fixed by MIPPO technique to avoid soft tissue damage and enhance the biological bone healing. In our serieswe had done single lateral locking compression plate for 22 patients and Dual plating for 5 patients. We had used posteromedial buttress plating for five cases of which 4 cases had posteromedial (coronal) fragment and

1 case in which posteromedial (small) fragment was not reduced with single lateral locking plate. In our series we have done primary bone grafting for 5 cases only. Most of our cases well united without bone grafting. The mean duration of surgery was 77 minutes (50-120min) and the average blood loss was 70 ml (40-200ml). In our cases majority of cases (> 80%) united between 12-16 weeks with an average of 13.70 weeks.

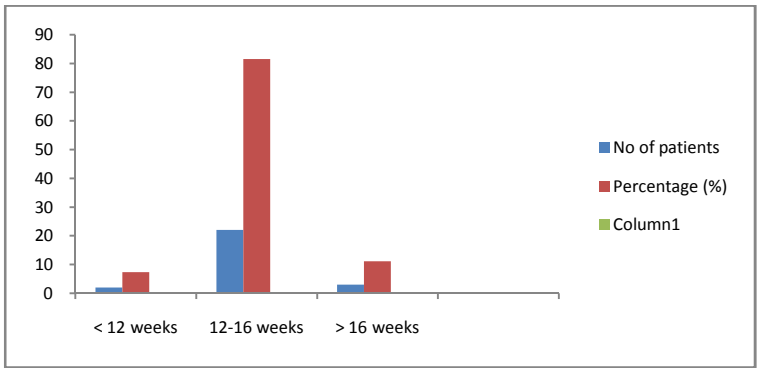

Figure 2: Results showing no. of patients and time taken for fracture union

In our study most of our patients (21 patients) had range of motion > 120 degree. Two patients developed knee stiffness due to poor adherence to physiotherapy. The clinical outcome of most of the patients (19) was excellent, which was based upon Knee society score. 06 patients had good and two patients with fair results.

Table 1: Functional results as per Knee Society Score

Interpretation	No of patients	Percentage (%)
Excellent	19	70.37
Good	6	22.22
Fair	2	07.40
Total	**27**	**100**

Figure 3: Illustration of management in 52 years male with type V Schatzkertibial plateau fracture (A) Pre op X Rays (B) Pre op 3D CT images (C) Post op X Rays (D) X Rays at 8 months follow up (E and F) Clinical results at 8 months follow up

Radiologically, Medial proximal tibial angle (MPTA) measurement was undertaken to assess varus/valgus malunion postoperatively. The normal value of MPTA is 87+/-5 degrees. In our series, the average value was 85.4 degrees (range 83 – 91degrees). Thus, we found that the normal proximal tibial joint orientation is maintained

after application of LCP. Articular step off was assessed with less than or equal to 2 mm step off kept as acceptable limit. In our series, 2 cases had articular step off more than 2 mm (range 3 – 5 mm) and 25 cases had the acceptable result of less than or equal to 2 mm step off. In our study we had 20 patients with no complications. Two patients developed knee stiffness due to poor compliance for physiotherapy. One patient had non-union of distal part of tibial tuberosity fragment which was not fixed primarily. Two patients developed distal screw infection for that one patient was treated with oral antibiotics and screw exit was done for another patient. One patient came with implant exposure after 10weeks of post operativeperiod. Implant removal was done and put an knee spanning external fixator. Fracture united in 14 weeks and external fixator was removed.

DISCUSSION

In this study, analysis of the results was made in terms of age and gender of patients, mode of injury, analysis of the types, medial condyle fracture planes, primary bone grafting, method of reduction and fixation, preoperative external fixation, dual plating, associated injuries and complications. In our study maximum age incidence of tibial plateau fracture was >40yrs (81%). Average age group in our study was 51.25 years, ranging from 40 – 70 years, compared to Gosling *et al* 2005 study (Average age group 51.5 years).[6] Males were most commonly affected compared to females (4.4:1). This may be explained by active lifestyle of males and higher chances of road traffic accidents. In our study road traffic accidents were the cause of injury in 24 patients out of 27. Accidental fall was the cause for three patients, all of them were old age patients (>60) with osteoporotic bones. We had only 4 cases of type V Schatzkertibialplateau, other 23 cases being type VI. Out of 27 cases 12 cases had posteromedial fragment in their CT scans, in which 4 cases (14.81%) had medial condyle fracture in coronal plane. Barei *et al* evaluated incidence of medial coronal fracture in Schatzker type V, VI and it was found to be 29%. In our series the indications for the surgery were the same standard indications as for the tibial plateau fractures. Four of our cases were associated with other injuries like fracture shaft of femur with patella, fracture shaft of femur, fracture both bone forearm and fracture neck of femur. We had done Interlocking nail for shaft of femur cases, tension band wiring for patella, ORIF with plating for both bone forearm and Hemiarthroplasty for neck of femur fracture. In our study we used preoperative temporary knee spanning external fixator in four of our patients came with tense compartment and blebs over the leg. Surgery was deferred until wrinkle sign to appear. We used MIPPO techniquefor reduction and fixation in 25 cases (92%) in which both duration of procedure and surgical insult to the soft tissues are very less compared to open reduction and internal fixation [17]. Wound healing was also better and faster compare to ORIF technique but it demands challenging surgical techniques [18,19]. Biological healing will not be disturbed in MIPPO technique. MIPPO technique is recommended for high energy tibial plateau fracture associated with severe soft tissue injury.[20-27] Indirect reduction of fracture and maintenance of axial alignment before the application of plate is very essential to achieve good functional outcome. In our study we used femoral distractor for indirect reduction[28-30] in all of our cases and axial alignment was checked under C-arm in both AP and Lat direction.[6] Dual plating was done for 4 cases with medial condyle fracture in coronal plane and one case which was not reduced after application of lateral locking plate due to small size of the fragment. All of our patients had stable soft tissue condition that allows us to do dual plating. We have used posteromedial approach for medial buttressing (antiglide effect).[31,32] Single lateral locking plate alone not sufficient to stabilize the medial condyle coronal fracture and small posteromedial fragment.[8,16] Single lateral LCP results in collapse of medial condyle.[33-36] Course of locking screw is predetermined (monoaxial configuration) and parallel to the fracture line which does not give any compression at fracture site.[37] In our study primary bone grafting was done only in 18.5% of cases mainly to fill the metaphyseal defects after the elevation of depressed lateral condyle, comparable to 19% of the same in the study by Gosling *et al* 2005 using LCP[6].Routine bone grafting not necessary with LCP[6] because it provides absolute articular stability which gives the hematoma and cancellous bone chance to fill the defects. In our study fracture union in 81 % of cases occurred in between 12-16 weeks. The mean time to union was 13.70 weeks ranging from 11-18 weeks, comparing with 10 weeks in Ehlinger *et al*[38]and 15.4 weeks in Yu *et al*[37] studies and there was no case of non-union in primary fracture lines. In our study 77.77% of cases had range of motion >120 degrees. The mean range of motion was 102.4 degrees ranging from 60-130 degrees. Two of our patients developed knee stiffness due to poor adherence to physiotherapy. Our results comparable with Ehlinger *et al* mean ROM-107.6^0.Average period for return to work in our study was 17.42 weeks. Two of our patients developed distal screw site infection. One patient was treated with wound debridement and oral antibiotics according to culture and sensitivity. One patient was treated by I.V antibiotics with removal of infected screw. One of our patient came with implant exposure with infection after 10weeks of postoperative period which necessitates implant removal

and it was done with application of knee spanning external fixator. Fracture united in 14 weeks and external fixator was removed. [38]In our study the deep infection rate was 3.7 %.This is explained by MIPPO technique associated with reduced deep infection and overall deep infection rate in LCP group is 4-8%.[6]

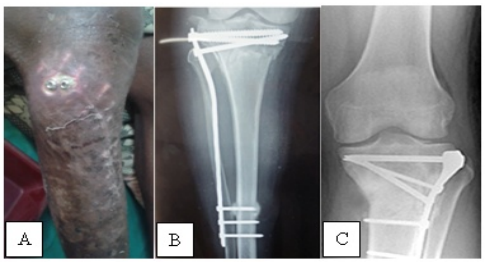

Figure 4: Complications (A) Infection with exposed implant (B) Distal screw site infection (C) Secondary Varus deformity

One of our cases developed varus deformity due to secondary loss of reduction for which corrective osteotomy was planned. In our case we didn't use lag screw for fixation. Postoperative varus collapse can be prevented by accurate reduction, proper positioning of the implant, lag screw application and posteromedial buttress plating. Out Of 27 patients, 19 had excellent functional outcome, six had good functional outcome and only two cases had a fair outcome according to Knee Society Score. In the study by Eggli[39]*et al*, out of 14 patients, 11 had very good functional outcome and three had good functional outcome as perLyshom knee score. Medial proximal tibial angle (MPTA) measurement was undertaken to assess varus/valgus malunion postoperatively. The normal value of MPTA is 87+/-5 degrees.[8] In our series, the average value was 85.4 degrees (range 83 – 91degrees). Thus, we found that the normal proximal tibial joint orientation is maintained after application of LCP.[40] Articular step off was assessed with less than or equal to 2 mm stepoff kept as acceptable limit. In our series, 2 cases had articular step off more than 2 mm (range 3 – 5 mm) and 25 cases had the acceptable result of less than or equal to 2 mm step off. This is comparable to the result published by Eggli *et al*. They reported 85% accurate articular reconstruction in their series of 14 patients.

CONCLUSION

At the end of our study, following conclusions could be drawn from the treatment of proximal tibial fracture with locking compression plate.

- Early mobilization is possible with LCP because of absolute stability given by the implant and this contributes to better knee range of motion.
- Medial condyle coronal fracture and small posteromedial fragment should be buttressed by posteromedial plating.
- LCP gives the promising results in osteoporotic bones.It prevents collapse of fracture both intraoperatively and postoperatively.
- Not all bicondylar fractures are same,treatment should be precised to individual fracture pattern.
- Bicondylartibial plateau fractures treated with locking compression plate, especially using MIPPO technique have an excellent to good functional outcome with very minimal wound complications.

REFERENCES

1. Sir Robert Jones: Orthopaedic surgery of injuries Vol.1, 86, 1921.
2. Sirkin MS, Bono CM, Reilly MC and Behrens FF, Percutaneous methods of tibial plateau fixation. *ClinOrthop 2000 June, 375; 60-68.*
3. Schatzker J, McBroom R, Bruce D. The tibial plateau fractures. Toronto experience.*ClinOrthop 1979; 138: 94.*
4. Dias JJ, Stirling AJ, Finlay DB, *et al*, Computerised axial tomography for tibial plateau fractures. J Bone Joint Surg Br. 1987, 69; 84-88.
5. Tscherne H, Lobenhoffer P: Tibial plateau fractures: Management and expected results. ClinOrthop 292: 87-100, 1993.
6. Single Lateral Locked Screw Plating of Bicondylartibial plateau fractures, T.Gosling MD; P.Schandelmaier, MD; M.Muller, MD; S.Hankemeier, MD ; M.Wagner, MD ; and C.Krettek, FRACS Number 439, pp.207-214.
7. Less Invasive Stabilization of Complex tibial plateau fractures/ Biomechanical Evaluation of a Unilateral Locked Screw Plate and Double Plating, T.Gosling, MD ; P.Schandelmaier, MD; A.Marti, PhD, T.Hufner, MD, A.Partenheimer, MD, and C. Krettek, FRACS (J Orthop Trauma 2004; 18: 546-551)
8. Barei DP, Nork SE, Mills WJ, *et al*. Complications associated with internal fixation of high-energy bicondylartibial plateau fractures utilizing a two incision technique. J Orthop Trauma.2004; 18: 649-657.
9. Tscherne H, Lobenhoffer P. Tibial plateau fractures. Management and expected results. ClinOrthopRelat Res. 1993; 292 : 87-100.

10. Weil *et al*, Posteromedial Supine Approach for Reduction and Fixation of Medial and BicondylarTibial Plateau Fractures. J Orthop Trauma 2008; 22: 357-362.
11. V Musahl *et al*, New trends and techniques in open reduction and internal fixation of fractures of tibial plateau. J Bone and Joint Surg (Br) 2009; 91-B: 426-33.
12. Kropp RJ, MalkaniAL, Roberts CS, Seligson D, Craford CH, Smith LBS. Treatment of BicondylarTibial Plateau Fractures Using Locked Plating Versus External Fixation. *Orthop 2009 Aug; 32(8): 559*
13. SumitArora *et al*, Salvage of proximal tibial fracture treated with locked compression plate. J ClinOrthopand Trauma- June 2012 (Vol.3,Issue 1, pages 58-61, DOI: 10.1016/j.jcot.2011.10.001)
14. Blokker CP, Rorabeck CH, Bourne RB. Tibial Plateau Fractures.An analysis of the results of treatment in 60 patients.ClinOrthop 182; 193, 1984.
15. Whittle AP, Wood II GW. Fracture of lower extremity. Chapter 51.in Campbell operative orthopaedics.Canale ST ed.10thedn, Vol.3, New York, Mosby; 2003.p.2782-2796.
16. Ali, Ahmad M, Saleh, Michael, Bolongaro, Stefano, Yang, Lang. The strength of different fixation techniquesforbicondylartibial plateau fractures – a biomechanical study. Clinical Biomechanics; 2003; 846-870.
17. Management of the Schatzker VI fractures with lateral locked screw plating. Rosario Spagnolo * Fabrizio Pace MusculoskeletSurg (2012) 96 ; 75-80.
18. Kumar A, Whittle AP. Treatment of complex (Schatzker Type VI) fractures of the tibial plateau with circular wire external fixation; Retrospective case review. J Orthop Trauma 14; 339-344, 2000.
19. Muller ME *et al*. The comprehensive classification of fracture of long bones. New york, Springer 1990.
20. Reliability of locked plating in Tibial Plateau Fractures with a medial component, M Ehlingera, M.Rahmea, B.K.Moorb, A.DiMarcoa, D.Brinkerta, P.Adama, F.BonnometaOrthopaedicsand Traumatology; Surgery and Research (2012) 98, 173-179.
21. Beck M, Gradl G, Gierer P, Rotter R, Witt M, MIttelmeier T. Treatment of complicated proximal segmental tibia fractures with the less invasive stabilization locking plate system. Unfallchirung 2008; 111: 493-8.
22. Biggi F, Di Fabio S, D' Antimo C, Trevisani S. Tibial Plateau Fractures; internal fixation with locking plates and the MIPPO techniques. Injury 2010; 41: 1178-82.
23. Boldin C, Finkhauser F, Hofer HP, Szyzkowitz R. Three year results of proximal tibia fractures treated with LISS. ClinOrthop 2006; 445; 222-9.
24. Haiduewych G, Sems SA, Huebner D, Horwitz D, Levy B. Results of polyaxial locked plate fixation of periarticular fractures of the knee. Surgical technique. J Bone Joint Surg (Am) 2008; 90(Suppl.2): 117-34.
25. Phisitkul P, McKinley TO, Nepola JV, Marsh JL. Complications of locking plate fixation in complex proximal tibial injuries. J Orthop Trauma 2007; 21: 83-91.
26. Ricci WM, Rudzki JR, Borelli J. Treatment of complex proximal tibia fractures with the less invasive skeletal stabilization system. J Orthop Trauma 2004; 18: 521-7.
27. Stannard JP, Wilson TC, Volgas DA, Allonso JE. Fracture stabilization of proximal tibial fractures with the proximal tibial LISS; early experience in Birmingham. Alabama (USA). Injury 2003; 34(Suppl.1): A36-42.
28. Berkson EM, Virkus WW (2006) High-energy Tibial Plateau Fractures. J Am AcadOrthopSurg 14(1); 20-31.
29. Schandelmaier P, Gossling T, Partenheimer A, Krettek C. Distal fractures of the femur. Chirurg 73; 1221-1233, 2002. (in German)
30. Babst R, Hehli M, Regazzoni P. LISS tractor, Combination of the "Less Invasive Stabilization System"(LISS) with the AO distractor for distal femur and proximal tibial fractures. Unfallchirurg 104; 530-535, 2001 (in German).
31. Nana AD, Joshi A, Lichtman DM. Plating of the distal radius. J Am AcadOrthop Surg. 2005; 13: 159-171.
32. Lamontagne J, Blachut PA, Broekhuyse HM, *et al*. Surgical treatment of a displaced lateral malleolus fracture; the antiglide technique versus lateral plate fixation. J Orthop trauma 2002; 16 : 498-502.
33. Bai B, Kummer FJ, Sala DA, *et al*. Effect of articular step-off and meniscectomy on joint alignment and contact pressures for fractures of the lateral tibial plateau. J Orthop trauma 15; 101-106, 2001.
34. Gerich T, Blauth M, Witte F, Krettek C; Osteosynthesis of fractures of the head of the tibia in advanced age: A matched-pair analysis. Unfallchirurg 104: 50-56, 2001 (in German).
35. Tscherne H, Lobenhoffer P. Tibial plateau fractures. Management and expected results. ClinOrthop 292; 87-100, 1993.
36. Higgins TF, Klatt J, Bachus KN. Biomechanical analysis of bicondylartibial plateau fixation; how does lateral lockingplate fixation compare to dual plate fixation? J Orthop trauma 2007; 21: 301-306.
37. Functional and radiological evaluations of high-energy tibial plateau fractures treated with double buttress plate fixation. Z.yu, l.zheng, y.zhang, j.li, b.ma Eur J Med Res (2009) 14; 200-205.
38. Reliability of locked plating in tibial plateau fractures with a medial component, m.rahmea, b.-k.moorb, a.dimarcoa, d.brinkerta, p.adama, f.bonnometa, Orthopaedicsand traumatology; Surgery and Research (2012) 98, 173-179.
39. Eggli *et al*. Unstable bicondylartibial plateau fractures. A clinical investigation. J Orthop Trauma 2008; 22: 673-679.
40. The Journal of bone and joint surgery. jbjs.org volume 88-a. number 8- August 2006.
41. Koval KJ, Hulfut DL. Tibial plateau fracture: evaluation and treatment. J Am AcadOrthopSurg 1995; 3(2): 86-94.
42. Wagner M.General principles for the clinical use of the LCP. Injury 2003 Nov; 34, Suppl 2: B31-42.

.

Source of Support: None Declared
Conflict of Interest: None Declared