

Hodgkins lymphoma presenting as a solitary bone tumor: A case report

Manimaran Karthikeya Pandian^{1*}, Varaprasad Sagiraj², Indhumathy K³

¹Associate Professor, ²Resident, Department of Orthopaedics, Government Medical College, Omandurar Government estate, Chennai, Tamil Nadu, INDIA.

³Consultant Pathologist, Anderson Diagnostics and Labs, 150, P. H. Road, Chennai-600084, Tamil Nadu, INDIA.

Email: dr.varam@gmail.com

Abstract

Abstract: Primary lymphoma of the bone is the bone involvement by malignant lymphoid infiltrate without the involvement of lymph nodes or other tissues. Differential diagnoses for the primary bone lymphomas include chronic osteomyelitis, primary bone sarcoma, Ewing's sarcoma, metastatic sarcomas, leukemic infiltrate and carcinoma. Lymphomas of the bone are commonly misdiagnosed as Ewing's sarcoma. We report a case of 16 years old male, who presented with pain in the Right hip and difficulty in walking that had persisted for 2 months with no history of trauma. The patient was initially diagnosed as a case of PLB of the right acetabulum confirmed by open biopsy but the FDG-PET-CT examination was done which showed an abnormally high uptake of F-FDG in the cervical, mediastinal, retroperitoneal, iliac lymphnodal groups, skeletal system, liver and spleen and Immunohistochemistry favoured the diagnosis of Classical Hodgkins lymphoma, mixed cellularity type. He was classified as stage IV B Cell lymphoma and referred to oncology department for favour of chemotherapy and radiotherapy.

Keywords: B-cell lymphoma, Primary bone lymphoma (PBL), diagnosis, therapy, Hodgkins lymphoma.

* Address for Correspondence:

Dr Manimaran Karthikeya Pandian, 4B, Shera Garden Apartments, No:2, Appa Garden street, Off Taylors Road, Kilpauk, Chennai-600010, Tamil Nadu, INDIA.

Email: dr.varam@gmail.com

Received Date: 04/08/2016 Revised Date: 14/09/2016 Accepted Date: 30/10/2016

Access this article online

Quick Response Code:	Website: www.statperson.com
	DOI: 02 November 2016

INTRODUCTION

We report a case of 16 years old male, who presented with pain in the Right hip and difficulty in walking that had persisted for 2 months with no history of trauma. On clinical examination patient had no obvious external swelling, tenderness and he had painful range of motion right hip and scarpa triangle tenderness on the right hip. Plain X-rays showed ill defined geographical lesion of the pelvic bones. Laboratory investigations showed normal blood counts with increased C - reactive protein (i.e. 38.9mg/L). Magnetic resonance imaging (MRI) of the

right hip was performed and showed bone marrow edema involving the acetabular region and adjoining iliac bone, pubic bone and ischium on the right side suggestive of Transient osteoporosis/transient marrow edema. ^{99m}Tc - MDP Whole body Three phase skeletal scintigraphy and SPECT/CT showed abnormal focal uptake of Tc-MDP in the pelvis suggestive of active infective pathology in the right acetabulum, right iliac bone, body of pubis, inferior pubic ramus and superior pubic ramus. Histopathologic examination of Right iliac bone biopsy showed bony trabeculae and hematopoietic marrow with focal edema with small aggregates of lymphocytes with histiocytes in the marrow. A definite epithelioid granuloma with giant cells are not present and result was focal lymphoid aggregates. Immunohistochemistry showed positive for markers CD68 in benign histiocyte and negative for CD1a marker and favoured the diagnosis of inflammatory pathology. Repeat Immunohistochemistry after open biopsy showed positive for markers CD 3, CD20, CD30, CD 138 and faint positivity for PAX5, and negative for CD1a, LCA, CD15, LMP, ALK-1, OCT2, BOB-1, PLAP and PANCK marker and favoured the diagnosis of Classical Hodgkins lymphoma, mixed

cellularity type. An ¹⁸F-fluorodeoxyglucose-positron emission tomography-computed tomography(18 FDG-PET-CT) scan was performed to identify the original site of the tumor. Abnormal ¹⁸F-FDG uptake was found cervical, mediastinal, retroperitoneal, iliac lymphnodalgroups, skeletal system, liver and spleen consistent with stage IV Lymphoma. Patient was referred to oncology department for favour of further management. Further Follow up study is needed to ascertain prognosis. Primary lymphoma of the bone (acetabulum) PLB is an extranodal lymphoma which represents about 3% of primary malignant bone tumors and 1% of malignant lymphomas 1). It manifests as a solitary, localized lesion and usually arises from the medullary cavity. PLB, an extremely rare condition was first described by Oberling in 1928 2). In PLB, any part of the skeleton can be involved and the cause is not known well 3). The cell subtype varies with regard to PLB and the molecular features of PLB have not been well studied 4). Staging differs with different criteria 5). In PLB Imaging features are usually non-specific 6). It is very important to differentiate PLB from other causes of lytic bone lesions, such as primary bone tumors and carcinomas as it is easily curable. Improved prognosis has been noted following chemotherapy and radiotherapy in

PLB patients 7). Written informed consent is obtained from the patient. We report a case of Hodgkins lymphoma which presented as a solitary bone tumor in our current study which posed a great challenge during diagnosis, initially diagnosed as a case of Primary lymphoma of the bone and later upon FDG-PET-CT examination done which showed an abnormally high uptake of ¹⁸F-FDG in the cervical, mediastinal, retroperitoneal, iliac lymphnodalgroups, skeletal system, liver and spleen and **Immunohistochemistry** favoured the diagnosis of Classical Hodgkinslymphoma, mixed cellularity type. He was classified as stage IV B Cell lymphoma and referred to oncology department for favour of chemotherapy and radiotherapy.

CASE REPORT

A 16-year-old male presented with pain in the right hip and difficulty in walking that had persisted for 2 months with no history of trauma. On clinical examination patient had no obvious external swelling, tenderness and he had painful range of motion right hip and scarpa triangle tenderness on the right hip. Plain X-rays of pelvis with both hip showed ill defined geographical lesion of the pelvic bones,. (Fig 1.1 and 1.2)

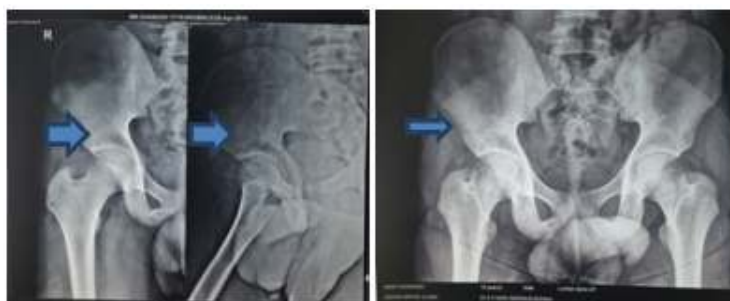
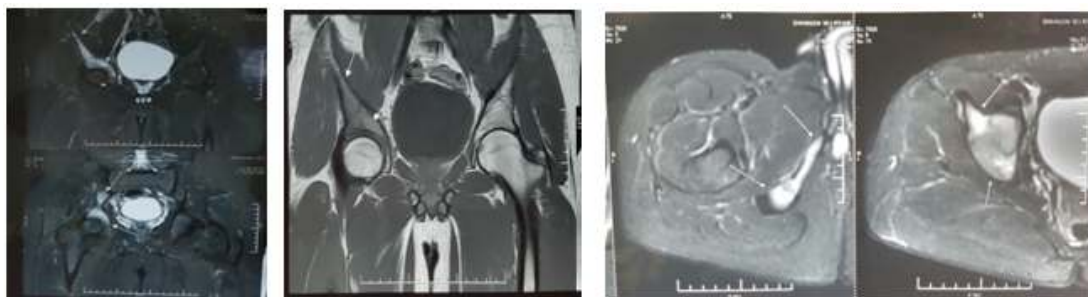
Figure 1.1 and 1.2: Plain X-rays showed ill defined geographical lesion of the pelvic bones

Magnetic resonance imaging (MRI) of the right hip (Fig 2.1, Fig 2.2, Fig 2.3 and Fig 2.4) and CT (Fig 2.5 and 2.6) was performed and showed bone marrow edema involving the acetabular region and adjoining iliac bone, pubic bone and ischium on the right side suggestive of

Transient osteoporosis/transient marrow edema (minimal sclerotic regions/subtle cortical thickening in inferior pubic ramus may be sequelae of insufficiency fracture and suggested follow up).



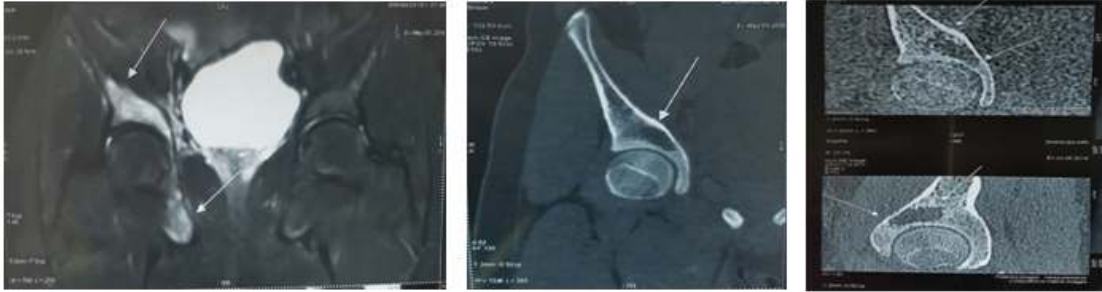

Figure 2.1 to 2.6: Magnetic resonance imaging (MRI) of the right hip(Fig 2.1, Fig 2.2, Fig 2.3, Fig 2.4) and CT (Fig 2.5, Fig 2.6) showed bone marrow edema involving the acetabular region and adjoining iliac bone, pubic bone and ischium on the right side suggestive of Transient osteoporosis/transient marrow edema.

CRP results showed positive 38.9 mg/dl and ESR high. Quantiferon TB Gold showed negative results. Technetium Tc 99m methylene diphosphonate (99mTc – MDP) Whole body Three phase skeletal scintigraphy(Fig 3.1, Fig 3.2) and SPECT/CT showed abnormal focal

uptake of Tc-MDP in the pelvis suggestive of active infective pathology in the right acetabulum, right iliac bone, body of pubis, inferior pubic ramus and superior pubic ramus.

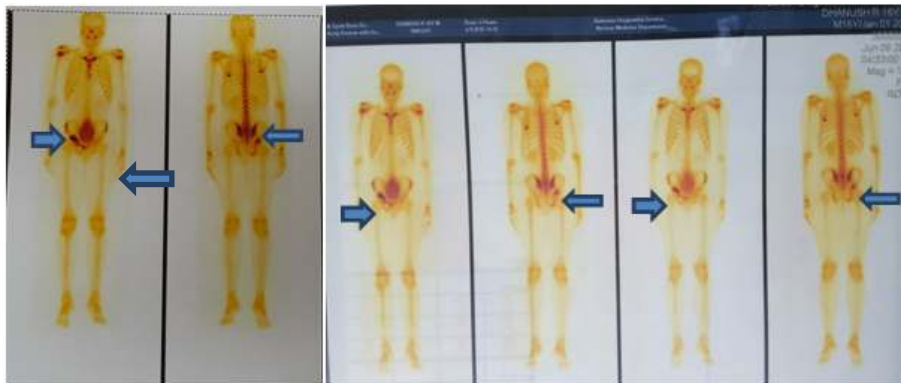


Fig 3.1 and Fig 3.2: Anterior and posterior radionuclide bone scans above depict an abnormally high distribution of technetium-99m in the right acetabulum, right iliac bone, body of pubis, inferior pubic ramus and superior pubic ramus.(arrow).

Hence CT guided biopsy and histopathological examination was planned. Aspiration for AFB showed negative smear for AFB. Culture and sensitivity of the tissue showed no bacterial growth. Histopathologic examination of Right iliac bone biopsy showed bony trabeculae and hematopoietic marrow with focal edema with small aggregates of lymphocytes with

histiocytes in the marrow. A definite epithelioid granuloma with giant cells are not present and result was focal lymphoid aggregates. Immunohistochemistry showed positive for markers CD68 in benign histiocyte and negative for CD1a marker and favoured the diagnosis of inflammatory pathology.(Fig.4).



Figure 4: Immunohistochemistry showed positive for markers CD68 in benign histiocyte and negative for CD1a marker.

Empirical ATT started for 1 month as the location is difficult to access, bone scan suggested infective pathology with negative culture, HPE suggestive of small aggregates of lymphocytes with histiocytes in the marrow and IHC favoured inflammatory pathology. Patient showed some improvement in pain for 1 week and after that he started to have increased pain. Repeat MRI was done as the patient had increased pain. Repeat MRI (Fig

5.1, Fig 5.2, Fig 5.3) showed osteolytic lesion with bone marrow edema in the acetabulum of right iliac bone. Bone marrow edema in the ischium and pubic bones on the right side of pelvis. Mild increase in size of the lesion and bone marrow edema is noted when compared to the previous scan and suggested for Clinical and Histopathological correlation. Repeat CT (Fig.5.4) was also done.

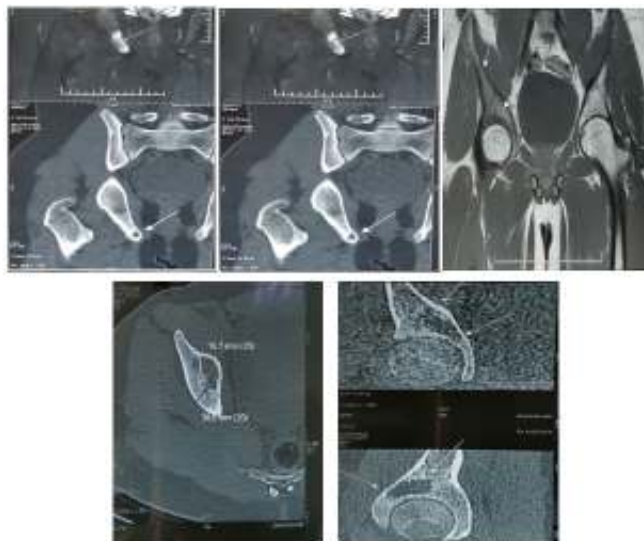


Figure 5.1, Fig 5.2, Fig 5.3: Repeat Magnetic resonance imaging (MRI) of the right hip shows osteolytic lesion with mild increase in size of the lesion and bone marrow edema is noted in the ischium and pubic bones on the right side of pelvis when compared to the previous scan and suggested for Clinical and Histopathological correlation. Repeat CT (Fig.5.4) was also done.

Hence Open biopsy of the acetabular lesion was planned.

Approach

Through Lateral Hardinge approach incision (Fig 6.1, Fig 6.2), stab incision is made over the Gluteus medius without disturbing the neurovascular bundle (Superior

Gluteal artery and nerve) in order to avoid postoperative abduction lurch, supraacetabular biopsy under C-ARM guidance (Fig 7.1, Fig 7.2) was taken and curettage of the lesion done and specimen sent for histopathological and immunohistochemistry evaluation.

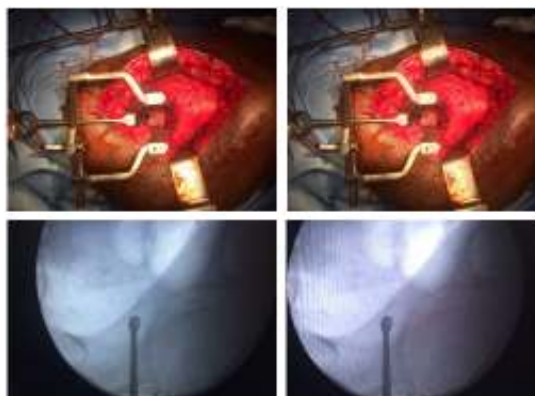


Figure 6.1: Figure 6.2: Open biopsy of the acetabular lesion through lateral Hardinge approach incision

Figure 7.1: Figure 7.2: Supra acetabular biopsy under C-ARM guidance was taken and curettage of the lesion done.

Gene Xpert MTB/RIF resistance detection assay from supraacetabular region tissue showed negative results for Mycobacterium tuberculosis.

Histopathology showed detached fragment of bony spicules. Amidst these are seen fibrocollagenous tissue showing patchy areas of atypical mononuclear round cell infiltrates with some crush artefact changes. Atypical lymphoid infiltrates, shows scattered prominent thick nuclei with prominent pinkish macro nucleoli suggestive of Reed Sternberg cell. (Fig 8.1, Fig 8.2). Amidst atypical

lymphoid cells are seen a brisk fibroblastic proliferation and patchy areas of granulation tissue and histiocytic reaction suggestive of atypical lymphoid infiltrates, suspicious of Lymphoma. Differential diagnoses include Hodgkins Lymphoma which is confirmed and subcategorized by Immunohistochemistry (IHC).

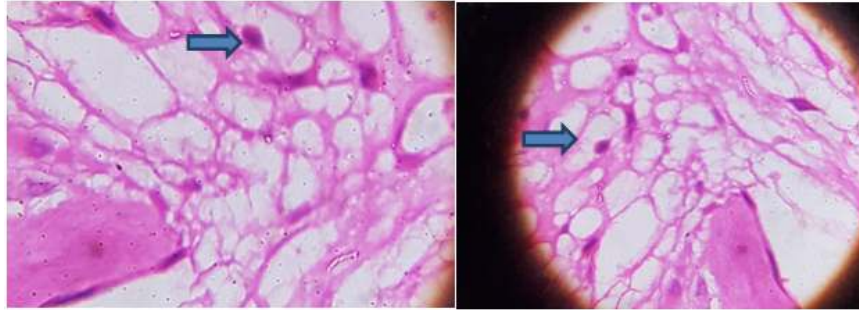


Figure 8.1: Figure 8.2: Histopathology image showing atypical lymphoid infiltrates, scattered prominent thick nuclei with prominent pinkish macro nucleoli suggestive of Reed Sternberg cell (arrow).

Immunohistochemistry subtyping

Immunohistochemistry showed positive for markers CD 3, CD20, CD30, CD 138 and faint positivity for PAX5, and negative for CD1a, LCA, CD15, LMP, ALK-1, OCT2, BOB-1, PLAP and PANCK marker and favoured the diagnosis of Classical Hodgkins lymphoma, mixed cellularity type.

FDG PET CT

An ^{18}F -fluorodeoxyglucose positron emission tomography (FDG-PET) CT scan was done to identify the original site of the tumor. Abnormal ^{18}F -FDG uptake was found cervical, mediastinal, retroperitoneal, iliac lymphnodal groups, skeletal system, liver and spleen consistent with stage IV Lymphoma. Patient was referred to oncology department for favour of further management. Further Follow up study is needed to ascertain prognosis.




Figure 9.1, 9.2 and 9.3: FDG-PET-CT scan of the whole body. FDG-PET-CT scan results showed an abnormally high uptake of ^{18}F -FDG in the cervical, mediastinal, retroperitoneal, iliac lymphnodal groups, skeletal system, liver and spleen.

Histopathological picture of the biopsy from right pelvis revealed detached fragment of bony spicules. Amidst these are seen fibrocollagenous tissue showing patchy areas of atypical mononuclear round cell infiltrates with some crush artefact changes. Atypical lymphoid infiltrates, shows scattered prominent thick nuclei with prominent pinkish macro nucleoli suggestive of Reed Sternberg cell. Amidst atypical lymphoid cells are seen a brisk fibroblastic proliferation and patchy areas of granulation tissue and histiocytic reaction. Suggestive of

atypical lymphoid infiltrates suspicious of Lymphoma. Differential diagnoses include Hodgkins Lymphoma which is confirmed and subcategorized by Immunohistochemistry (IHC). Furthermore, on performing immunohistochemistry, the neoplastic cells were positive for markers CD 3, CD20, CD30, CD 138 and faint positivity for PAX5, and negative for CD1a, LCA, CD15, LMP, ALK-1, OCT2, BOB-1, PLAP and PANCK marker and favoured the diagnosis of Classical Hodgkins lymphoma, mixed cellularity type. The patient

was initially diagnosed as a case of PLB of the right acetabulum confirmed by open biopsy but the FDG-PET-CT examination was done which showed an abnormally high uptake of ^{18}F -FDG in the cervical, mediastinal, retroperitoneal, iliac lymphnodal groups, skeletal system, liver and spleen. Immunohistochemistry favoured the diagnosis of Classical Hodgkins lymphoma, mixed cellularity type. He was classified as stage IV B Cell lymphoma and referred to oncology department for favour of chemotherapy and radiotherapy.

CONCLUSION

This case brings us to the fact that, the solitary bone tumors should be thoroughly investigated. The immunohistochemistry and FDG PET CT is potentially the most reliable diagnostic aid in the definitive diagnosis of Hodgkins lymphoma presenting as solitary bone tumors^{8,9,10}. This would enable the patient of neo-adjuvant chemotherapy in advanced malignancy at the earliest and improved prognosis. Follow up study of this patient is needed for further insight into the treatment outcome and prognosis of this patient. The patient was being followed up and he is currently undergoing chemotherapy (completed 4 cycles).

REFERENCES

1. Singh T, Satheesh CT, Lakshmaiah KC, Suresh TM, Babu GK, Lokanatha D, Jacob LA, Halkud R. Primary bone lymphoma: a report of two cases and review of the literature. *J Cancer Res Ther.* 2010; 6:296–298. [PubMed]
2. Oberling C. The reticulosarcomas and the reticulotheliomas of Ewing's osterosarcoma. *Bull AssocFr Etude Cancer (Paris)* 1928; 17:259–296. (In French)
3. Heyning FH, Hogendoorn PC, Kramer MH, Hermans J, Kluin-Nelemans JC, Noordijk EM, Kluin PM. Primary non-Hodgkin's lymphoma of bone: a clinicopathological investigation of 60 cases. *Leukemia.* 1999; 13:2094–2098. [PubMed]
4. Lewis VO, Primus G, Anastasi J, Doherty D, Montag AG, Peabody TD, Simon MA. Oncologic outcomes of primary lymphoma of bone in adults. *ClinOrthopRelat Res.* 2003; 415:90–97. [PubMed]
5. Jawad MU, Schneiderbauer MM, Min ES, Cheung MC, Koniaris LG, Scully SP. Primary lymphoma of bone in adult patients. *Cancer.* 2010; 116:871–879. [PubMed]
6. Mulligan ME, McRae GA, Murphey MD. Imaging features of primary lymphoma of bone. *AJR Am J Roentgenol.* 1999; 173:1691–1697. [PubMed]
7. Ramadan KM, Shenkier T, Sehn LH, Gascoyne RD, Connors JM. A clinicopathological retrospective study of 131 patients with primary bone lymphoma: a population-based study of successively treated cohorts from the British Columbia Cancer Agency. *Ann Oncol.* 2007; 18(1):129–135. [PubMed]
8. O'Connor AR, Birchall JD, O'Connor SR, Bessell E. The value of $^{99\text{m}}\text{Tc}$ -MDP bone scintigraphy in staging primary lymphoma of bone. *Nucl Med Commun.* 2007; 28:529–531. [PubMed]
9. Park YH, Choi SJ, Ryoo BY, Kim HT. PET imaging with F-18 fluorodeoxyglucose for primary lymphoma of bone. *ClinNucl Med.* 2005; 30:131–134. [PubMed]
10. Park YH, Kim S, Choi SJ, Ryoo BY, Yang SH, Cheon GJ, Choi CW, Lim SM, Yoo JY, Lee SS. Clinical impact of whole-body FDG-PET for evaluation of response and therapeutic decision-making of primary lymphoma of bone. *Ann Oncol.* 2005; 16:1401–1402. [PubMed]

Source of Support: None Declared
Conflict of Interest: None Declared