

Hydrocele of canal of Nuck

R Sharanya^{1*}, K Jawahar², Khalilur Rahman³, R Samson⁴

¹Post Graduate Resident, ²Professor and Unit Chief, ³Associate Professor, ⁴Assistant Professor, Department of General Surgery, Saveetha Medical College and Hospital, Thandalm, Tamil Nadu, INDIA.

Email: sharu_ravi@yahoo.com

Abstract

Female hydrocele or Hydrocele of the canal of Nuck, is very rare in females, mainly due to a developmental disorder presenting clinically as an inguino-labial swelling. The usual content of this sac is fluid being secreted by the peritoneum. The processes vaginalis accompanies the round ligament through the inguinal canal into the labium majora. This evagination of the parietal peritoneum forms the canal of Nuck in the female which normally loses its connection during the first year of life, but failure to close can result in a hernia or hydrocele.

Keywords: Hydrocele, canal of Nuck, around ligament.

*Address for Correspondence:

Dr. R. Sharanya, R.Sharanya, G-34 Madura Gardens, #15 PH road Maduravoyul, Chennai-95, Tamil Nadu, INDIA.

Email: sharu_ravi@yahoo.com

Received Date: 16/10/2016 Revised Date: 06/11/2016 Accepted Date: 01/12/2016

Access this article online

Quick Response Code:



Website:

www.statperson.com

DOI: 12 December
2016

INTRODUCTION

Hydrocele of the canal of Nuck is the female equivalent of a spermatic cord hydrocele in males; thus, this entity is called the “female hydrocele”¹. The processes vaginalis arises as an evagination of the parietal peritoneum. During embryogenesis, the processes vaginalis accompanies the round ligament or testis as it passes through the inguinal canal into the labium majora or scrotum, respectively. The canal of Nuck normally undergoes complete obliteration during the first year of life, and its failure to do so may result in an inguinal hernia or a hydrocele. While preoperative diagnosis of this type of inguinal region hydrocele is important, the diagnosis of a hydrocele of the canal of Nuck is quite difficult. The female hydrocele is equivalent to an encysted hydrocele of the spermatic cord in the male. The cysts seldom exceed 3 cm in length with a diameter of 0.3–0.5 cm².

CASE REPORT

A 26-year-old female presented with swelling in the right inguinal region for past five months which was initially small in size and gradually increased to attain the present size. No complaints of pain. On physical examination, a soft mass measuring approximately 4X 4 cm in diameter was palpable in the right inguinal region. Patient's vital signs and laboratory data were normal, with no history of local trauma noted. An oval swelling of size 5X4 cm was seen in the right inguinolabial region, extending from 4 cm from mid inguinal point, 8 cm from ASIS and 2 cm from pubic tubercle. Skin over the swelling is normal. Not warm, not tender, cystic in consistency, brilliantly transilluminant, no palpable cough impulse, not reducible and left inguinal region was normal.

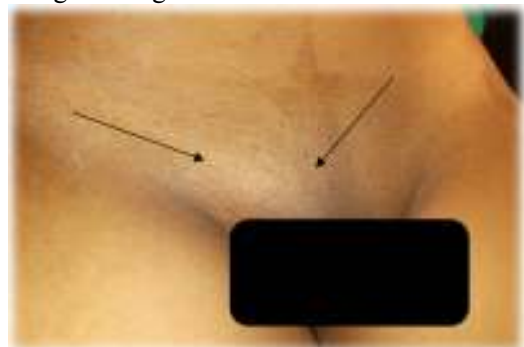


Figure 1: Right inguino labial swelling

Pt was admitted and blood investigation were done which were normal and ultra-sonogram was done which showed : encysted hydrocele of the canal of Nuck

Pt was evaluated for surgery and was posted under SA after obtaining consent, R groin crease incision was made and opened in layers.

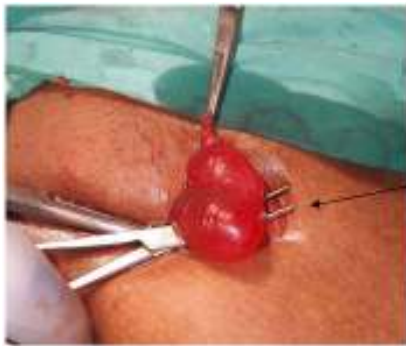

Figure 2: Right groin crease incision made and hydrocele sac identified by black arrow

Hydrocele sac was seen around the round ligament. Sac was separated, opened and contents [amber coloured] were drained. Proximal sac was laid open and marsupialisation was done leaving the round ligament intact. Haemostasis was secured. Incision was closed in layers.

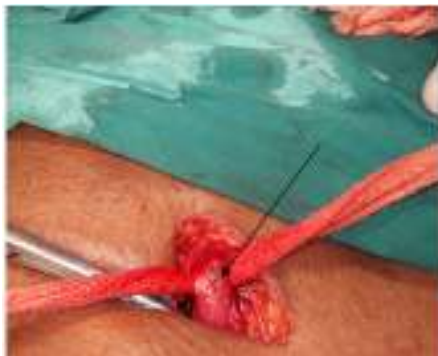

Figure 3: After marsupialisation, round ligament intact shown by a black arrow

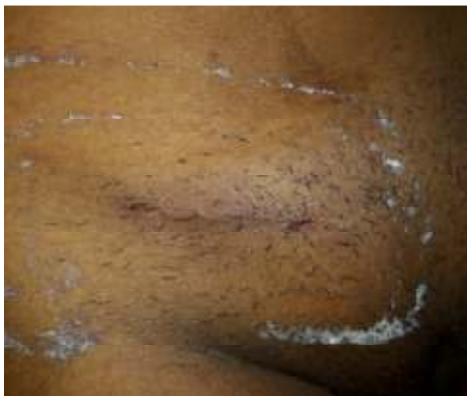

Figure 4: Post operative day seven.

Patient on discharge on post-operative day seven and it was uneventful.

DISCUSSION

Female hydrocele, also named as hydrocele canal of Nuck or cyst of the canal of Nuck, is a very unusual and rare diagnosis with only about 400 reported cases in the literature.^{1,2} Normally in humans the peritoneal evagination undergoes obliteration soon after birth. If it remains completely patent, it forms a pathway for an indirect inguinal hernia. Partial proximal obliteration, which leaves the distal portion of the processes vaginalis open, leads to development of a hydrocele of the spermatic cord and a cyst of the canal of Nuck, in males and females respectively.²⁻⁴ The reason for development of hydrocele would be due to an imbalance of fluid secretion and absorption by the secretory membrane lining the processes vaginalis. Hypersecretion or under absorption may result from trauma, inflammation, or improper lymphatic drainage, but in most cases it is idiopathic.⁵⁻⁸ Although the exact process is unclear but according Skandalakis “he stated that obliteration of the processes vaginalis occurs only after the seventh month of gestation”, thus accounting for the higher incidence of inguinal hernias in the premature infant¹⁰. Although not clearly explained, there is a known heredity factor associated with the occurrence of hernias which is more frequently seen in twin gestations and also in infants who have a family history of hernia hereby stating that family history plays an important role in development of hernias and hydrocele¹¹. In most cases, the hydrocele of canal of Nuck should be distinguished from hernia though it very difficult in some cases. Bowel sounds over the swelling are strongly suggestive of a hernia. As in this case hydrocele of the canal of Nuck typically presents as a painless, translucent swelling in the inguinolabial region¹². There is no nausea or vomiting with no signs of intestinal obstruction. If possible, the patient should be examined in the supine and standing positions¹³ and Valsalva’s manoeuvre should be performed to rule out hernia. If the bulge is apparent in the standing position and disappears while supine, a hernia is more appropriate diagnosis than hydrocele¹⁴. Able to get above the swelling also differentiates it from hernia. There are three types of hydrocele of the canal of Nuck. The most common type is the noncommunicating which does not communicate with the peritoneal space and forms an encysted hydrocele along the round ligament, from the inguinal canal to the vulva. The second type is when the communication is persistent with the peritoneal space. The third type is a combination of the first two and the inguinal ring which forms the constricting band around the hydrocele so that one part is communicating and the other part is enclosed, thus giving the name “hour-glass” type¹⁵. Currently, ultra sonogram is the imaging modality of choice for evaluation of this type of mass¹⁶. However, distinguishing the other

diagnosis of inguinolabial swelling from hydrocele of canal of Nuck is quite difficult as it is mostly operator dependant and need for trained sonologist is necessary to make a diagnosis as it may be missed easily. Anderson *et al*¹⁷ stated “a tubular anechoic mass extending along the course of the round ligament without any internal structures, thus representing a unilocular hydrocele”. However, with ultra sonogram, though we may we cannot identify whether there is a communication between cystic mass and peritoneal cavity. MR imaging can give more precise images including communication between cystic lesion and peritoneal cavity and septation, and information on the anatomical relation with adjacent structures^{18,19}. Therefore, MRI can help to diagnose in patients with inguinal cystic mass. It is not absolutely necessary as it mostly on table diagnosis for confirming it. The differential diagnosis of a cystic mass in the female groin region includes. Round ligament cysts, femoral hernia, varicosities of the round ligament, endometrial cyst inguinal herniation of the ovary, cystic lymphangiomas, epidermal inclusion cysts, abscesses, and pseudoaneurysms²⁰. But they are not transilluminant as hydrocele and in endometrial cyst, patients would have cyclical pain with bleeding every month. The treatment of choice is excision of the hydrocele and closure of the enlarged inguinal ring. This is generally done through the inguinal canal by making a groin crease incision with high ligation of the sac and try to preserve the round ligament.

CONCLUSION

A hydrocele of the canal of Nuck, although rare, it should be considered in the differential diagnosis in a case of inguino-labial swelling. Diagnosis is seldom on physical examination; hence, further evaluation with ultrasound or MRI scan imaging will be helpful to reach a diagnosis preoperatively, but mostly it is an intraoperative diagnosis. The treatment of choice for hydrocele of canal of Nuck is complete surgical excision.

REFERENCES

- Ihekwa FN. Hydrocele in the female. J R Coll Surgery Edinb 1981; 26:91–93.
- Kucera PR, Glazer J. Hydrocele of the canal of Nuck: a report of 4 cases. J Reprod Med 1985; 30:439–442
- Janssen K, Klinkner D, Kumar T. Encysted Hydrocele of Canal of Nuck: A Case Report With Review of Literature. Journal of Surgical Technique and Case Report. 2011;3[2]:97–98.
- Schneider CA, Festa S, Spillert CR, Bruce CJ, Lazaron EJ. Hydrocele of the canal of Nuck. NJ Med 1994;91:37–38.
- McElfatrick RA, Condon WB. Hydrocele of the canal of Nuck: a report of 2 cases. Rocky Mt Med J 1975;72:112–113.
- Rathaus V, Konen O, Shapiro M, Lazar L, Grunebaum M, Werner M. Ultrasound features of spermatic cord hydroceles in children. Br J Radiology 2001; 74:818–820.
- Miklos JR, Karram MM, Silver E, Reid R. Ultrasound and hookwire needle placement for localization of a hydrocele of the canal of Nuck. Obstet Gynecol 1995; 85:884–886.
- Merkle P, Schäfer JH. Hydrocele of Nuck’s canal [hydrocele feminae] in childhood [in German]. Bruns Beitr Klin Chir 1974; 221:247–249
- Skandalakis JE, Gray SW, Ricketts RR, Skandalakis LJ. In: Embryology for surgeons: the embryological basis for the treatment of congenital anomalies. 2nd ed. Baltimore: Williams and Wilkins; 1994. pp. 578–580.
- Rescorla FJ, Grosfeld JL. Inguinal hernia repair in the perinatal period and early infancy: clinical considerations. J Pediatr Surg. 1984;19:832–837.
- Czeizel A, Gárdonyi J. A family study of congenital inguinal hernia. Am J Med Genet. 1979;4:247–25
- Graham SD, Jr, Keane TE, Glenn JF. Glenn’s urologic surgery. 7th ed. Philadelphia: Lippincott Williams and Wilkins; 2009. pp. 735–749.
- Counseller V.S., Black B.M. Hydrocele of the canal of Nuck: report of seventeen cases. Ann Surg. 1941;113:625–630.
- Huang CS, Luo CC, Chao HC, Chu SM, Yu YJ, Yen JB. The presentation of asymptomatic palpable movable mass in female inguinal hernia. Eur J Pediatr. 2003;162:493–495. McCune WS.
- Hydrocele of the Canal of Nuck with Large Cystic Retroperitoneal Extension. Ann Surg. 1948;127[4]:750–53.
- Jagdale R, Agrawal S, Chhabra S, Jewan SY. Hydrocele of the Canal of Nuck: Value of Radiological Diagnosis. Journal of Radiology Case Reports. 2012;6[6]:18–22.
- Anderson CC, Broadie TA, Mackey JE, Kopecky KK. Hydrocele of the canal of Nuck: ultrasound appearance. Am Surg 1995; 61:959–196
- Safak AA, Erdogmus B, Yazici B, Gokgoz AT. Hydrocele of the canal of Nuck: sonographic and MRI appearances. J Clin Ultrasound. 2007;35:531–532.
- Oh SN, Jung SE, Rha SE, Lim GY, Ku YM, Byun JY, et al. Sonography of various cystic masses of the female groin. J Ultrasound Med. 2007;26:1735–1742.
- Poenaru D, Jacobs DA, Kamal I. Unusual findings in the inguinal canal: A report of four cases. Pediatr Surg Int. 1999;15:515–16.
- Santanu Sarkar, Soumyajyoti Panja and Sandeep Kumar Hydrocele of the Canal of Nuck [Female Hydrocele]: A Rare Differential for Inguino-Labial Swelling J Clin Diagn Res. 2016 Feb; 10[2]: PD21–PD22.

Source of Support: None Declared
Conflict of Interest: None Declared