

Acute Gall Bladder Volvulus; an Unexpected Abdominal Emergency

Ashish Motewar¹, Mandar Tilak^{2*}, Nikhil Bhamare³

{¹Associate Professor, ²Assistant Professor, ³Resident} Dept of Surgery, Dr Shankarrao Chavan Government Medical College

Nanded (MS) INDIA.

*Corresponding address:

i.mandar@hotmail.com

Case Report

Abstract: Gallbladder Volvulus is a very rare pathology in a patient presenting to the emergency with acute abdominal pain with only 500 cases reported worldwide [1]. The volvulus occurs along the axis of the cystic artery and cystic duct causing infarction and obstruction at the same time and if not diagnosed and treated promptly will lead to gangrenous perforation of the gall bladder, acute septic biliary peritonitis, morbidity and even mortality. Though it can occur in any age group most cases occur in elderly people with a female preponderance [2]. There is no classical clinical as well as radiologic sign for prompt diagnosis. But if a high index of suspicion is maintained and prompt diagnostic laparoscopy is done this acute condition can be satisfactorily treated with laparoscopic cholecystectomy with minimal intra operative difficulty and minimal post operative morbidity.

Keywords: gall bladder, long mesentery, volvulus, acute pain, diagnostic laparoscopy, cholecystectomy

Background:

Gall bladder volvulus is rare cause of acute abdominal pain in right hypochondriac region. The etiopathology lies in either very long mesentery of the gall bladder called floating gall bladder, or very short mesentery of gall bladder limited only to the cystic artery and the cystic duct leading to a vertical orientation of the gall bladder [4]. These along with absence of normal fixation to liver bed, predispose gall bladder to torsional forces leading to volvulus and obstruction.

Case presentation :

A 25 yrs old male patient presented to the emergency ward with acute pain in the right hypochondriac pain since one day, 4 episodes of non-billious vomiting. There was history of mild fever since 1 day. Patient gave no history of jaundice, gall stone disease or acid peptic disease and was non-alcoholic.

On clinical examination, patient was febrile, pulse rate of 110/min, normal blood pressure 120/76 mm of hg. There was no icterus. There were no signs of dehydration. On per abdominal examination there was tenderness in right hypochondriac region with positive Murphy sign. There was localized guarding in the right hypochondriac region. No lump or mass was palpable.

On USG there was loculated collection near the fundus of the gall bladder with thickening of gall bladder wall. No gb calculus was seen. There was mild collection in the pelvis with hypoperistaltic bowel loops. X-ray abdomen standing did not reveal any pathology.

Patient was investigated further. On hematological investigation the only significant finding was leucocytosis with TLC 15000/cmm. There was no increase in hepatic transaminases as well as serum bilirubin.



Figure 1: U.S.G showing edematous gall bladder wall




Figure 2: Usg showing hyperechoic neck region of gall bladder

The radiologic findings suggested a picture of acalculus cholecystitis. But the short duration & absence of contributory history were not matching with diagnosis of acalculous cholecystitis. Thus a decision for diagnostic laparoscopy was taken.

On introduction of scope there was evidence of darkened distended gall bladder with twist at junction of body and neck. Beyond the twist the neck appeared normal. There was collection at the fundus. There was minimal edema in Callot's triangle. Gall bladder fundus appeared to be mobile and not fixed to the liver bed. Thus this is a classic case of floating gall bladder with torsion.

Laparoscopic cholecystectomy was done. Patient recovered well post operatively and was discharged uneventfully on the 5th post operative day.

Intra-operative photographs showing gall bladder torsion.

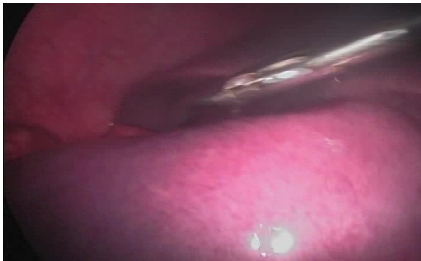

Figure 3: Mobile gall bladder

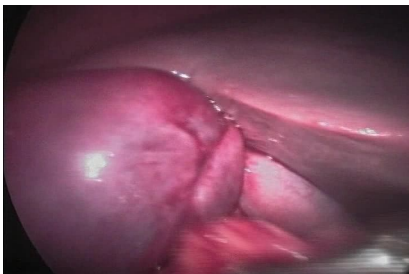

Figure 4: 360 degree torsion at body-neck junction

Discussion:

Gall bladder volvulus or torsion is a rare pathology presenting as acute pain in the right hypochondriac region. With only about 500 cases reported in literature [1]

Wendell first described Gall Bladder volvulus in 1898. [3]. It occurs mostly in elderly patients with average age > 65 years. There is female preponderance with female to male ratio 3:1. However it can present in any age and sex with cases reported in patients as young as 4 and 5 yrs. [2,5]

The anatomical variations of the peritoneal coverings of the gallbladder are

- (1) Completely embedded in the liver;
- (2) Closely attached to the undersurface of the liver by the peritoneum;
- (3) A complete mesentery but held closely to the liver;
- (4) A complete mesentery, which is long and allows the gallbladder to hang freely;
- (5) An incomplete mesentery which is attached along the cystic duct and allows the gallbladder to hang freely in the peritoneal cavity.

Only situations 4 and 5 can predispose to torsion & thus volvulus of the gallbladder [6]

Other precipitating factors are violent peristalsis of the neighboring organs, namely stomach, duodenum and colon, kyphosis, and weight loss in elderly with visceroptosis and atherosclerosis of the cystic artery [7]. The importance of gallstones is unknown;

approximately 70-80% of patients with torsion had no gallstones [8]

Peristalsis of the stomach and duodenum compounds with this mobility leading to volvulus. This can be incomplete at <180 degrees or complete > 180 degrees with sometimes entire 360 degree rotation. [9]. This can occur at site of cystic duct as well as below the neck of the gall bladder especially in cases with very short mesentery.

Volvulus leads to gall bladder wall ischemia with later on necrosis. The obstruction compounds this ischemia and facilitates perforation of the gall bladder wall with release of infected bile which leads to abscess and peritonitis if not contained by the greater omentum. In elderly and debilitated patients this can lead to severe morbidity and septicemia.

The clinical presentation is nonspecific with symptoms mimicking acute cholecystitis as well as acute exacerbation of acid peptic disease. But the acute and very short history with no contributory past history as well as absence of any other disease is a pointer. Clinical examination may sometimes reveal a cystic and slight mobile, very tender mass in the right hypochondriac region lower than the inferior margin of the liver. The short clinical duration points against an empyema of gall bladder.

Laboratory examinations are noncontributory with only positive finding being leucocytosis and elevated CRP which can occur in any acute condition.

Ultrasound studies often reveal a large floating gallbladder without gallstones and a thickened gallbladder wall. Specific ultrasound signs seen with gallbladder torsion include the presence of the gallbladder outside its normal anatomic fossa, inferior to the liver or in a transverse orientation with an echogenic conical structure - the twisted pedicle. [10]

Computed tomographic scan provides similar diagnostic clues with ultrasonography: the presence of gallbladder outside its fossa and inferior to the liver, pericholecystic fluid, and massively distended gallbladder with wall thickening [11]

Magnetic resonance imaging findings include high signal intensity within the gallbladder wall on T1-weighted images suggesting necrosis and hemorrhage and consistent with gallbladder torsion. The magnetic resonance cholangiopancreatography (MRCP) findings were defined by Usui et al.: v-shaped distortion of extrahepatic bile ducts as a result of traction by the cystic duct, tapering interruption of the cystic duct, a distended gallbladder at the end of the cystic duct which was deviated to the midline, and a difference in intensity between the gallbladder and the extrahepatic bile ducts and cystic duct [12]

Although commonly mimicking acute cholecystitis, Lau et. al. proposed 3 triads of clinical diagnosis suggestive of torsion. These include specific symptoms (short history, abdominal pain and early vomiting), physical signs (abdominal mass, absence of toxemia, and a pulse rate-temperature discrepancy) and even physical characteristics (thin, elderly, and deformed spine). [13]

Thus the crux is a high index of suspicion with very short history, acute pain, absence of features of infection, a mobile distended gall bladder if palpable and in usg and ct an inflamed gall bladder lower than its normal anatomic location with pericholecystic collection as pointers.

If diagnostic laparoscopy is done for above findings, quick and confirmatory evidence can be obtained and patient can be effectively treated in same sitting with minimal morbidity.

Principles of laparoscopic management include laparoscopic decompression, detorsion and cholecystectomy with or without intraoperative cholangiogram. Diagnosed early and treated with cholecystectomy, this disease has a low mortality rate of less than 5%. [14]

Conclusion:

Gall bladder volvulus though a rare clinical entity must be kept in mind in sudden or acute right hypochondriac pain with features mimicking acute cholecystitis but of very short duration without contributory history and in especially in elderly females and patients with visceroptosis. By using clinical judgement to correlate with the vague investigatory findings and using early diagnostic laparoscopy this wholly treatable condition can be effectively managed by laparoscopic cholecystectomy with minimal morbidity.

References:

- [1] Chung JC, Song OP, Kim HC. Gallbladder torsion diagnosed by MDCT and MRCP. *Abdom Imaging*, 35: 462-42, 2010.
- [2] Stieber AC, Bauer JJ: Volvulus of the gallbladder. *Am J Gastroenterol* 1983, 78:96- 98. Issue yr 1983
- [3] Wendel AV: A case of floating gallbladder and kidney complicated by cholelithiasis with perforation of the gallbladder. *Ann Surg.*, 27:199-202, 1898.
- [4] Tarhan OR, Barut I, Dinelek H: Gallbladder volvulus: review of the literature and report of a case. *Turk J Gastroenterol*; 17(3):209-211, 2006.
- [5] Kitagawa H, Nakada K, Enami T, Yamaguchi T, Kawaguchi F, Nakada M, Yamate N: Two cases of torsion of the gallbladder diagnosed preoperatively. *J Paediatr Surg.*, 32(11):1567-1569, 1997.
- [6] Chilton CP, Mann CV: Torsion of the gallbladder in a nine-year old boy. *J R Soc Med.*, 73(2):141-143, 1980.
- [7] Levene A. Acute torsion of the gallbladder. *Br J Surg.*, 45: 338-40, 1958.
- [8] Tarhan O, Barut I, Dinelek H. Gallbladder volvulus: a review of the literature and a report of a case. *Turk J Gastro-enterol.*, 17 (3): 209-211, 2006.
- [9] Ashby BS. Acute and recurrent torsion of the gallbladder. *Br J Surg.*, 52:182-4, 1965.
- [10] Safadi RR, Abu-Yousef MM, Farah AS, et al. Preoperative sonographic diagnosis of gallbladder torsion: report of two cases. *J Ultrasound Med.*, 12: 296-8, 1993.
- [11] Aibe H, Honda H, Kuroiwa T, et al. Gallbladder torsion: case report. *Abdom Imaging*, 27: 51-53, 2002.
- [12] Usui M, Matsuda S, Suzuki H, Ogura Y. Preoperative diagnosis of gallbladder torsion by magnetic resonance cholangiopancreatography. *Scand J Gastroenterol*, 35: 218-22, 2000.
- [13] Lau WY, Fan ST, Wong SH. Acute torsion of the gallbladder in the aged: a re-emphasis on clinical diagnosis. *Aust N Z J Surg.*, 52:492-4, 1982.
- [14] Nguyen T, Geraci A, Bauer JJ. Laparoscopic cholecystectomy for gallbladder volvulus. *Surg Endosc.*, 9:519-2, 1995.