

Acute Diarrhoea in a Child: Fish Tape Worm Infestation- *We All May Miss!*

Rabindra Kumar Sahoo^{1*}, Sujata Devi²

{¹Dept of Pediatrics, ²Dept of Medicine} Prathima Institute of Medical Sciences, Karimnagar, Andra Pradesh, INDIA.

*Corresponding Address:

rksbam@yahoo.com

Case Report

Introduction

Diphyllobothrium latum is a platyhelminth otherwise called as fish tapeworm. It is endemic in areas where humans frequently consume raw or pickled fish. *Diphyllobothrium latum* infection is typically an asymptomatic condition. Patients do not usually observe passage of segments in the stool as noted in other tapeworm infections. A few reports have documented patients who presented after vomiting a ball of worms that were determined to be fish tapeworms.

We report a rare case of Fish Tape Worm Infestation that occurred in India.

Case presentation

A nine-year-old girl was admitted with complaints of vomiting, loose stools, low-grade continuous fever from 3 days and recurrent abdominal pain. The vomitus contains undigested food particles. Her stools were watery in consistency, contained no blood or mucus, and the patient showed no signs of dehydration. She reported no history of similar complaints or any previous hospitalization. A general physical examination revealed the patient to be moderately built and dull looking, with normal vitals.

Investigations

Hemogram showed macrocytic- anemia. Stool examination showed the presence of operculated eggs measuring 75 μm \times 40 μm (Figure 1). scolex of the tapeworm along with gravid proglottids (Figure 2). On the basis of the morphology of the eggs with operculum and the presence of broader than long segments, as well as the scolex, the parasite was identified as *Diphyllobothrium* spp.

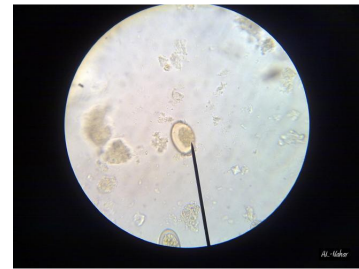

Figure 1

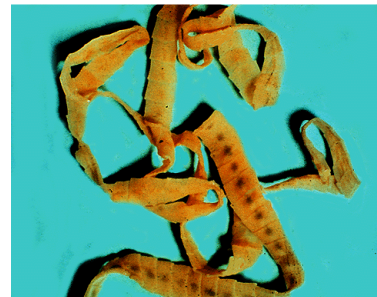


Figure 2

Discussion

Diphyllobothrium genus belongs to the order Diphyllobothridea. *D. latum*, commonly referred to as “fish tapeworm,” infects humans [1]. *Diphyllobothriasis* causes minimal local pathology, but is responsible for reduced vitamin B12 absorption and altered gut mobility [2]. The common symptoms include diarrhea, vomiting, low grade fever, and abdominal discomfort. *Diphyllobothriasis* is associated with eating raw fish and is endemic to Serbia, Scandinavia, North America, Japan, and Chile, with more than 2% prevalence worldwide. A detailed review of the previous literature revealed that only three previous cases [3-5] in India all from southern India and all were in pediatric patients, in contrast to what has been observed in recent Korean cases of *diphyllobothriasis*, which involved middle-aged individuals [6]. In contrast to what was observed in previous studies, our patient showed no marked eosinophilia and presented with mild fever [3]. The child

was treated with single dose of praziquantel(10mg/kg) and B12,Folic acid supplementation. Parents were counselled. Repeat stool examination found normal.

Conclusion

We emphasize the need for pediatricians to suspect Fish Tape Worm Infestation in acute diarrhoea in children and treat this infestation with single dose of Praziquantel.

References

1. Rausch RL, Scott EM, Rausch VR: Helminths in Eskimos in western Alaska, with particular reference to Diphyllbothrium infection and anaemia. *Trans R Soc Trop Med Hyg* 1967, 61:351-357.
2. Baily G: Other cestode infection: intestinal cestodes, cysticercosis, other larval cestode infections. In *Manson's Tropical Diseases*. Volume Chapter 85..21 edition. Edited by: Cook GC, Zumla AI. Philadelphia: Saunders/Elsevier; 2003:1593-1596.
3. Devi CS, Srinivasan S, Murmu UC, Barman P, Kanungo R: A rare case of diphyllbothriasis from Pondicherry, South India. *Indian J Med Microbiol* 2007, 25:152-154.
4. Pancharatnam S, Jacob E, Kang G: Human diphyllbothriasis: first report from India. *Trans R Soc Trop Med Hyg* 1998, 92:179-180.
5. Kumar CS, Anand Kumar H, Sunita V, Kapur I: Prevalence of anemia and worm infestation in school going girls at Gulbarga, Karnataka. *Indian Pediatr* 2003, 40:70-72.
6. Lee EB, Song JH, Park NS, Kang BK, Lee HS, Han YJ, Kim HJ, Shin EH,Chai JY: A case of Diphyllbothrium latum infection with a brief review of diphyllbothriasis in the Republic of Korea. *Korean J Parasitol* 2007, 45:219-223.