

Clostridium Non perfringens Species as an Etiological Agent in a Polymicrobial Abscess: A Case Report

Satyajeet K. Pawar^{1*}, M. V. Ghorpade², Vinayak Raje³

{¹ Asst. Prof., Dept. of Microbiology, ² Registrar, ³ Consultant Neurosurgeon} Krishna Institute of Medical Sciences University, Karad, Maharashtra. INDIA.

*Corresponding Address:

drskpawar@gmail.com

Case Report

Abstract: Abscess formation is common complication during wound healing. But association of abscess with anaerobes like *Clostridium non perfringens* species (spp.) in acute case is somewhat rare entity. We report a case of abscess formation with polymicrobial etiology in contused lacerated wound after road traffic accident. Out of the bacteria isolated from lesion, *Clostridium non perfringens* spp. was important as patient was on aerobic antibiotic therapy and recovery was prompt with addition of antibiotic against anaerobe in the treatment. One should not ignore presence of anaerobic bacteria like *Clostridium non perfringens* spp. in a polymicrobial abscess as in present case.

Key Words: polymicrobial abscess, *Clostridium non perfringens* species, wound healing.

Introduction

Wound healing is a complex process affected by many factors. ¹ Delayed wound healing many times results from progression of wound colonization to wound infection. This in turn is affected by wound size, host response, bacterial count, presence of different bacterial species and presence of foreign body in wound. ¹ The genus *Clostridium* is one of the major etiological agent in wound infection. ² It includes obligate anaerobic, endospore forming, gram positive bacilli. ² *Clostridium* spp. acts in synergy with other aerobic and anaerobic bacteria in wound infections. ³ Such polymicrobial infections are more destructive. ³ We report a case of delayed wound healing with polymicrobial abscess formation caused by *Clostridium non perfringens* spp. as one of the etiological agent.

Case report

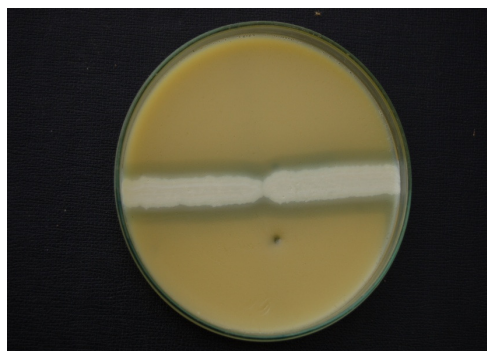
A 45 year old male came to Krishna Hospital and MRC, with complaint of swelling on left fronto parietal region on a previously sutured contused lacerated wound. Patient had a history of road traffic accident seven days before. In a tertiary care hospital, his wound was sutured and antibiotic Amoxycillin was given. Patient noticed swelling over the sutured wound, which was gradually increasing in size. Patient was afebrile. Patient was

nondiabetic and haematogram was normal. X-ray skull showed soft tissue swelling suggestive of draining subcutaneous abscess on left frontal regions measuring 47mm x 70mm x 8mm. After incision and drainage resuturing was done and pus sent for microbiological investigation. Gram stain showed besides, gram positive bacilli with central and subterminal spores, gram negative bacilli and pus cells. Aerobic culture showed growth of *Klebsiella* and *Citrobacter* spp. Anaerobic culture isolated *Clostridium* species. The organism was presumed to be *Clostridium non perfringens* as Nagler test was negative ^{4,5}. Antibiotic sensitivity testing was done for aerobic bacteria by Kirby-Bauer disc diffusion method. Both *Klebsiella* and *Citrobacter* spp. were sensitive to antibiotics like Ciprofloxacin, Cefoperazone, Amikacin, Piperacillin. Patient was put on antibiotic therapy against both aerobes and anaerobes, with which wound healing was prompt. The antibiotics used were Metronidazole, Amikacin and Piperacillin + Tazobactam combination.

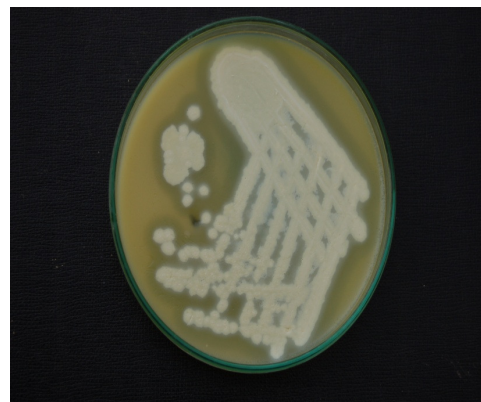Discussion

Even with good wound management, it is likely that it may get complicated ⁶. Factors affecting wound infection include inadequate vascular perfusion, inadequate nutrition, immune system disorder, chronic diseases like diabetes mellitus, malignancy, size of wound and presence of foreign body. ⁶ In present case, even after initial treatment of wound, swelling developed which may have been due to presence of foreign body as injury was due to traumatic accident. ⁷ Polymicrobial abscess in acute condition, as in present case within seven days is a rare condition as most polymicrobial infections occur in chronic condition ⁶. Most polymicrobial abscess due to trauma is combination of aerobic and anaerobic bacteria. ⁶ While aerobic organism isolated were *Klebsiella* and *Citrobacter* spp., anaerobic culture grew *Clostridium non perfringens* species. Species identification of *Clostridium* is usually limited to whether species is perfringens or non

perfringens especially in limited laboratory setup. Also increased cost and consumptions of time, limits use of identification in non perfringens species.⁸ There is always a very thin line of differentiation between colonization and infection of a wound.⁹ It is difficult to differentiate between pathogenic and nonpathogenic species in polymicrobial infected wound.¹⁰ Diagnosis of infection in polymicrobial wound should be based primarily on clinical signs.⁶ In the absence of clinical signs such as fever as in present case, greater emphasis has to be placed on microbiological result.⁶ In the present case *Clostridium non perfringens* species was one of the etiological agent of the abscess as direct smear showed presence of pus cells and gram positive spore bearing bacilli which outnumbered gram negative bacilli. This may be due to multiplication of anaerobic bacilli which is one of the indications of etiological agent.⁹ Most traumatic injuries are associated with polymicrobial etiology.⁶ *Clostridium non perfringens* species like *Clostridium bifermentans*¹¹, *Clostridium sporogens*⁸, *Clostridium glycolicum*², *Clostridium innocum*³, *Clostridium ramosum*³ and other species³ are associated with wound infection and pus formation. Further it is been proved that there is synergy of action among anaerobic bacteria including *Clostridium* spp. with aerobic bacteria.^{3,12} This synergy of action among *Clostridium* spp. and capsulated *Klebsiella* spp. as described by Brooks I.¹² may lead to delayed wound healing, as seen in present case. Early administration of appropriate antibiotics can prevent development of an abscess.¹³ Surgical drainage and combination of antimicrobial against aerobe and anaerobic organism will prevent further local spread if abscess develops as was in present case.¹³ What we feel is, in absence of all signs of infection, one should not overlook microbiological investigation especially in a polymicrobial disease condition.



Antitoxin Side Toxin Side
Nagler's Test : Negative
 There is no inhibition on antitoxin side.



Egg Yolk Agar Plate
 Lipase activity with pearl like reaction.

References

1. Edwards R., Harding K. G. Bacteria and wound healing, Current Opinion in Infectious Diseases, April 2004, Vol 17, 2 : 91- 96.
2. Jiang W, Abrar S., Romagnoli M, Carroll K C., Clostridium glycolicum Wound Infection: Case Reports and Review of the Literature. J Clin Microbiol: 2009 May, 47, 5: 1599-1601.
3. Brook I., Clostridial infection in children. J. Med Microbiol, 1995, 42, 78-82.
4. McClung L.S., Toabe R., The Egg Yolk Plate Reaction For The Presumptive Diagnosis of Clostridium Sporogens and Certain Species of the Gangrene And Botulinum Groups: J Bacteriol 1946, Vol 53, 139-147.
5. Willis A. T. Observations on the Nagler Reaction of some Clostridia, Nature, 1960 : 185, 943-944
6. Bowler P G, Duerden B I, Armstrong D G, Wound Microbiology and Associated Approaches to Wound Management. Clin Microbiol Rev. 2001 April 14(2) : 244-269
7. Connie M., Sarvis R N. Wound and Skin Care: Infected wounds Tipping the Balance with Stones. Nursing 2012, July 2007, 37: 7, 62.
8. Corbett C. E., Wall B. M., Cohen M., Case report : empyema with hydropneumothorax and bacteremia caused by Clostridium sporogens. Am J Med Sci. 1996 Nov; 312(5): 242-245
9. Patel S, Understanding Wound Infection And Colonisation, Wound Essentials, 2007 : 2 : 132 -142.
10. Hansis M. Pathophysiology of infection: a theoretical approach. Injury 1996; 27 Suppl 3: SC 5 –SC8.
11. Misra D P, Hurst D J. Necrotising pneumonia and empyema caused by Clostridium bifermentans. Thorax, 1980, 35, 310 -311.
12. Brook I. Abscesses. In: Brogden KA, Guthmiller JM, editors. Polymicrobial Diseases. Washington (DC) : ASM Press; 2002. Chapter 9. Available from: <http://www.ncbi.nlm.nih.gov/books/NBK2497>.
13. Brook I. Microbiology of Polymicrobial Abscess and implications for therapy. J. of Antimicrobial Chemotherapy. 2002, 50, 805-810.