

# Results of Defect Augmentation with Tricalcium Phosphate in Tibial Plateau Fractures

Supradeeptha C.<sup>1\*</sup>, Sudhir M. Shandilya<sup>2</sup>, Siva Reddy<sup>3</sup>, Vikram Kumar Kadium<sup>4</sup>

{<sup>1</sup>Assistant Professor, <sup>2</sup>Assistant Professor} Department of Orthopaedics, G. S. L. Medical Collge, Rajahmundry, Andhra Pradesh, INDIA

<sup>3</sup>Resident, B. I. R. R. D. Hospital, Tirupati, Andhra Pradesh, INDIA.

\*Corresponding Address:

[supradeep\\_challa@yahoo.co.in](mailto:supradeep_challa@yahoo.co.in)

## Research Article

**Abstract:** Reduction of the depressed joint surface in tibial plateau fractures leaves large cancellous bone defects. These metaphyseal defects are usually filled with autogenous bone grafts that cause significant donor site morbidity. The use of injectable tricalcium phosphate gives the opportunity to support the reduced joint surface without bone grafting. **Objective:** The aim of this study was to evaluate the functional and radiological outcomes of closed/open reduction and internal fixation, augmentation with injectable tricalcium phosphate in tibial plateau fractures. **Methods:** This prospective study includes 20 patients, with mean age of 44.4 years. According to the Schatzker's classification, there were 12 fractures of type II, one fracture of type III, five fractures of type V, and two of type VI. **Intervention:** All the patients underwent closed/ open reduction, osteosynthesis with screws or plate, and injection of tricalcium phosphate injection in the subchondral bone defect. The patients were reviewed at an average follow up of 15.35 months (range 6-28 months). Rasmussen's clinical and radiological score was used to assess the patients post-operatively and during follow-up period. **Results:** Union was achieved in all patients. Rasmussen's radiologic score was excellent in 2 patients (10%), good in 17 patients (85%), and fair in 1 patient (5%). Rasmussen's clinical score was excellent in 6 patients (30%), good in 13 patients (65%), and fair in 1 patient (5%). **Conclusion:** The results show that injectable tricalcium phosphate is a safe and useful alternative to bone grafting in tibial plateau fractures which have high compression strength and allows early partial and full weight bearing.

**Key words:** Tibial plateau fracture; Tricalcium phosphate; Schatzker's classification; Rasmussen's score.

## Introduction

Tibial plateau fractures comprise 1% of all lower extremity fractures affecting patients during the most productive years of their lives and can produce major disability<sup>1</sup>. Tibial plateau fractures occurs as a result of combination of vertical thrust and bending leading to varying degrees of articular surface depression and compression of underlying metaphyseal bone<sup>2</sup>. The main aim in the treatment of tibial plateau fractures is anatomic restoration of the articular surface and maintaining the reduction till fracture heals<sup>3</sup>. Restoration of the anatomy of the tibial plateau often leaves large cancellous bone defects. Usually the subchondral void is filled with autogenous iliac bone graft<sup>4,6</sup> which provides optimal

osteoconductive, osteoinductive, and osteogenic properties but associated with complications, ranging from temporary pain to chronic pain and numbness to long-term functional impairment, and wound complications are well documented<sup>7-15</sup>. Structural support is required to prevent collapse of the plateau when weight bearing is resumed, and an average of 60 grams of graft is required to fill the defect, once the plateau has been elevated back to its original position, as per Stephen W. Veitch<sup>16</sup>. Autologous cortical bone graft gives good structural support but poor bone graft interface. Furthermore, in certain large defects there is insufficient bone to fill the defect adequately especially in older patients. Furthermore, it may fail in clinical practice as most of the cellular (osteogenic) elements do not survive transplantation<sup>18</sup>. Autologous cancellous bone graft harvesting from iliac crest have a high morbidity (8.5-20%) such as postoperative pain, haematoma, delayed mobilization, deformed scar, and infection of the donor site<sup>17, 19</sup>. Acquired bowel herniation can occurs (this becomes a risk for larger donor sites (>4 cm). Satisfactory integration of the graft into the bone takes at about 6-12 months. During this period, collapse of the articular surface can theoretically happen, if full weight bearing was to be applied. Allografts hence were used to overcome these problems. The procedures of allograft carry drawbacks such as viral infection, immunogenicity, long term incorporation of graft to host bone, and limited immediate mechanical stability<sup>21-25</sup>. Fresh-frozen allografts are more osteoinductive and stronger than freeze-dried grafts. Further sterilisation of freeze-dried bone by ethylene oxide or gamma irradiation may also diminish osteoinductive properties. These materials are relatively brittle, difficult to apply to the irregularly formed defects. Rehydration of freeze-dried bone can result in longitudinal microscopic and macroscopic cracks, which may account for decreased graft strength of up to 50%. Cancellous allografts and hydroxyapatite allow full weight bearing only at a relatively late stage. Traditional polymethyl methacrylate cement may be well

molded into the metaphyseal defect and is appropriate for specific fracture problems but causes exothermic reaction and compromises local bone healing<sup>26, 27</sup>. Therefore, various biomaterials have been developed<sup>28, 29</sup>. Injectable tricalcium phosphate bone substitute<sup>30</sup> is one among them with high compressive strength and whose crystalline and chemical composition are similar to those of the mineral phase of human bone, accounting for its biocompatibility<sup>31</sup>. There is some experimental evidence concerning the effectiveness of tricalcium phosphate bone substitutes,<sup>32, 33</sup> but the published clinical data on humans has been limited. Study on cadavers, by Trenholm et al showed that, calcium phosphate cement was significantly ( $p < 0.0001$ ) stiffer than cancellous bone grafts and that defect displacement with loading was significantly ( $p < 0.0001$ ) less with calcium phosphate cement than with bone graft. Study on goats by Robert Welch et al<sup>32, 33</sup> showed that cancellous autograft did not maintain an anatomical reduction of the tibial plateau fractures. In contrast, augmentation with calcium phosphate cement prevented subsidence of the fracture fragment and maintained articular congruency as the fracture healed. In a multicenter, prospective, randomized study by Thomas A Russell, showed that calcium phosphate cement provide similar and possibly better mechanical support than autogenous iliac bone graft in treatment of unstable tibial plateau fractures<sup>34</sup>. Injectable calcium phosphate is a ceramic composite that combines “cement properties” with those of a void-filler<sup>34</sup>. As tricalcium phosphate, bone substitute is having similarity to the inorganic part of the bone tissue and its endurance (55 Mpa) to axial forces being higher than cancellous bone (2-20 Mpa) is a useful alternative to autologous bone graft<sup>35</sup>. During insertion, it occupies the whole volume of defect as it is in liquid form. As a result, when it sets, it offers better structural support to the fracture. Horstmann WG et al<sup>36</sup> reported the loss of reduction in one of 14 patients with tibial plateau fractures treated with calcium phosphate as

graft. Lobenhoffer et al<sup>37</sup> reported loss of reduction in two cases out of 26 cases. In Keating et al study there is loss in eight patients out of 44 patients. In Hatziantoniou et al<sup>38</sup> study loss is noted in two patients out of 20 cases. The aim of this study was to evaluate the incorporation of the injectable tricalcium phosphate graft and the ability of sustaining activity loads according to the clinical outcome. Ethical committee approval was taken. Informed consent was taken from all patients.

#### Patients and methods

20 patients with closed tibial plateau fractures [18 males and 2 females; mean age, 44.4 years (range 20-67 years)] were treated operatively using principles advocated by AO/AISF. All patients were studied prospectively. The right knee was involved in 8 patients and left knee in 12 patients. The modes of injury were road traffic accident (in 13 patients) or slip and fall (in 7 patients). Patients with multiple injuries, open fractures and with age below 18 years were excluded from the study. Pre-operative planning consists of antero-posterior and lateral view radiographs in all cases, and amount of displacement, articular depression/step-off, and angulation were recorded. Based on the radiograph, fractures were classified according to Schatzker's staging system<sup>3</sup>. According to the Schatzker's Classification, there were 12 fractures of type II, one fracture of type III, five fractures of type V, and two of type VI. Condylar depression/step-off (Fig: 1) was measured from a reference line level with the uninjured tibial plateau. Condylar widening (Fig: 2) was obtained by measuring total width of tibial plateau just below the joint line and measuring the width of femoral condyles just above the joint line. These two measurements are normally equal. Tibial plateau tilt (Fig: 3) was measured by angle drawn between line perpendicular to the long axis of the tibia and line along the depressed tibial plateau. Surgery performed as per the type of tibial plateau fracture.

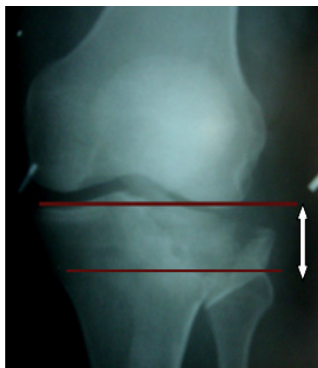

Figure 1: Measurement of Articular depression/step off

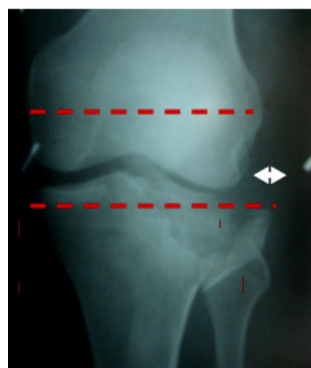

Figure 2: Measurement of condylar widening

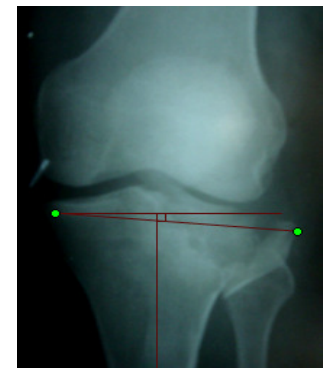
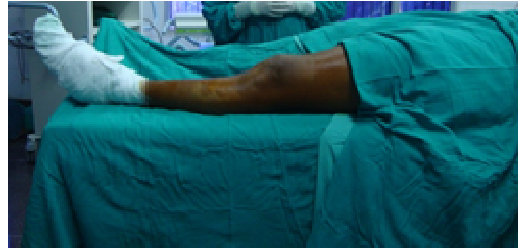
Figure 3: Measurement of tibial plateau tilt

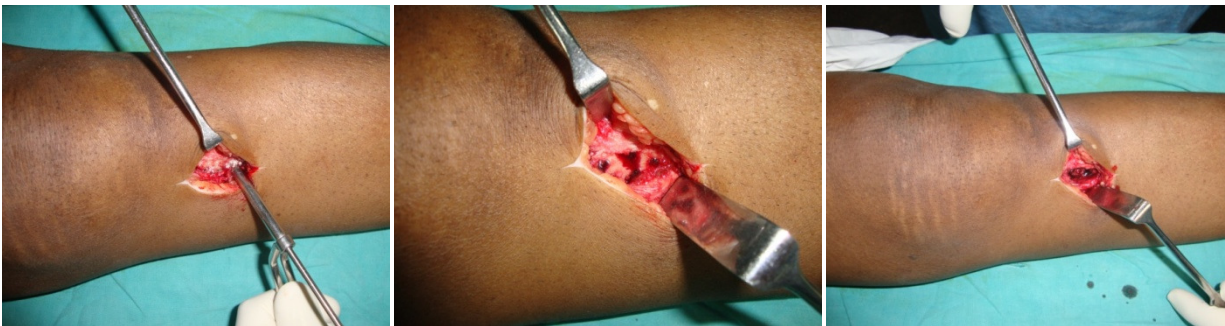Operative technique

The patients were operated under spinal anaesthesia AND SUPINE POSITION (Fig 3). The type of surgical procedure undertaken was determined in part by the condition of soft tissues and other factors that determine the ‘personality of the fracture’.

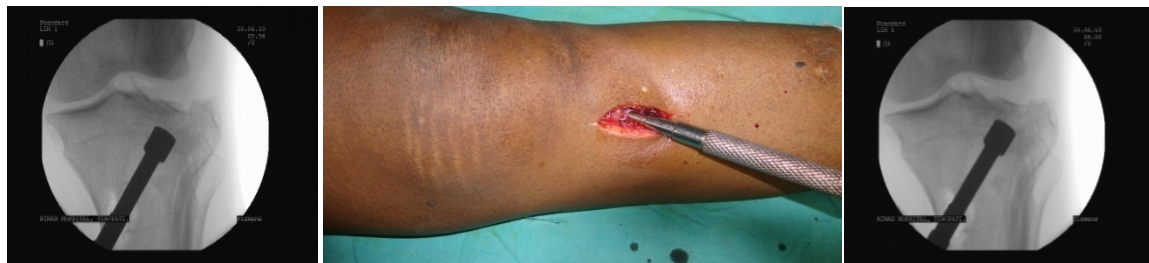

**Figure 4:** positioning of patient

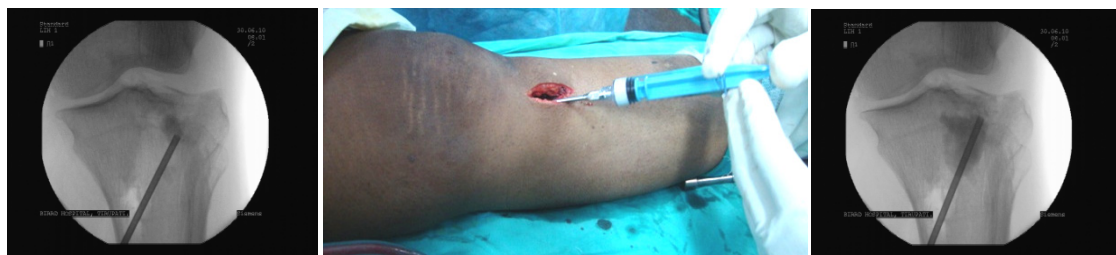All fractures were treated according to the principles advocated by AO/AISF. These principles include anatomic restoration of joint surface, rigid internal fixation to obtain a stable painless knee joint with normal range of motion controlled by well-functioning muscles. A trap door (Fig 4) of around 1×1 cm was created in the proximal tibial metaphysis using a small osteotome. A punch was inserted through the trap door (Fig 5), and the height of the tibial plateau is carefully restored. Depressed fragments were elevated to the anatomic joint line. The reduced fragments were maintained temporarily in anatomical position by K-wires.



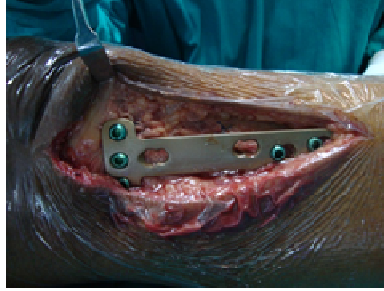
**Figure 5:** Creation of trap door



**Figure 6:** Elevation of the depression



**Figure 7:** cement inserton



**Figure 8:** internal fixation

6.5 mm lag screws were placed in the subchondral area to support the reduced joint fragments. If an additional split fracture was present, a precontoured buttress T-plate or a L-plate was placed on the lateral metaphysis and fixed in orderly fashion to avoid under tension in buttress plate (Fig 7). In bicondylar fractures, the fractured medial condyle was reduced percutaneously with the aid of reduction clamps under fluoroscopic control. Fixation of this fragment was achieved by lag screws from laterally or a small anti-glide plate, inserted under the antero-medial soft tissue coverage. When the osteosynthesis was completed, care was taken to remove all loose cancellous bone pieces and blood clots. The tricalcium phosphate bone substitute was injected (Fig 6) into the defect zone using fluoroscopy using syringe, the defect was filled completely with the cement under light pressure. The entire process of mixing and its application was completed within the five-minute working period of the cement. No manipulation was allowed for the next 10 minutes to allow the cement to harden. The C-arm was used to check the adequacy of reduction before closure. The tourniquet was then released. A tension free, layered closure was then performed under haemostasis control a sterile bulky dressing was applied.

#### Post-operative care

The knee was immobilized in 15° of flexion in a long knee brace and isometric quadriceps exercises and active ankle mobilization were started from the very next post-operative day. Ambulation with crutches and partial weight bearing mobilization was advised for first 6 weeks followed by full weight bearing over a further 6 weeks in either cast brace or crutches. All the patients were followed up at 6 weeks, 12 weeks, 6 months, 1 year and 2 years post surgically and radiographic evaluation was carried out at each time using clinical and radiological Rasmussen's score. Clinical healing was defined as an absence of pain at the fracture site with weight bearing and cantilevered stress. Radiographic healing was defined as a minimum of 3 bridging bone cortices across metaphyseal and diaphyseal components of the fracture site and lack of any evidence of failure at the articular surface. Evaluation of radiographs was done to know

radiological union of fracture, (disappearance of fracture lines) articular dehiscence, loss, or premature resorption of graft substitute, (presence of radiolucent zones) the amount of reduction of articular step. The postoperative radiographs were analyzed according to the Rasmussen's radiologic parameters of residual incongruity, condylar widening and tibial plateau tilt. Functional outcome was assessed by Rasmussen's parameters of pain, walking capacity, extensor lag, range of motion and stability.

#### **Results**

The average follow up was 15.35 months (range 6-28 months). Type II fracture was most common, occurring in twelve (60%) patients followed by type V fracture (5 patients), one (5%) patient had Type III and two (10%) patients had Type VI fracture.

#### Radiographic examination (Table 1):

Preoperative tibial plateau depression averaged 9.95 mm (range 4-25 mm). Immediate post-operative fracture depression averaged 2.25 mm (range 0-6 mm). Twelve patients had excellent reduction (2 mm or less), 7 patients had satisfactory (2-5 mm) reduction, and 1 patient had poor reduction (6 mm). At the final follow up, articular depression averaged 2.3 mm (range 0-8 mm). Eleven patients had excellent result and 8 patients had satisfactory result with other patient having poor result. One patient lost the initial post-operative reduction by more than 1 mm. Preoperative condylar widening was less than 5 mm in eleven (55%) patients, 5-10 mm in eight (40%) patients and more than 10 mm in one (10%) patient. At the final follow-up, no widening was noticed in six (30%) patients, thirteen (65%) patients had less than 5 mm widening and one (5%) patient had 6 mm widening. In our study the mean preoperative condylar widening was 5.4 mm (range 2-14 mm) and mean postoperative condylar widening at the final follow-up was 1.4 mm (range 0-6 mm). There were no non-unions or malunions in the study group. The mean Rasmussen's radiological score at final follow up was 12.9 (range 10-18). Two (10%) patients had excellent result, seventeen (85%) patients had good and one (5%) patient had fair result.

**Table 1:** Fracture depression, displacement, tibial plateau tilt values(preoperative and postoperative)

<b>Fracture depression (score)</b>	<b>Preoperative Number of patients (percent)</b>	<b>Immediate post-operative Number of patients (percent)</b>	<b>Final follow-up Number of patients (percent)</b>
None (6)	0	12(60%)	11(55%)
<5 mm(4)	5(25%)	7(35%)	8(40%)
6-10 mm(2)	10(50%)	1(5%)	1(5%)
>10 mm(0)	5(25%)	0	0
<b>Condylar widening (score)</b>	<b>Preoperative Number of patients (percent)</b>	<b>Postoperative Number of patients (percent)</b>	
None (6)	0	6(30%)	
<5 mm(4)	11(55%)	13(65%)	
6-10 mm(2)	8(40%)	1(5%)	
>10 mm(0)	1(5%)	0	
<b>Tibial plateau tilt (score)</b>	<b>Preoperative Number of patients (percent)</b>	<b>Postoperative Number of patients (percent)</b>	
None(6)	0	2(10%)	
<10 degrees	13(65%)	17(85%)	
10-20 degrees	7(35%)	1(5%)	
>20 degrees	0	0	

**Clinical evaluation**

Six (30%) patients had excellent result, thirteen (65%) patients had good result, and one (5%) patient had fair result. The mean functional score at final follow up is 24.5 (range 13-30). Only one patient developed infection which resolved within 3 weeks after usage of antibiotics (Table 2).

**Table 2:** Rasmussen’s score functional and radiological assessment

<b>Result</b>	<b>Functional assessment</b>		<b>Radiologic assessment</b>	
	<b>Rasmussen’s Score</b>	<b>No. of Patients(%)</b>	<b>Rasmussen’s Score</b>	<b>No. of Patients(%)</b>
Excellent	27-30	6(30%)	18	2(10%)
Good	20-26	13(65%)	12-17	17(85%)
Fair	10-19	1(5%)	6-11	1(5%)
Poor	<10	0	<6	0

**Discussion**

In our study, type II tibial plateau fracture is most common type. In a series by Stokel and Sadasivan<sup>40,41</sup>, the most common fracture types to be type II and type VI. Touliatos et al<sup>42</sup> reported 12 type II fractures, which was second only to type VI fractures. However, comparing results across studies is difficult. In our study, immediate post-operative mean depression was 2.25 mm and at final follow up the mean depression was 2.3 mm at average follow up of 15 months. In our study, the reduction achieved at the index operation was altered in four patients. Loss of 3 mm reduction is seen in one patient and 1 mm reduction in 3 patients (i.e., from 2mm to 3mm) at their final follow up. A further 3 mm subsidence of articular depression was noted in one patient who had infection. The loss of reduction was expected since tricalcium phosphate loses its endurance in pH changes. Another 3 patients (1 mm articular subsidence) whose age is more than 55 years with bicondylar tibial plateau fracture the osteoporotic quality of bone and cyclic loading on bicondylar fracture has probably played a role in the loss of reduction. The initiation of full weight bearing should therefore be more conservative in patients with poor quality of underlying bone. Richard L. Uhl et al<sup>39</sup> suggested that cyclic loading of bicondylar tibial

plateau fractures, shows that neither lateral locking alone nor dual-plate treatment facilitated early return to weight bearing so he suggested that prolonged non-weight bearing in the postoperative period may help prevent the subsidence. Biomechanical studies have shown that tricalcium phosphate provides more support of the articular surface than does cancellous bone graft. Landry et al.<sup>43</sup> and Trenholm et al.<sup>44</sup> found that, at a load of 1000 N applied to the plateaus of cadaveric tibiae with Schatzker type-II fractures, the rate of displacement was 68% lower for subchondral defects filled with tricalcium phosphate than for those filled with cancellous bone graft. Welch et al. found similar results of higher retention of the subarticular support with alpha-BSM compared with autogenous graft in fractures of the tibial plateau in a goat model. In our study, using Rasmussen’s radiological score,<sup>45</sup> two patients had excellent results, seventeen patients had good results, and one patient had fair result. The mean radiological score was 12.9 (range 10-18). In our study, six patients reported excellent, thirteen reported good and only one reported fair outcome with no poor results. The mean Rasmussen’s functional score at final follow up is 24.5 (range 13-30). In a meta-analysis study by Bajammal et al, the patients had less pain at the fracture site in comparison with controls managed with

no graft<sup>46</sup>. Most of the patients in our study were pain free and had normal walking capacity. Good range of knee joint movement can be attributed to early knee mobilization. Only one patient had less than 60° of knee movement, was attributed to delayed knee mobilization in this patient because of associated acetabular fracture. Only one patient had constant knee pain after activity in whom x-ray showing condylar step-off of 9 mm and the increase in articular step-off is probably due to associated infection. We had only one case of infection post-operatively which was treated with antibiotics. No case of deep vein thrombosis was observed as the patients were mobilized early. No case of mal-union and non-union was observed even after allowing early full weight bearing, probably due to high endurance of tricalcium phosphate to compressive forces.

### Conclusion

In our opinion, the injectable calcium phosphate cement used here is a promising alternative for filling metaphyseal defects in the treatment of displaced tibial plateau fractures. Although this study shows the feasibility of this material for these intra-articular fractures, the main weakness is the lack of a control group. A randomized study is now required to validate these promising results.

### References

1. Su EP, Westrich GH, Rana AJ, Kapoor K, Helfet DL. Operative treatment of tibial plateau fractures in patients older than 55 years. *Clin Orthop Relat Res.* 2004; 421: 240–248.
2. Kennedy JC, Bailey WH. Experimental tibial plateau fractures. *JBJS.* 1968; 50A: 1522-34.
3. Schatzker J. The rationale of Operative fracture care. 3<sup>rd</sup>.ed.Springer. 2005; 19.1: 447.
4. Koval KJ, Helfet DL. Tibial plateau fractures: evaluation and treatment. *J Am Acad Orthop Surg.* 1995; 3: 86-94.
5. Lachiewicz PF, Funcik T. Factors influencing the results of open reduction and internal fixation of tibial plateau fractures. *Clin Orthop Relat Res.* 1990; 259: 210-5.
6. Segal D, Franchi AV, Campanile J. Iliac autograft for reconstruction of severely depressed fracture of a lateral tibial plateau. Brief note. *JBJS Am.* 1985; 67: 1270-2.
7. Silber JS, Anderson DG, Daffner SD, Brislin BT, Leland JM, Hilibrand AS, Vaccaro AR, Albert TJ. Donor site morbidity after anterior iliac crest bone harvest for single-level anterior cervical discectomy and fusion. *Spine.* 2003; 28: 134-9.
8. Auleda J, Bianchi A, Tibau R, Rodriguez-Cano O. Hernia through iliac crest defects. A report of four cases. *Int Orthop.* 1995; 19: 367-9.
9. Goulet JA, Senunas LE, DeSilva GL, Greenfield ML. Autogenous iliac crest bone graft. Complications and functional assessment. *Clin Orthop Relat Res.* 1997; 339: 76-81.
10. Kurz LT, Garfin SR, Booth RE Jr. Harvesting autogenous iliac bone grafts. A review of complications and techniques. *Spine.* 1989; 14: 1324-31.
11. Arrington ED, Smith WJ, Chambers HG, Bucknell AL, Davino NA. Complications of iliac crest bone graft harvesting. *Clin Orthop Relat Res.* 1996; 329: 300-9.
12. Summers BN, Eisenstein SM. Donor site pain from the ilium. A complication of lumbar spine fusion. *J Bone Joint Surg Br.* 1989; 71: 677-80.
13. Younger EM, Chapman MW. Morbidity at bone graft donor sites. *J Orthop Trauma.* 1989; 3: 192-195.
14. B.N. Summers, S.M. Eisenstein. Donor site pain from the ilium: a complication of lumbar spine fusion. *JBJS Br.* 1989; 71-B: 677–680.
15. H.S. Sandhu, H.S. Grewal, H. Parvataneni. Bone grafting for spinal fusion. *Orthop Clin North Am.* 1999; 30: 685–698.
16. Stephen W. Veitch, Rowenna M. Stroud, Andrew D. Toms. Compaction bone grafting in Tibial Plateau Fracture Fixation. *The Journal of Trauma, Injury, Infection and critical care.* 2010; 68(4): 980-983.
17. C.A.F. Dodd, C.M. Fergusson, L. Freedman et al. Allograft versus autograft bone in scoliosis surgery. *JBJS Br.* 1988; 70: 431–434.
18. W.W. Tomford. Transmission of disease through transplantation of musculo-skeletal allografts. *JBJS Am.* 1995; 77: 1742–54.
19. John Gray Seiler III, MD, Joseph Johnson, MD. Georgia Hand and Microsurgery Clinic, Atlanta, Ga. "Iliac Crest Autogenous Bone Grafting: Donor Site Complications". *J South Orthop Assoc.* 2000; 9 (2): 91–97.
20. Abidi NA, Dhawan S, Gruen GS, Vogt MT, Conti SF. Wound-healing risk factors after open reduction and internal fixation of calcaneal fractures. *Foot Ankle Int.* 1998; 19: 856-61.
21. Stevenson S. Biology of bone grafts. *Orthop Clin North Am.* 1999; 30: 543-52.
22. E.U. Conrad, D.R. Gretch, K.R. Obermeyer et al. Transmission of the hepatitis-C virus by tissue transplantation. *JBJS Am.* 1995; 77-A: 214–224.
23. Boyce T, Edwards J, Scarborough N. Allograft bone. The influence of processing on safety and performance. *Orthop Clin North Am.* 1999; 30: 571-81.
24. Ladd AL, Pliam NB. Use of bone-graft substitutes in distal radius fractures. *J Am Acad Orthop Surg.* 1999; 7: 279-90.
25. Moore WR, Graves SE, Bain GI. Synthetic bone graft substitutes. *ANZ J Surg.* 2001; 71: 354-61.
26. Kemal Serbetc, Feza Korkusuz, Nesrin Hasirci. Mechanical and Thermal Properties of Hydroxyapatite-Impregnated Bone Cement. *Turk J Med Sci;* 2000 (30): 543-549.
27. Peter V Giannoudis, Haralambos Dinopoulos, Eleftherios Tsiridis. Bone substitutes: An update. *Injury;* 2005 (36-3): S20–S27.
28. Larsson S, Bauer TW. Use of injectable calcium phosphate cement for fracture fixation: a review. *Clin Orthop Relat Res.* 2002; 395: 23-32.
29. Nandi S.K, Roy S, Mukherjee P. Orthopaedic applications of bone graft and graft substitutes: a review. *Indian J Med Res.* 2010; 132: 15-30.
30. Robert D. Welch, DVM, PhD; Hong Zhang, MD; Dwight G. Bronson, MS. Experimental Tibial plateau fractures augmented with calcium phosphate cement or autologous bone graft. *JBJS Am* 2003; 85(2): 222-231.

31. Welch RD, Zhang H, Bronson DG. Experimental tibial plateau fractures augmented with calcium phosphate cement or autologous bone graft. JBJS. 2003; 85: 222-31.
32. Thomas A. Russell, Ross K. Leighton. Comparison of autogenous bone graft and endothermic calcium phosphate cement for defect augmentation in Tibial plateau fractures. JBJS 2008; 90: 2057-61.
33. Ahmad M. Ali, M. El- Shafie, K.M. Willett. Failure of fixation of tibial plateau fractures. J of Orthopaedic Trauma 2002; 16(5):323-329.
34. Hitin Mathur, Shankar Acharya, VK Nijhawan, SP Mandal. Operative results of closed tibial plateau fractures. Indian journal of Orthopaedics. 2005; 39(2): 108-112.
35. B Grimm, A W Miles. Optimizing a hydroxyapatite/tricalcium phosphate ceramic as a bone graft extender for impaction grafting. J Material Science. 2001; 12: 929-34.
36. W.G. Hortsmann, C.C.P.M.Verheyen, R.Leemans. An injectable calcium phosphate cement as a bone-graft substitute in the treatment of displaced lateral tibial plateau fractures. Injury, Int.J.Care Injured 2003; 34:141-144.
37. Lobenhoffer P, Gerich T, Witte F, Tscherne H. Use of injectable calcium phosphate bone cement in the treatment of tibial plateau fracture: a prospective study of twenty-six cases with twenty- month follow-up. J Orthop Trauma 2002; 16:143-149.
38. Hatziantoniou J, Diakos G, Kyriakidis M. The use of injectable calcium phosphate bone cement in tibial plateau fractures for structural support. Journal of Hellenic Association of orthopaedic and traumatology 2004; 55(3):433-438.
39. Richard L. Uhl, MD; Jonathon Gainor, MD; Joel Horning, MD. Treatment of bicondylar tibial plateau fractures with lateral locking plates. Orthopaedics. 2008; 31(5).
40. Stokel EA. Tibial plateau fractures-standardized evaluation of operative results. Orthopaedics. 1991; 14(3): 263-70.
41. Stokel EA, Sadasivan KK. Tibial plateau fractures: standardized evaluation of operative results. Orthopaedics. 1991; 14: 263-270.
42. Touliatos AS, Xenakis T, Soucacos PH, Soucacos PN. Surgical management of tibial plateau fractures. Acta Orthop Scand Suppl. 1997; 275: 92-96.
43. Landry S, Trenholm A, Deluzio K, McLaughlin K, Leighton R. A cadaver model of a tibial plateau fracture reveals increased compressive strength of bone substituting material over autograft. Trans Orthop Res Soc. 2001; 26: Poster no. 983.
44. Trenholm A, Landry S, McLaughlin K, Deluzio KJ, Leighton J, Trask K, Leighton RK. Comparative fixation of tibial plateau fractures using alpha-BSM, a calcium phosphate cement, versus cancellous bone graft. J Orthop Trauma. 2005; 19: 698-702.
45. Poul S. Rasmussen, Gothenburg. Tibial condylar fractures: Impairment of the knee stability and indication for surgical management .J Bone and Joint Surgery 1973; 55A:1331-1350.
46. Bajammal SS, Zlowodzki M, Leiwica A, Tornetta P 3rd, Einhorn TA, Buckley R, Leighton R, Russell TA, Larsson S, Bhandari M. The use of calcium phosphate bone cement in fracture treatment. A meta-analysis of randomized trials. J Bone Joint Surg Am. 2008; 90(6): 1186-96.

*Correspondence Address:*

**Dr. C. Supradeeptha**

S/o C. Janakirama naidu

Assistant Professor, Department of Orthopaedics

G.S.L. Medical Collge, Rajahmundry,

Andhra Pradesh, INDIA, PIN-533296

**Email:** [supradeep\\_challa@yahoo.co.in](mailto:supradeep_challa@yahoo.co.in)