Kikuchi's Fujimoto Disease

Vidya Fadnis

Department of Pediatrics, Yashvantrao Chavan Memorial Hospital, Pimpri, Pune, Maharashtra, INDIA.

Corresponding Address:

vidyapf@gmail.com

Case Report

Abstract: Children presenting with cervical lymphadenopathy is common clinical problem.When persistent cervical lymphadenopathy is present then diagnosis of tuberculosis, lymphoma, HIV infection, autoimmune disease is suspected. There is one clinical condition called as Kikuchi's disease where tender cervical lymphadenopathy is present. This is rare benign condition where treatment is symptomatic. Here two patients have been presented, 9 and 12 years old boys, with enlarged tender cervical lymphadenopathy. One of the patients received CAT1 treatment for? Tubercular cervical lymphadenopathy for 6 months and since lymphnodes were still enlarged CAT2 treatment was started. In other patient mother was worried about intermittently enlarged cervical lymphnodes associated with fever. After lymphnode biopsy both the patients turned out to be suffering from Kikuchi's disease. Purpose of presentation of these rare cases is one should be aware of this clinical condition so that unnecessary administration of antituberculous drugs and parental anxiety is avoided. Diagnosis is done by lymph node biopsy. Kikuchi-Fujimoto disease is extremely rare in children.

***Keywords*:** Kikuchi's, tender, lymphadenopathy, CAT1, biopsy.

Introduction

Kikuchi's-Fujimoto disease (KFD) also called as histiocytic necrotising lymphadenitis is uncommon, idiopathic, generally self limited cause of lymphadenitis.[1] It was originally described in young women & is rare benign condition of unknown cause characterised by cervical lymphadenopathy and fever.[2] Kikuchi first described the disease in 1972 in Japan. Fujimoto &Colleagues independently described Kikuchi disease in the same year.[3] The cause of Kikuchi-Fujimoto disease is unknown. Some kind of viral or post viral etiology has been proposed. It is reported worldwide with higher prevalence in Japanese or Asiatic individuals. People under 30 yrs of age are more affected by this disease than any other age group.[4] Lymphadenopathy resolves over several weeks to six months. Here I present two pts of 9yrs&12yrs old boys with Kikuchi-Fujimoto disease. Two patients' 9 years old boy in the month of March2013 &12 years old boy in the month of June 2013 admitted in the pediatric ward with the complaints of 1.Swellings in the neck increasing in size associated with fever and pain for 2 weeks In both the patients swellings were persistent for last 18moths which used to increase in size intermittently associated with fever & pain. Both the patients were investigated outside prior to admission in our hospital including lymph node biopsy. Lymph node biopsy was labelled as reactive lymphadenitis in 12 years old boy &in 9 years old boy lymph node biopsy report was not available but that child received ATT CAT 1 for 6months followed by CAT2 as lymphadenopathy was persistent. On examination in 9 years old boy-bilateral cervical lymphadenopathy +. Rt upper cervicallymph node-circular 1.5cm*1.5cms, tender, discrete, firm, not attached to underlying structures, Rt lower cervical lymph node 1cm*1cm,mobile firm, tender. Rt submandibular 1cm*1cm.Multiple small discrete lymphadenopathy < .5cms in size in Lt upper and Lt lower cervical region. In other 12 yrs old boy cervical lymphadenopathy two on the Rt upper cervical region 2cms*2cms firm tender, mobile, nonmatted, one on lt upper cervical 1.5cm*1.5cmfirm,tender,mobile &multiple small discrete cervical lymphadenopathy present in upper & lower cervical region. In both the patients no significant inguinal, axillary, or epitrochlear lymphadenopathy. Both the patients were averagely built & averagely nourished with no history of chronic cough, hemoptysis, breathlessness, anorexia, or wt loss. Systemic exam did not show any abnormality. All investigations were negative including T.T, sputam for AFB, X-ray chest, USG Abdomen & HIV. ESR in both the pts were 21 & 30 respectively. Lymph node biopsy was done & it showed necrotizing lymphadenitis with absence of granuloma or caseation. ZN staining did not reveal AFB. -VE for kochs, fungi, or malignancy. Diagnosis was Kikuchi-Fujimoto disease (slides 1, 2). Both the patients & their relatives were reassured and symptomatic treatment was given.

Discussion

Kikuchi Fujimoto disease presents with tender cervical lymphadenopathy & usually accompanied with fever. KFD(Kikuchi Fujimoto Disease)is more common in females compared to males with male to female ratio1:46.In our pts both the pts were males..Affected patient are most often young adults under30yrs of age.The disease is seldom reported in children7Our pts were 9&12yrs old children.

Less common symptoms in KFD include wt loss, diarrhea, anorexia, nausea, vomiting Some pts may have hepatosplenomegaly. The exact etiology of Kikuchi disease is not known. Viral or autoimmune cause has been suggested. Various viruses are supposed to be responsible for triggering characteristic hyperimmune reaction leading to Kikuchi disease3 but none have been confirmed uptil now. Association of SLE &KIKUCHI disease has been suggested but no convincing evidence to prove the association. Exact pathogenesis of cell necrosis in Kikuchi disease is not known but primary event may be activation of T lymphocytes & histiocytes. Proliferating Tcells enter the cycle of apoptosis which form necrosis in the lymphnodes and then cellular debris of necrosed cells are removed by histiocytes. In patients with Kikuchi disease laboratory studies are nonspecific. In our pts ESR was raised.(21,30respectively) .CXR was normal.& USG Abdomen did not show any abnormality. FNAC was inconclusive in both the patients showing reactive lymphadenitis. Diagnosis is confirmed only by excisional lymph node biopsy. 3In our pts histological findings are consistent with necrotising lymphadenitis with histiocytic proliferation. One lymphnode bit shows area of necrosis with karryorhectic debri, polys not seen. In pediatric age group Kikuchi disease is rarely suspected if cervical lymphadenopathy is present. Mostly conditions like TB, reactive lymphadenopathy, lymphoma are suspected. In our pts one pt received antikochs before diagnosis of Kikuchi was made. Even FNAC lymphnode was inconclusive &one needs to do lymphnode biopsy and good histopathologist to diagnose Kikuchi disease so that we can avoid unnecessary antikochs treatment & relieve parental anxiety. Treatment of Kikuchi disease is symptomatic. NSAIDS are given for pain &fever. In severe form of disease corticosteroids, I.V immunoglobulins have been tried with some success. Usually it is benign self limiting condition which resolves in few wks to months. The disease has recurrence rate of 3to4%.

Conclusion

Kikuchi Fujimoto disease is rare disease. Clinically it may mimic TB, lymphoma, collagen vascular disease. It is important to be aware of this condition & diagnosis should be done by histopathological exam of lymphnode so that unnecessary use of antikochs or other agents are avoided. In Kikuchi-Fujimoto disease treatment is symptomatic &reassurance of parents is most important.

References

1. Kikuchi M: Lymphadenitis showing focal reticulum cell hyperplasia with nuclear debris and phagocytes-a clinicopathological study. Acta Hematol Jpn1972;35:379-380.
2. UpToDate Kikuchis disease-Michael J Richards, MD, (FRACP)
3. Mediscape-kikuchi DiseasE--Author-John Boone, MD, Chief editor Emmanuel C MD
4. Ku OT. Kikuchis disease(hystiocytic necrotising lymphadenitis)a clinicopathologic study of 79 cases with analysis of histologic, Subtypes ,immunohistology and DNAploidy :-Am. J. Sug Pathol1995(19:798to809Pub Med)
5. Kikuchi Disease-Author John Boone, MD Chief editor. Emmanuel C Besa, MD
6. Kikuchi-Fujimoto disease-Xavier Bosch, and Antonia Guilabert-Orphanet Journal of Rare Diseases 2006,1:18.

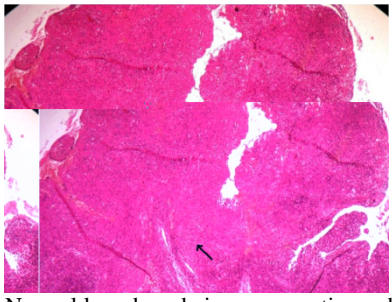

Figure 1: Normal lymph node in upper portion, while lower portion is showing effected architecture and large geographic area of geographical necrosis (Arrow), A-(HPE; 4x) B-(HPE; 10x)

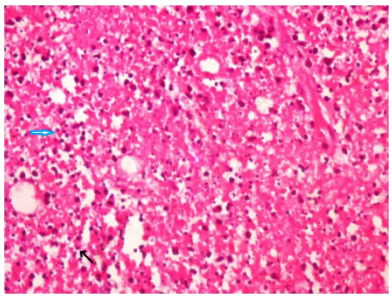

Figure 2: Typical picture of karyorrhexis/pykosis (Black arrow) of nucleus with absence of neutrophilic reaction with presence of large areas of karyolysis (Blue arrow) (HPE; 40x)