

Primary Multicentric Hepatocellular Carcinoma An Incidental Finding at Autopsy

Arun M.^{1*}, Reddy A.², Kagne R. N.³, Sowmya S.⁴, Balaraman R.⁵

{¹Post Graduate, ²Assistant professor, ³Professor and Head}

Department of Forensic Medicine, Sri Manakula Vinayagar Medical College and Hospital, Puducherry, INDIA,

⁴Professor and Head, Department of Pathology, Sri Manakula Vinayagar Medical College and Hospital, Puducherry, INDIA.

⁵Head of the Department, Department of Forensic Medicine, Indira Gandhi Government General Hospital and Post Graduate Institute, Puducherry, INDIA.

Corresponding Address:

doctorarun@live.com

Case Report

Abstract: Multicentric hepatocellular carcinoma is relatively a rare malignant condition usually presenting without symptoms. It is commonly seen in hepatic or cirrhotic liver as an incidental finding at autopsy. In non hepatic liver multicentricity is associated with secondary metastasis rather than primary hepatocellular carcinoma. Medicolegal autopsy was conducted on a 56 year old male who died due to septicemic complications of burns. On gross examination of the liver secondary metastasis was suspected because of the presence of multiple nodules seen on the surface of both the lobes. After histopathological examination of the lesion the diagnosis of primary multicentric hepatocellular carcinoma was established. Thus a case of multicentric hepatocellular carcinoma was detected as an incidental finding on medicolegal autopsy.

Key words: Medicolegal Autopsy, Incidental finding, Multicentric hepatocellular carcinoma.

Introduction

Hepatocellular carcinoma (HCC) is a global health problem representing the third leading cause of cancer related death worldwide [1]. The incidence rate of hepatocellular carcinoma in India for men ranges from 0.7 to 7.5 and for women 0.2 to 2.2 per 1, 00,000 populations per year. There is a male preponderance with a male: female ratio of 4:1 and the median age ranges between 40 and 70 years [2]. Hepatitis B virus (HBV), Hepatitis C virus (HCV) infections and intake of alcohol are widely recognized as the major etiological factors of HCC [3]. Multicentric liver cell carcinoma is associated with cirrhosis which have greater tendency of widespread hepatic involvement rather than those arising from previously normal liver [4]. Macroscopically, hepatocellular carcinoma appears as a nodular or infiltrative tumor. The nodular type may be solitary mass or it can also be multinodular, mimicking metastasis. The prevalence of hepatocellular carcinoma is less than 1% of all autopsies in USA and Europe. The incidence in Africa and South East Asia is 2 to 8% [5].

Case Report

A 56 year old male patient was admitted with history of accidental burns (25-30%). Clinically he was evaluated and managed for burns under the cover of antibiotics and supportive treatment including fluids and electrolytes. His renal parameters and liver functions were within the normal range for the first three days of admission. Skin grafting was planned after two weeks for which serological tests were advised. Serological tests for Hepatitis B and HIV were negative. The patient was non-alcoholic and non-smoker. There was no history of abdominal discomfort in the recent past. In the later stage the patient's general condition and the biochemical parameters especially the renal functions gradually deteriorated during his hospital stay. The patient died on the 40th day due to septicemic complications of burns. Medicolegal autopsy was conducted on the next day.

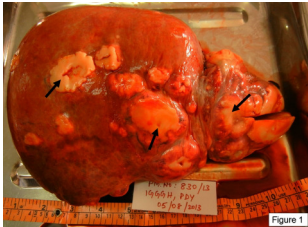Autopsy Findings

On external examination partially healed dermo-epidermal burns (25-30%) were present over the right side of the body involving the thorax, abdomen, pelvis, upper and lower limbs. Burnt areas showed pockets of pus and granulation tissue formation. Infected bed sores were present over the sacral and shoulder blade areas. On opening the thoraco abdominal cavities we noticed enlarged liver with abnormal multiple nodular structures over the entire organ which lead to the suspicion of secondaries. Hence searched for primary lesions meticulously, especially in the lungs and colon but no lesions were noticed.

On gross examination

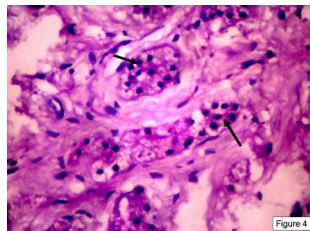
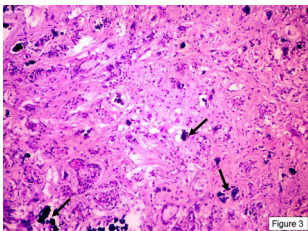
Liver was large weighing 1900gms measuring 20 × 10 × 8cms. The external surface of the liver had multiple nodularity with bosselated appearance (Figure 1). On cut section liver showed multiple well circumscribed nodules

both in the sub capsular and the parenchyma of both the lobes (Figure 2). They appeared solid and fleshy with many foci of calcification. Few nodules showed central induration and necrosis. The largest nodule was 4 cms in diameter and the smallest was 1cm diameter. These nodules were surrounded by adjacent normal liver parenchyma. Gallbladder and bile ducts were apparently normal.



Microscopic examination

Multiple sections of the nodules and the adjacent liver parenchyma revealed tumor nests composed of polygonal cells with abundant granular cytoplasm. The nuclei of these cells showed marked pleomorphism and hyperchromatism. These tumor cells resembled the parent tissue suggesting that the lesion was primary multicentric hepatocellular carcinoma. Some of the nodules showed tumor nests surrounded by dense desmoplasia with multiple areas of dystrophic calcification, H& E 20x (Figure 3). The tumor consists of nests of granular cells surrounded by fibrosis, H&E 40x (Figure 4). The adjacent hepatic parenchymal tissues were within normal limits.



Hence, in the present case medicolegal autopsy findings in combination with gross and histopathological examination findings facilitated the accurate diagnosis of multicentric hepatocellular carcinoma.

Discussion

HCC is highly malignant and prone to multicentric occurrence [6]. Incidence rate of HCC in India for men ranges from 0.7 to 7.5 and for women 0.2 to 2.2 per 1, 00,000 populations per year. There is a male preponderance and the median age ranges between 40 and 70 years [2]. Multicentric hepatocellular carcinoma is less often seen and is usually asymptomatic until later stages [5]. HCC is unusual among human cancers in that pathophysiology is complex, multifactorial and ever expanding. HCV, HBV infections and chronic alcoholism are the major risk factors recognized for HCC,

responsible for approximately 80% of new cases. No definitive cause is found in 10- 30% of HCC patients. Therefore, it is conceivable that risk factors other than viral infection or alcohol drinking exist for HCC, but the evidence is still unclear [7]. HCC is usually asymptomatic until later stages. In the present case the patient was a 56 year old male and he was a non- alcoholic, non-smoker and the serological tests for HBV and HIV were negative. He remained asymptomatic throughout his life for hepatocellular carcinoma. Recent studies in molecular biology have shown that some HCCs are multicentric in origin [8]. Exact genetic occurrence of multicentric hepatocellular carcinoma is unknown. The multicentric occurrence of HCC is new and different from the primary lesion, but for intrahepatic metastasis, the recurrence is derived from the primary tumor. Patients with multicentric occurrence have better outcomes than those with intrahepatic metastasis [1]. Death is often due to liver failure associated with cirrhosis and/or rapid outgrowth of multilobular HCC [9]. In situations where autopsy findings indicate that there is a combination of injury and disease, the autopsy surgeon should analyse the data carefully and opine on the relative role of trauma and disease to death. In accepting trauma as a cause of cancer and death, the Ewing's postulates should be satisfied [10]. None of the criteria can be proved with this tumor. In the present case the cause of death is due to septicemic complications of burns but not related to hepatocellular carcinoma.

Conclusion

In the recent past clinicopathological autopsies were important in detecting types of cancer, causative agents, patterns of incidence and behavior in types of cancer. Nowadays clinicopathological autopsies have become a rare entity, so medicolegal autopsies can explore these areas for the benefit of human beings. Thus this case highlights the importance of medicolegal autopsy in combination with histopathology. Recent diagnostic advances have done little to change the incidence of unexpected deaths; medicolegal autopsy plays a vital role in depicting the exact causes of death which will be helpful in improving various research and health care priorities. Even though medicolegal autopsy does not offer direct benefits to the dead, it is indispensable for supporting or contradicting clinical impressions, defining the level of residual disease and the adequacy of therapy and revealing unexpected findings that affected patient care.

References

1. Li S-L, Su M, Peng T, Xiao K-Y, Shang L-M, Xu B-H, et al. Clinicopathologic characteristics and prognoses for multicentric occurrence and intrahepatic metastasis in synchronous multinodular hepatocellular carcinoma

- patients. *Asian Pac J Cancer Prev APJCP*. 2013;14(1):217–23.
- World digestive health day- Special 2013 WDHD publication. [Internet]. World Gastroenterology Organisation; 2013. Available from: <http://www.wgofoundation.org/assets/export/userfiles/wdhd13-supplement-FINAL.pdf>
 - Farazi PA, DePinho RA. Hepatocellular carcinoma pathogenesis from genes to environment. *Nat Rev Cancer* 2006;6:674–87.
 - Rosai J, Ackerman. *Surgical Pathology*. 10th ed. Newyork: Elsevier Inc; 2012. 946.
 - Mohan H. *Textbook of pathology*. 6th ed. New Delhi: Jaypee brothers medical publications (p) Ltd; 2010. 633-4.
 - Nomoto S, Kinoshita T, Kato K, Otani S, Kasuya H, Takeda S, Kanazumi N, Sugimoto Z, Nakao A. Hypermethylation of multiple genes as clonal markers in multicentric HCC. *British Journal of Cancer* 2007;97:1260-5.
 - Ibrahim AS, Zaghoul H, Badria FA. Case Report Evidence of Relationships between HCC and Ochratoxicosis. *PloS One*. 2013;8(8):1-8.
 - Kubo S, Nishiguchi S, Hirohashi K, Shuto T, Kuroki T, Minamitani S, et al. Clinicopathological criteria for multicentricity of hepatocellular carcinoma and risk factors for such carcinogenesis. *Japan J Cancer Res Gann*. 1998 Apr;89(4):419-26.
 - Feitelson MA, Sun B, Satiroglu Tufan NL, Liu J, Pan J, Lian Z. Genetic mechanisms of hepatocarcinogenesis. *Oncogene* 2002;21:2593-604.
 - Parikh CK. *Parikh's textbook of medical jurisprudence, Forensic medicine and toxicology*. 6th ed. New Delhi: CBS publishers and distributors; 2005. 4.89-90.