Comparison of Vacuum Assisted Closure Therapy with Standard Wound Therapy for Open Musculoskeletal Injuries

Ketan Gupta[1], Ajay Mundada[2], Adish Patil[3]

[1]Resident, [2]Resident, [3]Assistant Professor, Department of Orthopaedics

Krishna Institute of Medical Sciences Deemed University, Karad, Maharashtra, INDIA.

[1]ketangupta15@gmail.com, [2]ajaymundada15@gmail.com, [3]patil.adish@gmail.com

Research Article

Abstract: **The Primary objective** of this prospective randomised study is to compare the rate of infection, primary wound coverage, hospital stay and healing of soft tissue injury associated with open musculoskeletal injuries. **Materials and Methods:** Thirty patients with open musculoskeletal injuries were included in this study. They were divided in two groups of 15 each, Group A (VAC) and Group B (sterile dressing group) .All these patients had undergone wound debridement and fracture fixation. This was followed by application of Vacuum Assisted Closure (VAC) for Group A and sterile dressings for group B patients. The infection rate of these two groups was analysed by clinical signs and symptoms. **Results:** The infection rate in Group A is very low when compared to group B. The primary wound coverage can be done earlier in group A. The hospital stay is minimum in Group A and wound healing is also faster in Group A patients when compared to group B. **Conclusion:** This is a simple and low cost method for treating soft tissue injury associated with severe open Fractures. It can be done even in peripheral hospitals with low resources.

Key words: VAC, open fracture, sterile dressing, comparison.

Introduction

Open fracture is a surgical emergencies.[1] The annual incidence of open fractures of long bones has been estimated to be 11.5 per 100 000 persons with 40% occurring in the lower limb [9]. Open fractures still represent a major challenge for the treating surgeon and frequently demand a complex of soft tissue and bone procedures to achieve an undisturbed healing with adequate limb function. However, despite improvement in operative techniques and antibiotic therapy septic complications still occur in severe open fracture forms up to 50%.[6] Delayed wound healing is a significant health problem, particularly in older adults. In addition to the pain and suffering, failure of the wound to heal also imposes social and financial burdens.[2] Vacuum Assisted Closure (VAC) is a therapy that can be used on a variety of acute and chronic wounds to achieve either wound closure or prepare the wound bed for further surgical interventions.[3]. VAC therapy aids healing by, maintaining a moist wound environment, increase local blood flow, removing wound exudates, promoting granulation tissue, reducing infection and exerting mechanical pressure[4]. The primary objective of this prospective randomised study is to compare the rate of wound infection, primary wound coverage, hospital stay and healing of soft tissue injury associated with open fractures treated with two different standard techniques, Vacuum Assisted Closure (VAC) and sterile dressing.

Materials and Methods

All patients above 18 years of age with open musculoskeletal injuries in extremities that required coverage procedures were included in the study however, patients with pre-existing osteomyelitis in the wounds, neurovascular deficit in the injured limb, diabetics, malignancy, and peripheral vascular disease were excluded from the study.30 cases were divided into two groups of 15 each. Group A, vacuum assisted closure group (VAC) and group B sterile dressing group. The selection was made in a random manner. All these cases were treated with tetanus prophylaxis, standard antibiotics and other supportive measures. All of them had undergone wound debridement and fracture fixation. Subsequently the group A patients were treated with VAC application and the group b by sterile dressings.

Vacuum assisted wound therapy procedure

Any dressings from the wound were removed and discarded surgical debridement of necrotic tissue was done and fracture fixation was done under appropriate anaesthesia. Adequate haemostasis was achieved sterile, open-pore foam dressing was gently placed into the wound cavity. Open-pore foams are polyurethane with 400–600 microns size having hydrophobic open cell structured network. Such sizes of pores are most effective at transmitting mechanical forces across the wound and provide an even distribution of negative pressure over the entire wound bed to aid in wound healing. Sealing with drapes. The site was then sealed with an adhesive drape covering the foam and tubing and at least three to five centimetres of surrounding healthy tissue to ensure a seal. The application of negative pressure. Controlled pressure

was uniformly applied to all tissues on the inner surface of the wound. The pump delivered an intermittent negative pressure of −125mmhg. The cycle was of nine minutes in which pump was on for six minutes and off for three minutes. The dressings were changed on third or fourth day depending upon the amount of drain. The main outcome variables were presence of infection, time interval between initial injury and reconstructive soft tissue procedure, duration of hospital stay and complete healing of the wound. Wound infection was recorded as a binary variable -present or absent; infection was assessed on the basis of clinical signs and symptoms that included increasing drainage, increasing pain, purulent discharge and increasing erythema. Time interval for definitive soft tissue reconstruction was recorded as binary variables i.e. less than 3 weeks or more than 3 weeks and the hospital stay as less than one month and more than one month. The healing of the wound was recorded as binary variable ie., < 6 weeks and > 6 weeks.

Observation and Results

In our study, in group A there were 11males and 4 female and in group B there were 12 males and 3 female. Mean patient age was 39 ± 18 years (range, 18 to 76 years). All patients had suffered an acute trauma. Road traffic accident was found to be most common cause with 20 (66.66%) patients, followed by fall from height in 6 (20%) and by machinery injury in 4 (13.33%) patients. Wound infection occurred in 3 cases in group A and 11 cases in group B. Wound coverage was done within 3 weeks in 13 patients of group A and 3 patients in group B. Wound completely healed within 6 weeks in 13 patients of group A and 3 patients of group B. Similarly less than one month of hospital stay was required in 13 patients of group A and 3 patients in group B. Table-1 showing infected and non infected cases. Table-2 showing time taken for coverage of wound. Table-3 showing time taken for wound healing. Table-4 showing duration of hospital stay.

Table 1: showing infected and non infected cases

	Group A	Group B	Total
Infected Cases	03	11	14
Non infected Cases	12	04	16
Total	15	15	30

Table 2: Time taken for coverage of wound

	Group A	Group B	Total
Less than 3 weeks	13	03	16
More than 3 weeks	02	12	14
Total	15	15	30

Table 3: Time taken for wound healing

	Group A	Group B	Total
Less than 6 weeks	13	03	16
More than 6 weeks	02	12	14
Total	15	15	30

Table 4: Duration of hospital stay

	Group A	Group B	Total
Less than 1 month	13	03	16
More than 1 month	02	12	14
Total	15	15	30

Wound infection was found in 3 patients of group A and 11 patients in group B. On statistical analysis this difference was found to be highly significant (p value of 0.0092). Wound coverage was done within 3 weeks in 13 patients of group A and 3 patients in group B. On statistical analysis this difference was found to be highly significant (p value of 0.0007). Similarly the wound completely healed within 6 weeks in 13 patients of group A and 3 patients of group B. On statistical analysis this difference was found to be highly significant (p value of 0.0007). Case-1 30 yrs male patient with right side compound grade 3b (gustilo-anderson) comminuted proximal tibia fracture. Fracture stabilised with locking plate and VAC applied to the wound for a period of 16 days. Figure-1 showing the progress of wound. Case-2 35 years old male with right side compound grade 3a (gustilo-anderson) midshaft tibia fracture. Fracture stabilised with intramedullary nailing and VAC applied for a period of 20 days. Figure-2 showing the progress of wound.

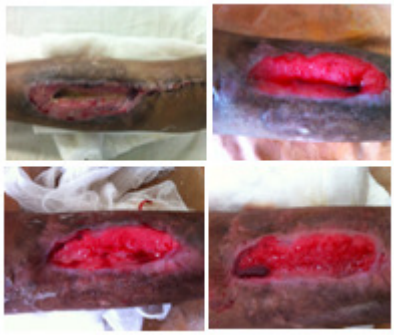

Figure 1

Figure 2

Discussion

The treatment of open fractures requires the simultaneous management of both skeletal and soft-tissue injury[9]. Although numerous papers have been published which suggest the technique may have an important role to play

in the management of many types of chronic or infected wounds, the cost of the system is such that some clinicians may be reluctant to use it until further prospective studies have been undertaken to demonstrate its cost effectiveness in routine use.[7] The cost of treating wounds with vacuum assisted closure therapy is comparable to the cost of conventional wound treatment. Hence, the method is cost-effective in treating categories of wounds for which the evidence indicates a shortened length of stay and reduced mortality[5] There is some evidence that VAC therapy yields fewer infections and wound complications than conventional wound treatment [5].The careful handling of soft tissues with radical debridement of all necrotic tissues, the early coverage of soft tissue defects and the osseous stabilization by minimal invasive implants contribute to the avoidance of infections [6]. Chronic infections with septic non-union are three times more frequently found in open fractures and correlated to the severity of soft tissue damage [6]. The high prevalence of microbial contamination of the open wounds predisposes to the development of infection which is related to the severity of the damage to the soft tissue [9]. In recent years the developement of packing wound caves with sponges and evacuation of interstitial tissue fluids and bacteria by continous drainage (vacuum assisted wound closure =VAC systems) gave remarkable results [6].

Conclusion

Since it is a cheap and useful technique using easily available materials, it can be done at any hospital, without much expertise. Adequate early debridement followed by application of primary VAC has reduced wound infection rate, time interval between soft tissue cover and initial injury and duration of hospital stay in patients with severe soft tissue injury associated with open fractures, and hence early wound healing can be achieved. It provides psychological, social and financial benefits to the patient by reducing the hospital stay and allowing early return to normal life.

References

1. Campbells operative orthopaedics eleventh edition.
2. Vacuum assisted closure for the management of wounds: an accelerated system review. Asernip-s report no 37 december 2003.
3. Management of vacuum assisted closure therapy.tissue viability clinical nurse specialist ,mr mark pemberton, vascular consultant nmcec.
4. Evidence review. Vacuum assisted closure therapy. Cep 08017. June 2008
5. Vacuum assisted wound closure therapy. Sbu alert report no 2011-09-2011-11-02.
6. Open fractures and infection Otevřené zlomeniny a infekce Th. Neubauer1, g. S. Bayer2, m.wagner.
7. An introduction to the use of vacuum assisted closure steve thomas phd, director, surgical materials testing laboratory,bridgend, wales, uk
8. Vacuum-assisted closure therapy from: the hospitalist, may 2007. A portable vacuum device improves upon this 20-year-old therapy. By m. Leijnen, md, msc, p. Steenvoorde, md, msc, l. Vandoorn, ma-npa, s.a. Da costa, md, phd, and j. Oskam, md, phd.
9. Review of the management of open fracture of the tibia and femur P. V. Giannoudis, bsc, mb, md, eec(orth), C. Papakostidis, and c. Roberts.