

Unusual Arterial Variation of Upper Limb – Case Report.

U.W. Mane^{1*}, S. R. Pandhare²

¹Assistant Professor, Department of Anatomy, Government Medical College, Nanded(MS), INDIA.

²Assistant Professor, Department of Anatomy, Government Medical College, Nagpur (MS), INDIA.

*Corresponding Addresses:

dr.uddhav.mane@gmail.com

Research Article

Abstract: Brachial artery, which is continuation of axillary artery extending from lower border of teres major muscle up to the neck of radius, where it divides into radial and ulnar arteries. In the present case two arteries in the right arm of a male cadaver were recorded. The one was normally positioned brachial artery & the other was variant brachial artery. The variant artery was observed to run superficial to both median nerve & normal brachial artery, termed as superficial brachial artery. This variant artery traversed distally as superficial ulnar artery, superficial to flexor muscles of forearm. Normal brachial showed a rare feature of giving origin to Radial artery and Common Interosseous artery.

Presence of Superficial Brachial Artery (SBA) can be hazardous because it is more vulnerable to injury. It can be used as a feeding artery to a free flap from medial arm skin.

Key word: superficial brachial artery, superficial ulnar artery, arterial variations, upper limb.

Introduction: Brachial artery is the main artery of the arm, which is direct continuation of axillary artery, beginning at the lower border of teres major and enters into cubital fossa accompanying the median nerve. Under the cover of bicipital aponeurosis, it divides into a larger ulnar artery and smaller radial artery anteromedial to the neck of the radius. Common interosseous artery arises from the ulnar artery which branches into anterior and posterior interosseous arteries.

Materials and Methods:

During routine undergraduate dissection hours, we observed an unusual and interesting variation in the arteries of right arm of a male cadaver. The specimen was carefully dissected, cleaned under water, and then dried well with acetone. Later that was painted with fabric red colour paint, and photographed.

Observations:

In the present case, there were two brachial arteries in the right arm of a male cadaver. Variant brachial artery arose from axillary artery, it passed between two heads of the median nerve; it lied anterior to median nerve, following medial border of the biceps muscle. At the same time there was also the normally positioned brachial artery seen. This variant artery was termed as Superficial Brachial artery¹. This superficial brachial artery continued in forearm as superficial ulnar artery². The superficial ulnar artery as named so since, it had superficial course immediately beneath antibrachial fascia, running obliquely downward over the origin of pronator teres and superficial to other flexor muscles of forearm. Normally positioned brachial artery continued in forearm as radial artery and common Interosseous artery².




Figure I:
In the arm: Variant “superficial” Brachial Artery (SBA) run superficial to median nerve (MN) & brachial artery (BA).

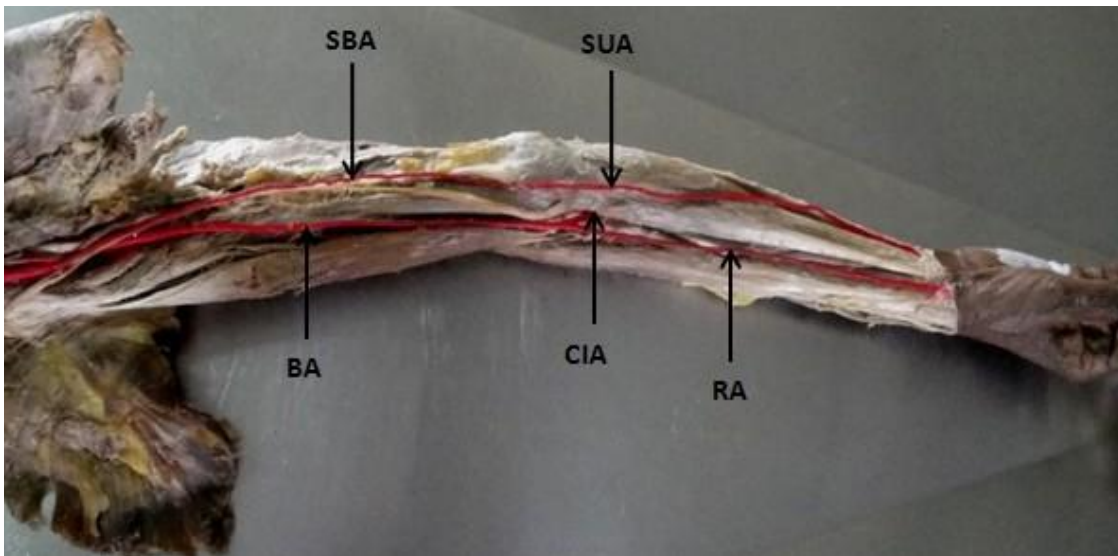


Figure II:
In cubital fossa: Superficial Brachial Artery (SBA) continues as Superficial Ulnar Artery (SUA) and Brachial Artery (BA) divides into Common Interosseous Artery (CIA) & Radial Artery (RA).

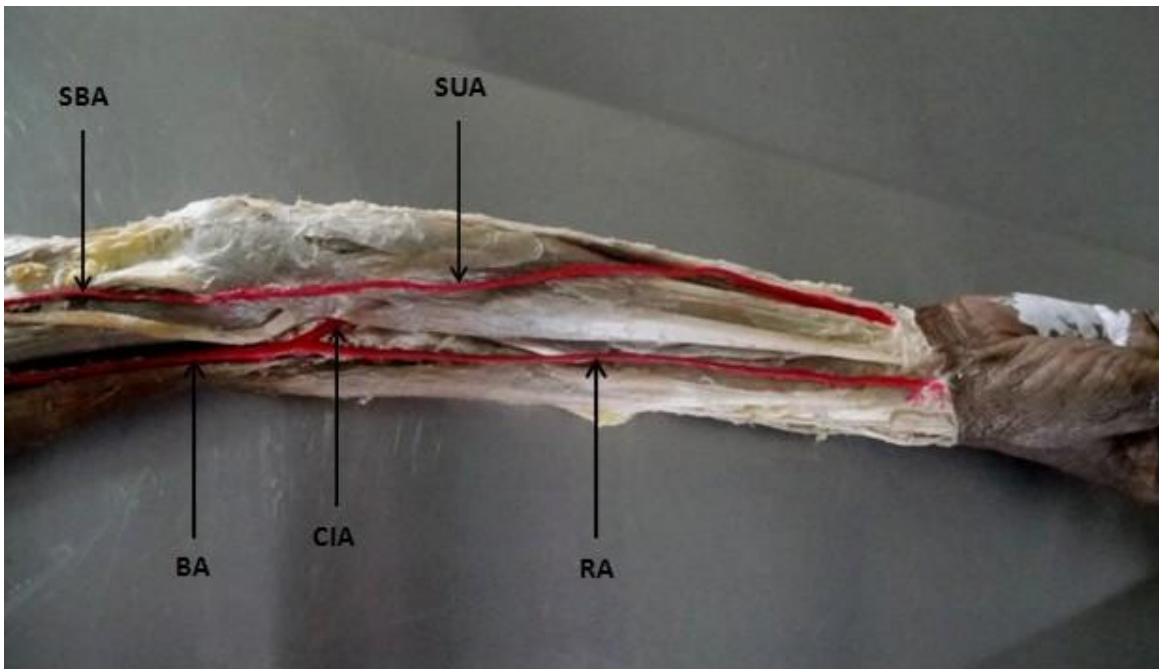


Figure III:
In the forearm: Superficial Ulnar Artery (SUA) run superficial to flexor muscles of Forearm

Abbreviations:

SBA: Superficial brachial artery
BA: Brachial Artery
SUA: Superficial Ulnar artery
RA: Radial artery
CIA: Common Interosseous Artery
MN: Median Nerve

Discussion:

The distribution and course of the arteries of superior extremity of human beings are subject to multiple variations at different levels, as reported in earlier studies (Baeza, 1995)³.

Various authors like, M Rodriguez-Niedenfuhr et al (2001)⁴, Bilodi AK et al (2004)⁵, Hee-Jun Yang et al (2007)⁶ have studied variations of brachial arteries. They mentioned that Superficial Brachial Artery lies superficial to median nerve and may continue as, (1) ulnar & radial arteries, (2) superficial radial artery, (3) superficial ulnar artery in the forearm or (4) may terminate in

arm only after giving some muscular branches.

In the present case, there was a Superficial Brachial Artery that passes superficial to median nerve and then continued as superficial ulnar artery in the forearm. Superficial ulnar artery passes deep to bicipital aponeurosis and superficial to flexor muscles of forearm. Occasionally this arterial pattern also labelled as superficial brachioulnar artery⁶. The Brachial Artery bifurcates just opposite neck of radius into Radial Artery and Common Interosseous Artery.

Conclusion:

Superficial position of brachial artery not only makes it more vulnerable to trauma and thus to bleeding but also more accessible to cannulation if needed. It may be mistaken for a vein and if certain drugs are injected into it, such an accidental intra-arterial injection, causing thrombosis or

gangrene of the arm or fingers⁷. SBA can be used as a feeding artery to a free flap from medial arm skin. Considering these possible complications and benefits, investigations of the arterial pattern in patient's arms before any invasive procedures may be helpful in avoiding iatrogenic injury or in using an SBA for some procedures. Doppler ultrasound imaging or angiography can assist healthcare providers in treating patients with an SBA. Duplex ultrasonography for detecting peripheral vascular injuries and Doppler pressure studies for examination of arterial pressure index are commonly used diagnostic procedures in vascular surgery (Johansen et al., 1991; Taub et al., 1999)^{8,9}. Whether those devices are available or not, anatomical knowledge of the SBA is essential. Hence it has been studied and reported.

Acknowledgment:

My sincere thanks to head of department, senior teachers, colleagues and all staff members

References:

- [1] W. Henry Holinshed. Anatomy for surgeons: vol.3 (The Back And Limbs). 3rd Ed., Philadelphia, Harper & Row. 362, 1982.
- [2] Rodriguez-Baeza, A., Nebot J., Ferreira B., Reina F., Perez J., Saundo J. R. & Roig M. An anatomical study and ontogenetic explanation of 23 cases with variations in the main pattern of the human brachio-antebrachial arteries. *J. Anat.* 187: 473-479, 1995.
- [3] M Rodriguez-Niedenfuhr at al. Variations of the arterial pattern in the upper limb revisited: a morphological and statistical study, with a review of the literature. *J. Anat.* 199: 547-566, 2001.
- [4] Bilodi AK, at al. Variations in termination of brachial artery – A case report. *Kathmandu University Medical Journal.* 2, 1. 49-51, 2004.
- [5] Hee-Jun Yang, at al. Variations of the Superficial Brachial Artery in Korean

- Cadavers. *J Korean Med Sci.* 23. 884-887, 2008.
- [6] Patnaik VVG, Kalsey G, Singla RK. Branching Pattern of Brachial Artery- A Morphological Study. *J Anat Soc Ind.* 51, 2. 176-86, 2002.
- [7] Johansen K., Lynch K., Paun M. & Copass M. K. Noninvasive vascular tests reliably exclude occult arterial trauma in injured extremities. *J. Trauma.* 31. 515-522, 1991.
- [8] Taub J.; Giannikis G.; Shen H.Y. & Kim U. The Brachial artery transection following closed elbow dislocation. *J. Trauma.* 47, 1. 176-178, 1999.