

# Aberrant Right Renal Artery- A Case Report

S G Kawale<sup>1\*</sup>, G L Maske<sup>2</sup>, A D Kannamwar<sup>3</sup>, S E Shaikh<sup>4</sup>, S V Pandit<sup>5</sup>

<sup>1</sup>Junior resident III, <sup>2,3</sup>Assistant Professor, <sup>4</sup>Professor and HOD, Department of Anatomy, Shri V. N. Government Medical College, Yavatmal, Maharashtra, INDIA.

<sup>5</sup>Associate Professor, Department of Anatomy, Government Medical College, Akola, Maharashtra, INDIA.

Email: [sugat\\_kawale@yahoo.com](mailto:sugat_kawale@yahoo.com)

## Abstract

During routine undergraduate dissection of abdomen in middle aged male cadaver we encountered an unusual variation. This was aberrant right renal artery arising from superior mesenteric artery. There were no variation on left side and other branches of abdominal aorta and there courses were normal. Clinical implication and embryological basis of this type of variation will be discussed.

**Key words:** accessory renal artery, branches of abdominal artery, renal artery, upper polar artery.

## \*Address for Correspondence:

Dr. S G Kawale, Shri V. N. G. M. C., Yavatmal, 445001. Maharashtra. INDIA.

Email: [sugat\\_kawale@yahoo.com](mailto:sugat_kawale@yahoo.com)

Received Date: 22/11/2019 Accepted Date: 30/12/2019

Access this article online	
Quick Response Code:	Website: <a href="http://www.statperson.com">www.statperson.com</a>
	Volume 10 Issue 1

terminologies related to aberrant renal artery and an accessory renal artery. An accessory renal artery is one that is accessory to main artery accompanying the same towards the hilum to supply it, while the aberrant renal artery supplies the kidney without entering its hilum. Aberrant renal artery entering superior renal pole is called as superior polar artery and aberrant renal artery entering inferior renal pole is called as inferior polar artery.<sup>1</sup>

## MATERIAL AND METHOD

Conventional Dissection technique

## OBSERVATION AND RESULT

During routine undergraduate dissection of abdomen in middle aged male cadaver we encountered an unusual variation. These was aberrant right renal artery arising from superior mesenteric artery. Aberrant renal artery entered into kidney from its capsule to upper pole of kidney, hence called superior polar artery. There were no variation on left side and other branches of abdominal aorta and there courses were normal as well as remaining branching pattern of superior mesenteric artery was also normal. This aberrant renal artery had a parallel course with that of the normal right renal artery lying superior to it (figure 1). In this case we also noticed that right kidney was situated in higher position than that of the left kidney (figure 2).

## INTRODUCTION

The renal arteries are a pair of lateral branches arising from the abdominal aorta below the level of superior mesenteric artery at the upper border of first lumbar vertebra for left kidney and upper border of third lumbar vertebra for right kidney. The paired renal arteries take about 20% of the cardiac output to supply kidneys that represent less than one-hundredth of total body weight.<sup>1</sup> The right renal artery is longer in its course than left renal artery because of the location of the abdominal aorta which is more towards left side of midline. Each renal artery is divided into anterior and posterior division, at or very close to the hilum of the kidney. Further it is divided into segmental branches to supply respective segments of the kidney, being themselves as end arteries. Variation in number, source, branching and course of the renal arteries are very common. These accessory or aberrant renal arteries account for about 30% of existence, while 70% owes normal type. Further there is a difference in

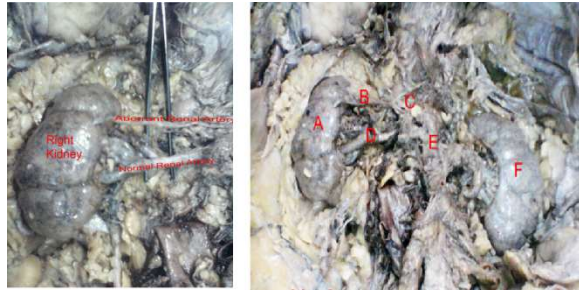


Figure 1

Figure 2

**Legend Figure 2:**

A – Right Kidney, B – Aberrant Renal Artery, C – Superior Mesenteric Artery, D – Right Renal Artery, E – Abdominal Aorta F – Left Kidney

**DISCUSSION**

Presence of unusual branching pattern of renal arteries are not uncommon. In 70% cases, there is single renal artery supplying each kidney. Considering this fact, multiple branching pattern of renal arteries may not be uncommon finding, the clinical implication of such an anomaly need to be given due attention. Presence of variant renal arteries may be associated with other underlying pathological condition. T. Ramesh rao<sup>2</sup> (2011) observed an unusual variation in the vascular supply to the kidney on the right side of 60 years old male cadaver. He observed aberrant right renal artery originated at the level of lower border of L1 vertebra along with the origin of the normal right renal artery Such variation not found on opposite side. Patient with such variation may be asymptomatic. Kanaskar N. *et al*<sup>4</sup> (2012), observed that two additional renal arteries arises right side from abdominal aorta. The artery cranial to normal renal artery entered the anterior aspect of the kidney 4 cm below the upper pole. The second artery was caudal to the normal renal artery. This artery entered the lower pole of kidney. In a patient of Systemic hypertension, Cerny J. C. *et al*<sup>5</sup> (1973), observed normal left renal artery and aberrant right renal artery arising at eleventh thoracic vertebra, during the procedure of Abdominal aortogram. Selective injection of aberrant right renal artery also shows aneurysm at segmental bifurcation and cortical atrophy of lower pole. Most of the abnormalities of renal artery are due to changing position of kidney as a part of its normal

development and ascent. The kidney begins their development in pelvic cavity. During further development they ascent to lumbar region which is their final position. When they are in pelvic cavity they are supplied by internal or common iliac artery. While kidney ascent to lumbar region their arterial supply also shift from common iliac to abdominal aorta<sup>3</sup>. In this case, the variation of aberrant renal artery arising from superior mesenteric artery may be due to the higher position of right kidney than that of the left kidney (figure 2). The increasing use of invasive diagnostic and interventional procedure in cardiovascular diseases, advent of laparoscopic renal surgeries and donor nephrectomies makes it important for the surgeons to understand the abnormality or variation in the renal vasculature. Knowledge of the existence of aberrant renal arteries is important because they may be inadvertently damaged during renal surgery and their presence must be considered in evaluating a donor kidney for possible renal transplantation.

**CONCLUSION**

In this case, we found a rare variation associated with the renal vasculature, in the form of right superior polar artery, in addition to normal right renal artery. Existence of the aberrant renal arteries are accountable in cases of surgical approaches, pathological conditions and radiological interventional.

**REFERENCES**

1. Standing S., Grays anatomy. The anatomical Basis Of Clinical Practice. 40<sup>th</sup> ed. 2008. Urogenital System. Ch. 74. Pg-1231-32.
2. T. Ramesh Rao. Aberrant Renal Artery and Its Clinical Sinignificant. International Journal Of Anatomical Variation. 2011. Pg-37-39.
3. Moore K. L., Persaud TVM. The Developing Human, Saunders. An Imprint Of Esevier. 9<sup>th</sup> ed., Pg- 175-176.
4. Neelesh Kanaskar., Vaishali Paranjape., Jyoti Kulkurni., Sapna Shevade. Double Accessory Right Renal Arteries.2012. IOSR Journal Of Dental and Medical Science., vol 1 (5). Pg- 17-20.
5. Joseph C. Cerny., Daniel Karsch., Aberrant Renal Artery. Urology. December1973. vol 2 (6). Pg-623-626.

Source of Support: None Declared  
Conflict of Interest: None Declared