

# Pericolic abscess due to large bowel perforation by fish bone – a case report

Vijay Kalimuthu<sup>1\*</sup>, Jawahar Krishnaswamy<sup>2</sup>, Anitha Samraj<sup>3</sup>, Ravishankar Jayavelu<sup>4</sup>

<sup>1</sup>Assistant Professor, <sup>2</sup>Associate Professor, <sup>3,4</sup>Professor, Department of Surgery, Saveetha Medical College and Hospital, Saveethanagar, Thandalam, Tamil Nadu-602105, INDIA.

Email: [viji\\_00765@yahoo.co.in](mailto:viji_00765@yahoo.co.in), [drkjawahar@gmail.com](mailto:drkjawahar@gmail.com), [anitaamarsamraj@gmail.com](mailto:anitaamarsamraj@gmail.com), [drjvrs@yahoo.com](mailto:drjvrs@yahoo.com)

## Abstract

A diagnosis of large-bowel perforation, caused by a sharp or pointed foreign body, is rarely made preoperatively because the clinical symptoms are usually nonspecific and can mimic other surgical conditions, such as appendicitis and diverticulitis. Less than 1% of ingested foreign body results in perforation from mouth to anus mostly by sharp objects. Of these sharp objects, chicken bone and fishbone account for half of the reported perforations. The most common sites are the ileo-caecal junction and sigmoid colon. In our case the patient presented late with pericolic abscess following the perforation by a fish bone in proximal ascending colon and the fish bone found extramurally making it as first case for that site of large bowel perforation by a fish bone with localized late presentation.

**Keywords:** fish bone, Pericolic abscess.

## \*Address for Correspondence:

Dr. Vijay Kalimuthu, Assistant Professor, Department of Surgery, Saveetha Medical College and Hospital, Saveethanagar, Thandalam, Tamil Nadu-602105, INDIA.

Email: [viji\\_00765@yahoo.co.in](mailto:viji_00765@yahoo.co.in)

Received Date: 03/12/2020 Accepted Date: 13/01/2021

Access this article online	
Quick Response Code:	Website: <a href="http://www.statperson.com">www.statperson.com</a>
	Volume 11 Issue 1

## INTRODUCTION

A variety of foreign bodies are encountered on abdominal x-rays in emergencies. Most of its ingestion are accidental, but there may be other factors for ingestion such as mental disorder, bulimia, alcoholism. Usually they pass spontaneously through the entire alimentary tract but not so in case of sharp materials where, impaction and perforation are common. These perforations usually presents as emergency but rarely a late presentation can be encountered. We report this rare and late presentation of such perforation in ascending colon by a sharp fish-bone.

## CASE REPORT

A 49 year old male patient was admitted from OPD with complaints of abdominal pain for past 4 weeks in lower

abdomen radiating to right lumbar region which was Intermittent, dull aching and relieved on medications. There was few episodes of mild fever for four weeks. No other symptoms like nausea, vomiting, loose stools, constipation, urinary disturbances. Patient had loss of appetite with no loss of weight. He was recently diagnosed as type2 diabetes mellitus on oral hypoglycaemic agents. There was no similar episodes in the past and no previous abdominal surgery. Patient was under medications with analgesics and antibiotics for the above complaints in several private facilities. On examination he was afebrile with stable vital signs. Abdominal was soft with mild tenderness in right iliac fossa with no palpable mass or organomegaly. Digital rectal examination was normal. Other systemic examinations were normal. Ultrasonogram of abdomen was done which suspected colitis. CECT abdomen showed mild soft tissue thickening along lateral aspect of proximal ascending colon and caecum with marked fat stranding – likely inflammatory. A thin linear hyper density seen within the soft tissue density - foreign body. Few lymph nodes in right iliac fossa likely reactive. Final impression was to rule out sealed perforation by foreign body. Other minor findings were minimal thickening of appendix likely reactive and minimal bladder wall thickening likely mild cystitis. Elective Laparotomy was planned and proceeded to find no free fluid in the

peritoneal cavity with Omental adhesions in right paracolic gutter. Pericolic abscess on the lateral wall of proximal ascending colon found and 20 ml pus drained. After drainage a sharp pointed fishbone of about 4 cm present freely in the cavity. Lateral wall of colon was thickened and sealed perforation was suspected. Peritoneal lavage done. Closed non-suction drainage tube

kept in pelvis. Post-operative period was uneventful. Drainage tube was removed on fifth postoperative day. Sutures removed on the eighth day and also CT done to confirm no residual or recurrent abscess. Patient on follow up after two weeks and eight weeks with healthy wound and normal bowel habits and no specific complaints.



Figure 1: Fish bone of length 4cm

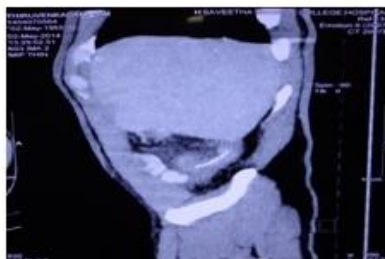

Figure 2: Saggital section in CECT showing linear foreign body

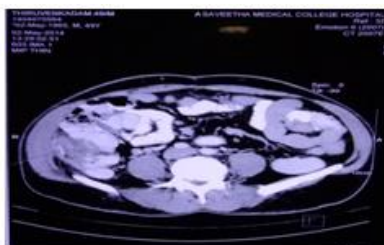


Figure 3: Coronal section in CECT showing foreign body inside an soft tissue stranding lateral to proximal ascending colon

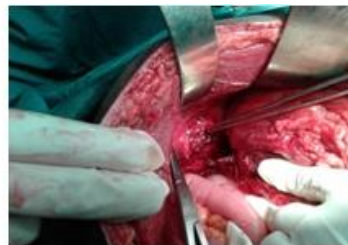


Figure 4: Per-operative picture showing site of pericolic abscess after drainage

## DISCUSSION

Foreign bodies such as fish bones, chicken bones, toothpicks and even dentures have been known to cause intestinal perforation. Perforation usually occurs at the point of acute angulation and narrowing. The risk of perforation is related to the length and the sharpness of the object. Perforation commonly occur at the ileo-caecal junction and sigmoid colon. Other potential sites are the duodeno-jejunal flexure, appendix, colonic flexure, diverticulae and the anal sphincter. Perforations can be secondary to colonic diverticulitis and colonic carcinoma. Even colovesical or colorectal fistulas have been reported as being caused by chicken bones. The predisposing factors for ingestion of foreign bodies may be due to defective tactile sensation of the palate, sensory defects due to cerebro-vascular accident, achlorhydria where the foreign body passes unaltered from the stomach, previous bowel surgery causing stenosis and adhesions and diverticula predisposing impaction. Overeating, rapid eating, or a voracious appetite may be contributing factors for ingesting fish or chicken bones. The mean time from ingestion to perforation is 10.4 days. In cases when objects fail to pass the tract in 3 to 4 weeks, reactive

fibrinous exudates due to the foreign body may cause adherence to the mucosa, and objects may migrate outside the intestinal lumen to unusual locations such as the bladder, liver, and peritoneal cavity. The length of time between ingestion and presentation may vary from hours to months and in unusual cases to years. In our case the average duration between ingestion of foreign body and presentation was around 28 days. In most of the cases, definitive preoperative history of foreign body ingestion is uncertain and intestinal perforations are rarely diagnosed preoperatively because clinical symptoms are usually non-specific and mimic other surgical conditions, such as appendicitis and diverticulitis. Patients with foreign body perforations in the stomach, duodenum, and large intestine are significantly likely to be febrile with chronic symptoms with a normal more total white blood cell count compared to those with foreign body perforations in the jejunum and ileum. CT scans are more informative especially if radiographs inconclusive. Contrast studies with Gastrograffin may be required in excluding or locating the site of impaction of the foreign body as well as determining the level of a perforation. Using contrast is important in identifying and locating

foreign bodies if intrinsically non-radiopaque substances, such as fish and chicken bones are ingested. The identification of a foreign body with an associated mass or extraluminal collection of gas in patients with clinical signs of mechanical bowel obstruction, peritonitis, pneumoperitoneum strongly suggests the diagnosis. Whenever a diagnosis of peritonitis subsequent to foreign body ingestion is made, an exploratory laparotomy is performed. The most common treatment was simple suture of the defect. For the cases with no evidence of perforation, surgical removal of the foreign body is indicated if the foreign body has sharp points or if it remains in one location for more than 4 to 5 days especially in the presence of symptoms. In recent years, laparoscopy has been increasingly recognized as a procedure offering precise, visual assessment of the intra-abdominal condition, allowing consequent prompt intervention.

## CONCLUSION

Colonic perforation by foreign body can mimic appendicitis or diverticulitis. Late presentation of foreign body perforation is difficult to diagnose without the aid of imaging modalities. Rarely, a perforated foreign body can form a pericolic abscess adjacent to the perforated colon with non-specific symptoms.

## REFERENCES

1. Hsu SD, Chan DC, Liu YC. Small-bowel perforation caused by fish bone. *World J Gastroenterol* 2005; 11(12): 1884-1885
2. Arif HS, Hakim IS, Asim MP, Fazl QP, Rubina L, Khurshid AW. Gastro Intestinal tract perforations due to ingested foreign bodies; a review of 21 cases. *BJMP* 2012;5(3):a529
3. Pinero MA, Fernandez Hernandez JA, Carrasco PM, Riquelme RJ, Parrilla PP. Intestinal perforation by foreign bodies. *Eur J Surg* 2000; 166: 307-309
4. Chu KM, Choi HK, Tuen HH, Law SYK, Branicki FJ, Wong J. A prospective randomized trial comparing the

- use of the flexible gastroscope versus the bronchoscope in the management of foreign body ingestion. *Gastrointest Endosc* 1998; 47:23-27
5. Chang JJ, Yen CL. Endoscopic retrieval of multiple fragmented gastric bamboo chopsticks by using a flexible overtube. *World J Gastroenterol* 2004; 10: 769-770
6. Webb WA. Management of foreign bodies of the upper gastrointestinal tract. *Gastroenterology* 1988; 94: 204-216
7. Hunter TB, Taljanovic MS. Foreign bodies. *Radiographics*. 2003 May Jun;23(3):731-57.
8. Eisen GM, Baron TH, Dominitz JA, et al. Guideline for the management of ingested foreign bodies. *Gastrointestinal Endosc*. 2002;55:802-6.
9. Stack LB, Munter DW. Foreign bodies in the gastrointestinal tract. *Emerg Med Clin North Am*. 1996 Aug; 14(3):493-521.
10. Eftaiha M, Hambrick E, Abcarian H. Principles of management of colorectal foreign bodies. *Arch Surg*. 1977;112:691-5.
11. Puia I.C, Puia V.R, Andreescu A, Cristea P.G. Ascending colon perforation by ingested fruit stones. *Chirurgia (Bucur)* 2011; 106(6):825-827.
12. Chiru JJ, Chen T.L, Zhan Y.L. Perforation of the transverse colon by a fish bone: case report. *J Emerg Med* 2009; 36(4):345-347.
13. Joglekar S, Rajput I, Kamat Sachin, Downey S. Sigmoid perforation caused by an ingested chicken bone presenting as right iliac fossa pain mimicking appendicitis: a case report. *J Med Case Rep*. 2009; 3:7385.
14. Ali F.E, Al-Busairi W.A, Esbaita E.Y, Al-Bustan M.A. Chronic perforation of the sigmoid colon by foreign body. *Curr Surg*. 2005; 62(4):419-422.
15. Ben Rejeb A, Gammoudi A, Ben Alaya M. Intestinal Perforation by Fish Bone. Apropos of a Case and Review of the Literature. *Ann Chir* 1993; 47(1): 86-70. (Abstract).
16. Chuvilkin AV. Case of Large Bowel Perforation by a Fish Bone. *Wiad Lek* 1973; 26(8): 761-3.
17. Chen CK, Su YJ, Lai YC, et al. Fish Bone-Related Intra-Abdominal Abscess in An Elderly Patient. *Int J Infect Dis* 2010; 14(2): e171-2.

Source of Support: None Declared  
Conflict of Interest: None Declared