

Study of management of superficial burn wounds (up to 30%), using camphor and coconut oil, in 2000 patients

S P Jadhav¹, Ritvik Jaykar², Shrikant Makam^{3*}, S P Patankar⁴

¹Professor, ²Associate Professor, ³Assistant Professor, ⁴Ex. Resident, Department of Surgery, Dr. V. M. G. M. C. Solapur, Maharashtra, INDIA.
Email: drshrimakam@gmail.com

Abstract

The authors report their experience with Management of Burn wound with Camphor and Coconut Oil in 2000 Patients, From January 2000 to January 2014. The patients having superficial burns involving 30% or less than 30% were selected for the study. There were no major complications and no mortality in the series. The advantages exceed that of conventional dressing methods. Advantages like decreased duration for wound healing, decreased pain, decreased hospital stay with early return to routine activities and finally better cosmesis were seen. It also decreased the cost compared to other methods which needs costly dressing materials.

Keywords: Camphor oil, coconut oil, burn wound of 30% and less.

*Address for Correspondence:

Dr. Shrikant Makam, Assistant Professor, Department of Surgery, Dr. V. M. G. M. C. Solapur, Maharashtra, INDIA.

Email: drshrimakam@gmail.com

Received Date: 23/05/2021 Revised Date: 02/06/2021 Accepted Date: 06/07/2021

Access this article online	
Quick Response Code:	Website: www.statperson.com
	Volume 11 Issue 3

INTRODUCTION

Body burns is the frequent condition seen in India due to accidental, suicidal, or homicidal incidents. It may be seen in form of flames, scalds, chemical or electric burns requiring emergency treatment. Sushrut described classification of burn wound in sushrutsamhita 7000 years back, where he also mentioned various herbs and oils for their management¹. Egyptians, Chinese, Romans and other Indian scholars also mentioned various herbal treatments². Burn wounds are supposed to be notoriously get infected if not taken care well³. Today there are number of newer dressing techniques available which are quite effective in wound healing but at a higher cost which makes them unaffordable for poor and needy patients in developing and underdeveloped countries.⁴

Here we have tried different method which is cost effective as well as proves to be better wound healing technique for burn wound management using camphor and coconut oil.⁴

AIMS AND OBJECTIVE

1. To study the rate of wound healing.
2. To study the effect of this technique on pain in selected patients.
3. Evaluation of the procedure in terms of wound infection and cosmesis of scar.
4. Evaluation of the procedure in terms of cost of procedure and hospital stay.

MATERIALS AND METHOD

This study includes 2000 cases of superficial Burns of 30% and less than 30% ,who were willing to participate for the procedure and study.

EXCLUSION CRITERIA

- Burns more than 30%
- Deep burns like electric and chemical burns
- Female patients of buens with pregnancy.
- Patient not willing for procedure and not willing to participate in study.
- Patient in septic shock.
- Patients age above 60 years.

- History of burns more than 72 hrs before and untreated.
- Old cases and infected cases of burns.
- Patients of immune compromised states (e.g. HIV infection, patients on steroids or immunosuppressants.)

Patients selected with respect to above criteria were included in this study, were admitted in hospital and routine investigations performed like hemogram, serum electrolytes, serum creatinine, blood urea, serum bilirubin, HIV test and chest x ray if necessary.

METHOD

Preparation of camphor and coconut oil mixture



Figure 1: Ingredients used for preparation

This mixture is prepared by mixing 50 ml of coconut oil, and 4-5gms of camphor, both of which are commercially available at very low cost. Coconut oil act as solvent for the camphor and thus we get a homogenous mixture for application over burn wounds. This proportion of both components was maintained as per the need of quantity of mixture required, depending upon percentage of burns. This preparation of camphor and coconut oil mixture was

used for study. Before application of this mixture, procedure was described to every patient. Initially wounds were cleaned with normal saline, blebs were aspirated and dead skin removed. Then with the help of sterile cotton above prepared mixture was applied over wound gently, starting from centre and moving to the periphery of wound and over few cm of normal skin. This procedure was repeated three times a day for 5-6 days, by that time patients developed epithelialization. All patients were advised daily soap bath and drying the wounds with clean clothes. After application of camphor and coconut oil, wounds were kept open in hygienic condition. The application of the mixture was continued till patient gets complete wound healing with epithelialization and a steady cosmetic result. In case of superficial burns excellent healing was observed.

Medicinal aspects of Camphor

Camphor is having antibiotic action, antiseptic action proved on Mueller hinton agar impregnated with it, and then inoculated with various skin pathogenic microorganisms. It increases microcirculation and stimulates healing process at molecular level, and reduces peripheral pain impulses. Except these properties it is also mildly cardio respiratory stimulant and CNS stimulant.⁶

Medicinal aspects of coconut oil

It is rich source of saturated medium chain fatty acids, which acts as effective anti-oxidants minimizing further skin damage and when broken into molecules, they act as an effective anti-microbial. The coconut oil forms a protective antiseptic layer over the wound when applied under aseptic precautions.⁷

OBSERVATIONS AND ANALYSIS

Table 1: Age distribution

Age in years	No. of patients
1-10	350
11-20	300
21-30	670
31-40	330
41-50	140
51-60	210
Total	2000

Above table shows maximum cases in our study group were in the age group 21-30 yr.

Table 2: Sex distribution

Sex	Male	Female
No. of patients	820	1280

Incidence of burns observed in our study is higher in females.

Table 3: Camphor and Coconut oil Sensitivity

Sr. No	Organism	No. of strains	No. of strains inhibited		
			0	1+	2+
1	Staphylococcus coagulase –ve	6	-	3	3
2	Staphylococcus coagulase +ve	5	-	2	3
3	Pseudomonas	2	-	2	-
4	Proteus	5	-	1	4
5	e.coli	2	1	1	-
6	Klebsiella	4	2	-	2

Sr. No.	Organism	Percentage of growth inhibited (%)		
		Partial	Complete	Resistance
1	Staphylococcus coagulase –ve	50	50	No
2	Staphylococcus coagulase +ve	40	60	No
3	Pseudomonas	100	-	No
4	Proteus	50	50	No
5	e.coli	80	20	No
6	Klebsiella	50	50	No

Thus from above observation, we can conclude that camphor and coconut oils are having effective antimicrobial properties.



Figure 2: No growth on camphor and coconut oil mixture

Table 4: Incidence of infection	
No infection	Infection noted
1820 (91%)	180(9%)

Infection was detected in 180 patients was mainly because of lack of basic hygienic practices in those patient group.

Table 5: Pain assessment

	Significant pain		Insignificant pain		No pain	
VAS	10	8	6	4	2	0
No. of patients	14	67	21	212	1436	250
Total	102		1648		250	

Analgesics were mainly needed for pediatric patients. Pain assessment was done using visual analogue scale.⁸

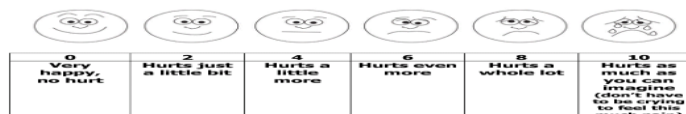


Figure 4: Visual Analogue Scale

Table 6: Scarring

No scar	Minimal	Hypertrophied scar	Keloid	contracture	Total
270	1680	40	18	2	2000

Cosmesis was assessed using Vancouver scar scale scoring system⁹, repeatedly on follow up examination. (6 weeks, 3month, 6year and 1 year)

Table 7:

Points	Vascularity	Pigmentation	Pliability	Height in mm
0	Normal	Normal	Normal	Normal (flat)
1	Pink	Hypopigmentation	Supple	0 – 2
2	Red	Hyperpigmentation	Yielding	2 – 5
3	Purple	-	Firm	-
4	-	-	Banding	-
5	-	-	Contracture	-
Total score			13	

Result	Vancouver scar scale score	No. of cases	Percentage
No scar	0	270	13.5%
Minimal scar	3	1680	84%
Hypertrophic scar	10	40	2%
Keloid	12	18	0.9%
Contracture	13	2	0.001%

Cosmesis observed was very good in maximum no. of patients (97.5%) with use of camphor and coconut oil.

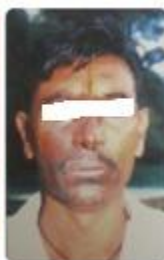
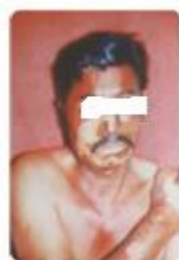
Figure 5: 27 % Burns before and after treatment

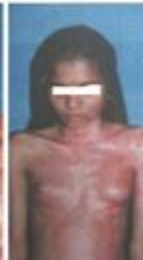
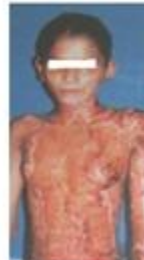
Figure 6: 12% Burns before and after treatment

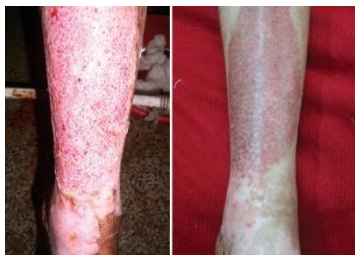

Figure 7: 9 % burns before and after treatment

Table 8: Duration and average stay in hospital

Burn woun	No. of patients	No. of days
1-10	570	5.2
11-20	835	5.6
21-30	595	6.2

The average duration of hospital stay observed in our study patients was 5.6 days.

RESULTS AND DISCUSSION

The procedure was performed successfully in almost all patients, with exception of few who developed infection because of their unhygienic habits and associated comorbidities. Few failures of wound healing were due to malnutrition status. The mean healing time was approximately 5 days, which is equivalent and seems to be better as compared to other costly dressing procedures. There were no major complications, no mortality was noted. Post procedural pain was significantly less, assessed by visual analogue scale. The mean hospital stay was 6 days for the series with early return to routine activities. Few cases of wound infection and contracture were also noted. The cosmesis of scar was assessed by Vancouver scar scoring system which yields better perception for cosmesis. The mean VSS score was 1.8. The cost reduction is obvious because it obviates the need of costly dressing materials with operation room infrastructure with its maintenance and special drugs (anesthetic agents and sedatives etc.); the procedure requirements are only standard set up for indoor facility and basic materials which were made available at our institute. No patient was given any type of anesthesia for the procedure. As there is no removal of dressing needed, pain due to that, which invariably occurs due to removal of dressing is avoided. Patients need for anesthesia during conventional change of dressing is also avoided.

CONCLUSION

Though modern dressing techniques are increasingly being used for burn wound management with good result, they are out of reach for poor patients because of their cost and unavailability at peripheral centers and hospitals.^{10, 11} So to fill this gap and to overcome it, our new method of camphor and coconut oil mixture dressing for burn wounds could be rewarding. There are minimal complications regarding wound healing. Quality of patients life is improved, as there is less pain in this technique, with improved wound healing rate which leads to decreased hospital stay and early return to routine activities. This mixture of camphor and coconut oil also

gives cost benefit and excellent cosmesis. This is also socially acceptable without undue side effects and seems to have a far better patient acceptability, giving good cosmetic as well as functional results. Even we have observed that these patients never had cross infections from other patients. In ward where these patients were kept, never smelled badly, on the contrary ward environment used to have a pleasant smell of camphor and coconut oil mixture. There was no need for use of face masks or caps during the procedure or patients care. This kind of ambience motivated patients for better healing and they got a mental support to get rid of traumatic events earlier.

REFERENCES

1. Sushrutsamhita
2. Dravya gun widyan
3. Branski K. L., Al-Mousawi A., Rivero H., Jeschke M. G., A.P. Sanford, and Herndon D.N. Emerging Infection in burns. *Surg. Inf.* vol 10. (2009). 5:389-397.
4. Raghad Q. Majeed :Department of Biology, College of Science, University of Baghdad , Baghdad , Iraq, Prophylactic effect for the sesame oil and camphor oil on the infected burn skin of mice ,*Tikrit Journal of Pure Science* 17 (4) 2012 ISSN: 1813 – 1662
5. Atiyeh B.S., Gunn S. W., Hayek S.N. State of the art in burn treatment. *World J. Surg.* (2005).29:131-48.
6. Paul M.I., Beiler J.S., King T.S., Clapp E.R., Vallati J., Berlin C.M."Vapor Rub, Petrolatum, and Tikrit Journal of Pure Science 17 (4) 2012 ISSN: 1813 – 166233
7. Gopalkrishna *et al*, Coconut oil: Chemistry, Production and Its application – a review ,*Indian coconut journal*, CSIR, Mysore, 15-26
8. P. Dawes and I. Haslock.; Visual Analogue Scales, *Ann Rheum Dis.* Aug 1982; 41(4): 434-435
9. Regina fearemonti *et al*, division of plastic surgery DUMC, Durham, NC: A review of scar scales and scar measuring devices: open access journal of plastic surgery. www.eplaty.com June 21.2010.
10. Ahmad sukarhalim *et al*; biologic and synthetic skin substitute: an overview, *Indian j plassurg*, Sep 2010, 43 (suppl) s23-s28.
11. Sujatasrabhi: recent advances in topical wound care; *Indian j of plastic surgery*;2012,may-aug,45(2), 397-387

Source of Support: None Declared
Conflict of Interest: None Declared