

Atypical spinal tuberculosis— extra-osseous extra dural tuberculoma: a retrospective study

Jayant Jain^{1*}, V Shanmugam²

¹Assistant Professor, ²Professor and HOD, Department of Orthopedics, Sree Venkateswara Medical College & Research Centre, Ariyur, Pondicherry, 605102

Email: drjayanthj@rediffmail.com

Abstract

Introduction: Extra-osseous, epidural tuberculoma are extra-pulmonary manifestations of tuberculosis involving the central nervous system. **Material and methods:** We are reporting 5 patients of extra-dural tuberculoma ranging in age from 21yrsto 64 yrs. All patients had varying degree of paraparesis at the time of presentation. Only two patients had spinal tenderness and bone involvement could not be seen in plain radiographs in all five cases. All patients underwent magnetic resonance imaging and only three had no osseous involvement. Exploration through posterior approach by laminectomy with posterior instrumentation done in all cases and the epidural mass had been sent for histo-pathological examination which confirmed the diagnosis. **Results:** All patients healed clinico-radiologically with anti tubercular therapy and been followed for minimum 2 years. **Conclusion:** Extra-dural tuberculoma should be considered as a differential diagnosis in compression myelopathy due to spinal tumor syndrome.

Key Word: Atypical spinal tuberculosis, extra-dural tuberculoma.

*Address for Correspondence:

Dr. Jayant Jain, 302, Faculty Quarters S.V.M.C. & R.C., Ariyur, Pondicherry, 605102.

Email: drjayanthj@rediffmail.com

Received Date: 26/05/2021 Revised Date: 04/06/2021 Accepted Date: 08/07/2021

Access this article online	
Quick Response Code:	Website: www.statperson.com
	Volume 11 Issue 3

INTRODUCTION

The spinal column is involved in less than 1% of all cases of tuberculosis (TB)¹. Paradiscal variety is most common where the familiar picture is of destruction of adjacent vertebral bodies with its intervening disc. Other varieties include the central (central part of vertebral body), anterior type (involving anterior surface of vertebral body) and appendicular type (involving pedicles, lamina, spinous process or transverse process)². In few instances, cord involvement may be secondary to epidural tuberculoma. This atypical spinal tuberculosis presents as compression myelopathy due to a lumbar disc syndrome, spinal tumor syndrome or epidural abscess³. Extra-osseous lesions are difficult to identify on plain

radiographs. Magnetic resonance imaging has been used in all cases having neurological deficit. The diagnosis of tuberculoma has been confirmed by histo-pathological examination.

MATERIAL AND METHODS

This is a retrospective study of five patients of extra-dural tuberculoma. Age of patients varies from 21yrs to 64yrs. All patients were having varying degree of neurological involvement. Neurological assessment was done using Frankel grading. One patient was in Frankel group B, two were in Frankel group C and two in Frankel group D. patients were not having any deformity of spine and two patients were having spinal tenderness. All patients had preoperative investigations including complete blood picture, ESR, CRP, chest X ray and AP & Lat. view of spine. MRI has been done in all patients to evaluate the cause of neurological involvement. In two patients, osseous involvement was there and in three patients there were no osseous involvement. MRI reported moderately defined, diffusely enhanced extra-dural lesions in dorso-lumbar spine compressing and displacing the thecal sac. In one case feature were suggestive of extra-dural abscess (phlegmonous stage) probably complicating a post traumatic hematoma (history of fall 6 wks back). All

patients were planned for exploration, decompression laminectomy through posterior approach and stabilization by posterior instrumentation. Under general anesthesia, patient in prone position, midline incision was given after confirmation by fluoroscopy. Para-spinal muscles retracted on both sides. Titanium polyaxial pedicular screws have been inserted under fluoroscopy control. Total laminectomy performed on affected level according to cord compression in MRI. The extra-dural mass was removed and sent for Histo-pathological examination. In one case a portion of mass anterior to Dura couldn't be removed. After application of connecting rods, postero-

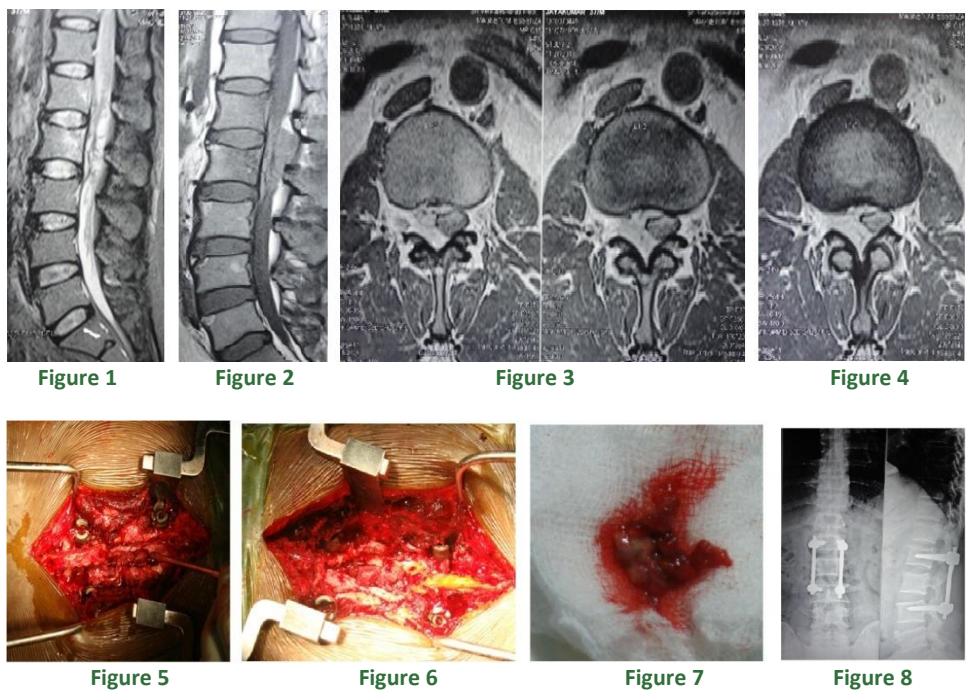
lateral fusion has been done. If the fixation spans more than two levels, a connector has been applied between connecting rods. Mobilization was started in Frankel group D patients on 2nd postoperative day with help of brace and wheel chair mobilization for non-ambulant patients. After histo-pathological confirmation, ATT started according to extended DOTS regime (2 months of intensive phase and 6 months of continuation phase) as recommended by WHO. MRI evaluation has been done at the end of 8 months to decide upon continuation or stoppage of chemotherapy. All patients followed for minimum of two years.

RESULT

All cases healed clinico-radiologically on ATT. In the case where complete excision of extra-dural mass couldn't be done showed clearance of mass in repeat MRI after 8 months of ATT. All patients improved neurologically.

Table 1

Frankel grade pre-operative		Frankel grade post-operative				
A	B	A	B	C	D	E
	1				1	
	2					2
	2					2



Legend:

- Figure 1 & 2: Lesion extending from L1 to L3 vertebrae
- Figure 3 & 4: Mass compressing and displacing the thecal sac
- Figure 5 & 6: Intra-operative picture showing epidural mass compressing the Dura
- Figure 7: Excised epidural mass
- Figure 8: Postoperative radiograph showing post laminectomy status and posterior instrumentation

DISCUSSION

Classical Pott's spine with involvement of two vertebral bodies with the intervening disc with or without paravertebral abscess is readily diagnosed and treated.⁴ Any spinal tuberculosis which does not have typical clinical or radiological features is called Atypical Tuberculosis³. They are uncommon, difficult to diagnose, misdiagnosed and mistreated. The incidence of atypical spinal tuberculosis is 2.1%^{5,6,7}. Extra-osseous epidural tuberculoma has been reported infrequently. In recent years newer diagnostic modalities can detect bony involvement not apparent on plain radiographs⁸. Three patients did not have osseous involvement and presented with compressive myelopathy with radiculopathy (spinal tumor syndrome). The differential diagnosis is neurofibroma, meningioma, lipoma, astrocytoma or other neural tissue tumors⁷. Another differential diagnosis is epidural abscess. Spinal epidural abscess (SEA) is a very rare disease and it occurs at incidence rate of 0.2 to 2.8 cases per 10,000 hospital admissions^{5,9,10}. Predisposing factors involved are spinal surgery, recent trauma, immuno-suppression, distal site infection, intravenous drug use, diabetes mellitus and alcoholism^{11,12,13}. 20% of patients will not have clear predisposing factors¹⁴. SEA is a life threatening disease that can cause neurological deficits due to compressive effect or ischemia. When recognized early and treated appropriately the outcome can be excellent^{4,5,6,15}. Paraplegia due to epidural tumor is not always subjected to exploratory laminectomy thinking of its poor prognosis whereas epidural tuberculoma responds well with decompression laminectomy with anti-tubercular treatment⁴. Hence, it is of paramount importance to do histo-pathological examination for diagnosis rather than relying on clinico-radiological impression alone^{16, 17}. Even the gross appearance during surgery can be deceptive, so histo-pathological confirmation of diagnosis is essential. In our study all patients improved neurologically and recovery was confirmed by MRI.

CONCLUSION

Extra-osseous, extra dural tuberculoma should always be considered in patients of spinal tumor syndrome in

tuberculosis endemic area. Early surgical intervention gives good results.

REFERENCES

1. Mohammad R. Rasouli,1,2 Maryam Mirkoohi,1 Alexander R. Vaccaro,2 Kourosh Karimi Yarandi,1 and Vafa Rahimi-Movaghar. Spinal Tuberculosis: Diagnosis and Management. Asian Spine J. 2012 December; 6(4): 294–308.
2. Tuli SM (2010) Tuberculosis of the skeletal system, 4th edn. Jaypee Publishers, Delhi, p 183
3. Vikas Singh, Ajay Kumar, KR Patond. Extraosseus extradural spinal tuberculosis – A case report. Indian Journal Of Orthopaedics January 2005 Volume 39 : Number 1 : P. 62-63
4. Babhulkar SS, Tayade WB, Babhulkar SK. Atypical spinal tuberculosis. J Bone Joint Surg Br. 1984 Mar;66(2):239-42.
5. Martin RJ, Yuan HA. Neurosurgical care of spinal epidural, subdural, and intramedullary abscesses and arachnoiditis. Orthop Clin North Am. 1996;27:125–36.
6. Naim-ur-Rahman. Atypical forms of spinal tuberculosis. J Bone Joint Surg (Br). 1980; 62: 162-165.
7. Pande KC, Babhulkar SS. Atypical spinal tuberculosis. Clin Orthop. 2002; 398: 67-74.
8. Mantzoros CS1, Brown PD, Demby L. Extraosseous epidural tuberculoma: case report and review. Clin Infect Dis. 1993 Dec;17(6):1032-6.
9. Mackenzie AR, Laing RB, Smith CC, Kaar GF, Smith FW. Spinal epidural abscess: the importance of early diagnosis and treatment. J Neurol Neurosurg Psychiatry. 1998;65:209–12.
10. Chao D, Nanda A. Spinal epidural abscess: a diagnostic challenge. Am Fam Physician. 2002;65(7):1341–6.
11. Soehle M, Wallenfang T. Spinal epidural abscess: clinical manifestations, prognostic factors, and outcomes. Neurosurgery. 2002;51(1):79–87.
12. Vilke GM, Honingford EA. Cervical spine epidural abscess in a patient with no predisposing risk factors. Ann Emerg Med. 1996;27(6):777–80.
13. Rabih O. Darouiche. Spinal Epidural Abscess. review article. N Engl J Med. 2006;355:2012–20.
14. Louis Amy, Fernandes Christopher. Spinal epidural abscess. Can J Emerg Med. 2005;7(5):351–4.
15. Hasengawa K, Hideyuki M et al. Spinal tuberculosis. Clin Orthop. 2002; 403: 100-103.
16. Milnes JN. Spinal compression from isolated epidural tuberculosis. B J Clin Pract 1966;20:219-20
17. Kocen RS, Parsons M. Neurological complications of tuberculosis : some unusual manifestations Q J Med 1970;NS 39:17-30.

Source of Support: None Declared
Conflict of Interest: None Declared