

Assessment of thickness of the temporalis muscle in orthodontic patients with various growth pattern using ultrasound imaging system

Joe Joseph¹, Gokulakrishnan Periakaruppan^{2*}, Arun B Chitharanjan³, P M Venkata Sai⁴

{¹Resident, ³Professor and HOD, Department of Orthodontics and Dentofacial Orthopaedics}

{²Assistant Professor, ⁴Professor and HOD, Department of Radiology}

Sri Ramachandra University, Porur, Chennai-600116, Tamil Nadu, INDIA.

Email: raygokuljournals@gmail.com

Abstract

Introduction: Wolff's law states that, "Every change in the form and function of bone or of their function alone is followed by certain definite changes in their internal architecture, and equally definite alteration in their external conformation, in accordance with mathematical laws." Based on cephalometric values the dentofacial growth pattern has been divided into three namely, average, vertical and horizontal. **Aims and Objectives:** To assess the thickness of temporalis muscle in orthodontic patients with various growth pattern using ultrasound imaging system. **Materials and Method:** The study consisted of 75 subjects undergoing orthodontic treatment in the Department of Orthodontics and Dentofacial Orthopedics, Faculty of Dental Sciences, Sri Ramachandra University. All the subjects were divided in three groups (viz. average, vertical and horizontal growth group) containing 25 patients each. Ultrasonography was used to calculate the thickness of temporalis muscle. The thickness was measured in relaxed and contracted state on both sides. **Results:** It was observe that the thickness of temporalis was more in average growth group in relaxed and contracted state but the difference was not statistically significant. The thickness of temporalis muscle in contracted and relaxed state was more in horizontal growth group but the difference was not statistically significant. The thickness of temporalis muscle in contracted and relaxed state was more in horizontal growth group as compared to vertical group and the difference was also statistically significant. **Conclusion:** The thickness of the temporalis muscle was greatest in horizontal growth pattern, followed by average growth pattern and vertical growth pattern.

Keywords:temporalis muscle, cephalometric values, thickness.

*Address for Correspondence:

Dr. Gokulakrishnan Periakaruppan, Assistant Professor, Department of Radiology, Sri Ramachandra University, Porur, Chennai-600116, Tamil Nadu, INDIA.

Email: raygokuljournals@gmail.com

Received Date: 28/08/2021 Revised Date: 06/09/2021 Accepted Date: 14/10/2021

Access this article online

Quick Response Code:	Website: www.statperson.com
	Volume 11 Issue 4

INTRODUCTION

Wolff's law is an important theory in the field of biodynamics which relates form and function to bone morphology. This law states that, "Every change in the

form and function of bone or of their function alone is followed by certain definite changes in their internal architecture, and equally definite alteration in their external conformation, in accordance with mathematical laws."¹ Under the principles of Wolff's law a relationship has also been defined between bone shape and muscle function^{1,2}. Based on cephalometric values the dentofacial growth pattern has been divided into three namely, average, vertical and horizontal. Opdebeeck and Bell, in 1978, postulated that the stronger, more active muscles of the face are associated with a tendency towards parallelism of the jaws and other features of the short face syndrome³. Many researchers have also suggested that bone shape and structure are closely related to the attached muscle activity^{1,2,3,4}. Recent experimental studies have uncovered a significant correlation between

morphological alterations of bone tissue and changes in mechanical stresses (Goldstein, 1992)⁵.The temporal muscle is broad and fan-shaped. It is situated along the side of the head, occupying the temporal fossa. It originates from the temporal fossa and temporal fascia, passing the zygomatic arch, or cheekbone, before inserting into the mandible's coronoid process. This muscle is found beneath the temporal fascia and accessible on the temples. Unclenching and clenching the jaw contracts this muscle. This muscle controls both retraction and elevation of the mandible or jaw bone.The main action of temporalis is to elevate the mandible, raising the lower jaw. Elevation of the mandible occurs during the closing of the jaws. If only the posterior part contracts, the muscle moves the lower jaw backward. Moving the lower jaw backward causes retraction of the mandible. Retraction of the jaw often accompanies the closing of the jaws.⁶Based on cephalometric values the dentofacial growth pattern has been divided into three namely, average, vertical and horizontal. Thus the present study was undertaken to examine the variation and effects of temporalis muscle thickness on vertical, horizontal and average growth patterns.

AIMS AND OBJECTIVES

To assess the thickness of temporalis muscle in orthodontic patients with various growth pattern using ultrasound imaging system.

MATERIALS AND METHOD

The present study was in the Department of Orthodontics and Dentofacial Orthopedics, Faculty of Dental Sciences, Sri Ramachandra University.Total 75 patients were selected for the study. The patients were divided into

three groups, of 25 subjects each, based on their growth pattern.

Group 1: Average growth pattern (25 subjects)

Group 2: Vertical growth pattern (25 subjects)

Group 3: Horizontal growth pattern (25 subjects)

The selected patients were more than 20 years of age and were without any dental prosthesis and without any history of diseases involving the neuromuscular mechanism.The growth pattern of the patients was evaluated using lateral cephalograms of the patients taken for routine diagnosis prior to orthodontic treatment. Seven angular measurements and four linear measurements were analyzed. The thickness of temporalis muscles was measured bilaterally using a GE LOGIQ P5 machine in the Department of Radiology and Imaging Sciences. A 12 MHz high- resolution linear array transducer was used, oriented perpendicular to the ramus, so as to avoid a distorted image of the muscle thickness. The angle of the transducer was altered until the best echo of the mandibular ramus surface was achieved. Temporalis muscle thickness was measured just in front of the anterior border of hair line.The imaging and the measurement were made bilaterally with the subjects seated upright, with the head in postural rest position. The variation in thickness in both relaxed and contracted states was measured. The measurements were made directly on the screen. The imaging and measurements are performed three times, with an interval of at least five minutes between the scanning and the thickness per side was calculated as the average of the three measurements. The relationship between the muscle thickness with growth pattern, anterior and posterior facial heights are then compared.

RESULTS

Table 1: Comparison of temporalis thickness in average and vertical growth group

	Muscle group	Average	Vertical	P value
Right	Relaxed	6.016±1.3984	5.796±1.1703	0.549
	Contracted	6.588±1.3700	6.548±1.1576	0.912
Left	Relaxed	6.108±1.1972	5.624±0.8038	0.100
	Contracted	6.80±1.203	6.31±0.784	0.091

The thickness of average and vertical growth pattern was compared in both relaxed and contracted states. It was observe that the thickness was more in average growth

group in relaxed and contracted state but the difference was not statistically significant.

Table 2: Comparison of temporalis thickness in average and horizontal growth group

	Muscle group	Average	Horizontal	P value
Right	Relaxed	6.016±1.3984	6.408±1.1941	0.292
	Contracted	6.588±1.3700	7.076±1.0822	0.169
Left	Relaxed	6.108±1.1972	6.392±1.1102	0.389
	Contracted	6.80±1.203	7.07±1.181	0.437

It was observed that the thickness of temporalis muscle in contracted and relaxed state was more in horizontal

growth group. But the difference was not statistically significant.

Table 3: Comparison of temporalis thickness in vertical and horizontal growth group

Muscle group		Vertical	Horizontal	P value
Right	Relaxed	5.796±1.1703	6.408±1.1941	0.007
	Contracted	6.548±1.1576	7.076±1.0822	0.010
Left	Relaxed	5.624±0.8038	6.392±1.1102	0.007
	Contracted	6.31±0.784	7.07±1.181	0.010

The thickness of temporalis muscle in contracted and relaxed state was more in horizontal growth group as

compared to vertical group and the difference was also statistically significant.

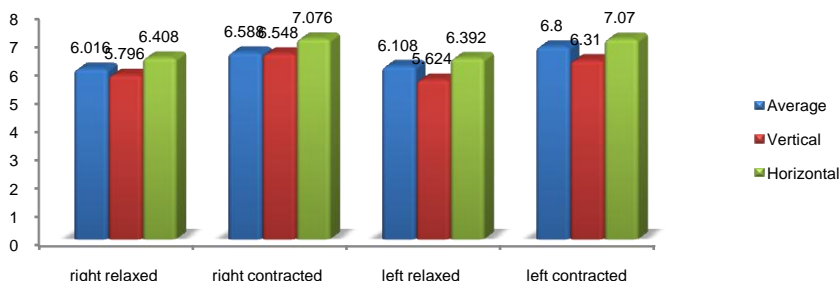


Figure 1: Comparison of temporalis muscle thickness between average, horizontal and vertical growth group

DISCUSSION

The present study was conducted with the objective to study the thickness of temporalis muscle in orthodontic patients with various growth patterns using ultrasound imaging system. The field of orthodontics has made tremendous advances in aspects of diagnosis and treatment planning. Studies have evaluated the dentofacial complex and improved our understanding of the human physiology and its function. The methods like computed tomography (CT), cone beam computed tomography (CBCT), magnetic resonance imaging (MRI), ultrasound etc are highly sophisticated imaging techniques. Computed tomography and cone beam computed tomography are imaging techniques which use ionizing radiation and so they are disadvantageous, magnetic resonance imaging is time consuming and is expensive. Among these techniques, ultrasonography is advantageous because it has no known cumulative biological effects. The efficiency of ultrasonography as an instrument for measuring muscle thickness has been proved in previous studies^{2, 6,7,8,9}. It is accurate, reliable and an inexpensive technique. Thus in the present study ultrasound was used for the measuring the muscle thickness. The patients selected in the present study were over 20 years of age because earlier studies have indicated that there will not be any variation in muscle thickness and stature after the age of 20 years⁷. In this study the muscle thickness of temporalis muscle was measured bilaterally. The measurements were made in

both relaxed and contracted states. As it has been considered that the relaxed muscle thickness has been considered less accurate due to the fact that the relaxed muscle permitted compression by the transducer¹⁰. There was no statistical significance observed in the measurements between left side and right side in both the muscles. Variation was observed in the temporalis muscle thickness among the three groups. Right temporalis muscle thickness in relaxed state (average = 6.016±1.3984mm; vertical = 5.796±1.1703mm; horizontal = 6.408±1.1941mm) and contracted state (average = 6.588±1.3700mm; vertical = 6.548±1.1576mm; horizontal = 7.076±1.0822mm) showed that the thickness was more in horizontal growth pattern compared to average and vertical growth patterns. Same results were observed for left temporalis muscle in both relaxed (average = 6.108±1.1972mm; vertical = 5.624±0.8038mm; horizontal = 6.392±1.1102mm) and contracted (average = 6.80±1.203mm; vertical = 6.31±0.784mm; horizontal = 7.07±1.181mm) states. Temporalis muscle thickness in horizontal and vertical group was compared with average group the difference was not statistically significant. But when variation in the thickness between the vertical and horizontal groups was compared it showed significant difference. The results of the present study showed that there was a significant variation in masticatory muscle thickness among average, vertical and horizontal growth patterns. Right and left sides did not show much variation

in muscle thickness. Inter-individual differences in the cross-section of the masseter muscle may be due to a variable number of muscle fibers, variation in fiber size, or both¹⁰. The results were similar to previous studies done by Kiliaridis and Kalebo¹⁰, Satiroglu *et al*², Benington *et al*³, Raadsheer *et al*⁷ etc. who observed a strong correlation between temporalis muscle thickness and facial morphology.

CONCLUSION

The thickness of the temporalis muscle was greatest in horizontal growth pattern, followed by average growth pattern and vertical growth pattern.

REFERENCES

1. Frost HM. Wolff's law and bone's structural adaptations to mechanical usage: an overview for clinicians. *Angle Orthod* 1994; 64(3):175-188.
2. Şatiroğlu F, Arun T, Işık F. Comparative data on facial morphology and muscle thickness using ultrasonography. *Eur J Orthod* 2005; 27:562-567.
3. Benington PCM, Gardener JE, Hunt NP. Masseter muscle volume measured using ultrasonography and its relationship with facial morphology. *Eur J Orthod* 1999; 21:659-670.
4. Kubota M, Nakano H, Sanjo I, Satoh K, Sanjo T, Kamegai T, Ishikawa F. Maxillofacial morphology and masseter muscle thickness in adults. *Eur J Orthod* 1998; 20:535-542.
5. *Illustrated Anatomy of the Head and Neck*, Fehrenbach and Herring, Elsevier, 2012, page 98
6. Castelo PM, Gavião MBD, Pereira LJ, Bonjardim LR. Masticatory muscle thickness, bite force, and occlusal contacts in young children with unilateral posterior crossbite. *Eur J Orthod* 2007; 29:149-156.
7. Raadsheer MC, Kiliaridis S, van Eijden TMGJ, van Ginkel FC, Prahl-Andersen B. Masseter muscle thickness in growing individuals and its relation to facial morphology. *Archs oral Biol.* 1996; 41(4):323-332.
8. Esformes JI, Narici MV, Maganaris CN. Measurement of human muscle volume using ultrasonography. *Eur J Appl Physiol* 2002; 87:90-92.
9. Bertram S, Brandlmaier I, Rudisch A, Bodner G, Emshoff R. Cross-sectional characteristics of the masseter muscle: an ultrasonographic study. *Int J Oral Maxillofac Surg* 2003; 32:64-68.
10. Kiliaridis S, Kalebo P. Masseter muscle thickness measured by ultrasonography and its relation to facial morphology. *J Dent Res* 1991; 70(9):1262-1265.

Source of Support: None Declared
Conflict of Interest: None Declared