

Absence of Musculocutaneous Nerve Along With Accessory Head of Biceps Brachii

U.W. Mane^{1*}, S. R. Pandhare²

¹Assistant Professor, Department of Anatomy, Government Medical College, Nanded (MS), INDIA.

²Assistant Professor, Department of Anatomy, Government Medical College, Nagpur (MS), INDIA.

*

Corresponding Addresses:

dr.uddhav.mane@gmail.com

Research Article

Abstract: Musculocutaneous nerve is one of the terminal branches of lateral cord of brachial plexus. This nerve is responsible for innervation of flexor compartment of arm and for cutaneous innervation on lateral surface of forearm. Its absence has been described previously but its real prevalence is unknown. A case of absence of Musculocutaneous nerve along with presence of accessory head of biceps brachii was observed during routine undergraduate dissection of right arm of a male cadaver. In this case the muscles which are usually innervated by musculocutaneous nerve were innervated by median nerve.

Medical concerns related with these variations include, anaesthetic blocks, surgical approaches, interpreting tumour or traumatic nerve compressions having unexplained clinical symptoms. There is also possibility of injury to the muscular branches of median nerve in arm by surgeon as usually this nerve does not give branches in arm. Hence this case report was studied and reported.

Key words: Musculocutaneous nerve, Median Nerve, accessory head of biceps brachii, brachial plexus, lateral cord

Introduction: The musculocutaneous nerve is one of the terminal branches of the lateral cord of the brachial plexus in the axilla. It derives its fibers especially from 5th and 6th cervical nerves. It diverges laterally from lateral root of median nerve to lie between the coracobrachialis muscle and axillary artery; at this position it gives off one or more branches to the coracobrachialis muscle, and then penetrates the muscle to lie between the biceps and brachialis, and thereafter is purely cutaneous, passing downward between biceps and brachialis muscle to emerge lateral to the tendon of biceps and continue into the forearm as the lateral cutaneous nerve of forearm (Figure 1). A case of absent musculocutaneous nerve from the lateral cord of the brachial plexus was encountered during

routine undergraduate dissection. The median nerve took over the innervation of the anterior compartment muscles of the upper arm.

This report will assist clinicians and the surgeons by pointing out anatomical anomalies associated with the origin of musculocutaneous nerve and variations in the origin of muscular branches to the anterior compartment muscles of the upper arm. Hence this case was studied and reported.

Materials and Methods:

During routine undergraduate dissection hours, we observed an unusual and interesting variation of musculocutaneous nerve of right arm of a male cadaver. The specimen was carefully dissected, cleaned under water, and then dried well with acetone. Later that was painted with fabric red colour paint, and photographed.

Observations:

A case of absence of Musculocutaneous nerve along with presence of accessory head of biceps brachii was observed during routine undergraduate dissection of right arm of a male cadaver. The muscles which are usually innervated by musculocutaneous nerve were innervated by median nerve in this case. Two muscular branches arose from median nerve and innervated biceps brachii and brachialis muscles. Branch of median nerve which supplied brachialis continued as lateral cutaneous nerve of forearm. The coracobrachialis muscle was

supplied by one small nerve twig that arose from lateral root of median nerve. [Figure 2 & 3]

The accessory head of bicep brachii muscle was also noted in the same limb. It arose

from fascia under pectoralis major muscle. [Figure 4]

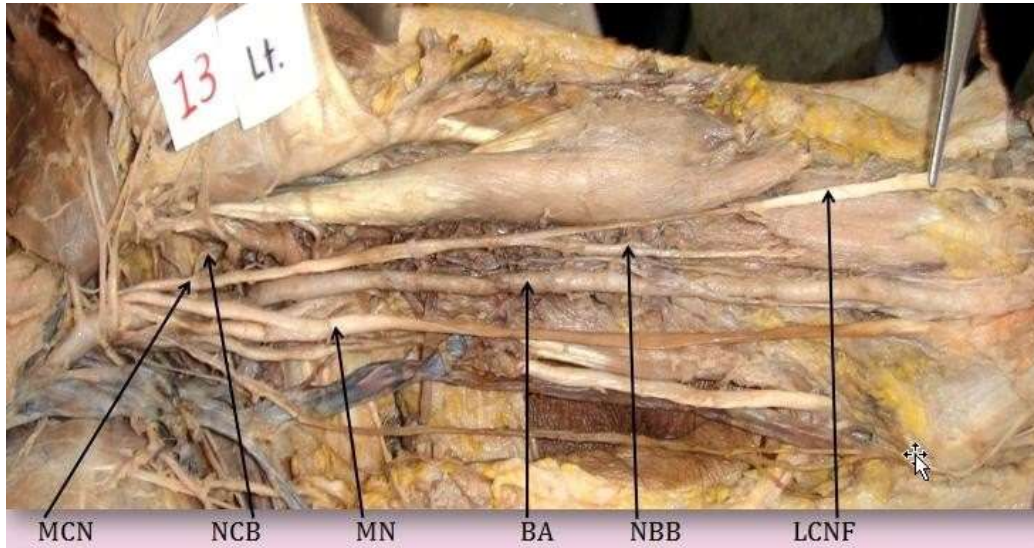


Figure 1: Normal Musculocutaneous & Median nerves in left arm of same cadaver.

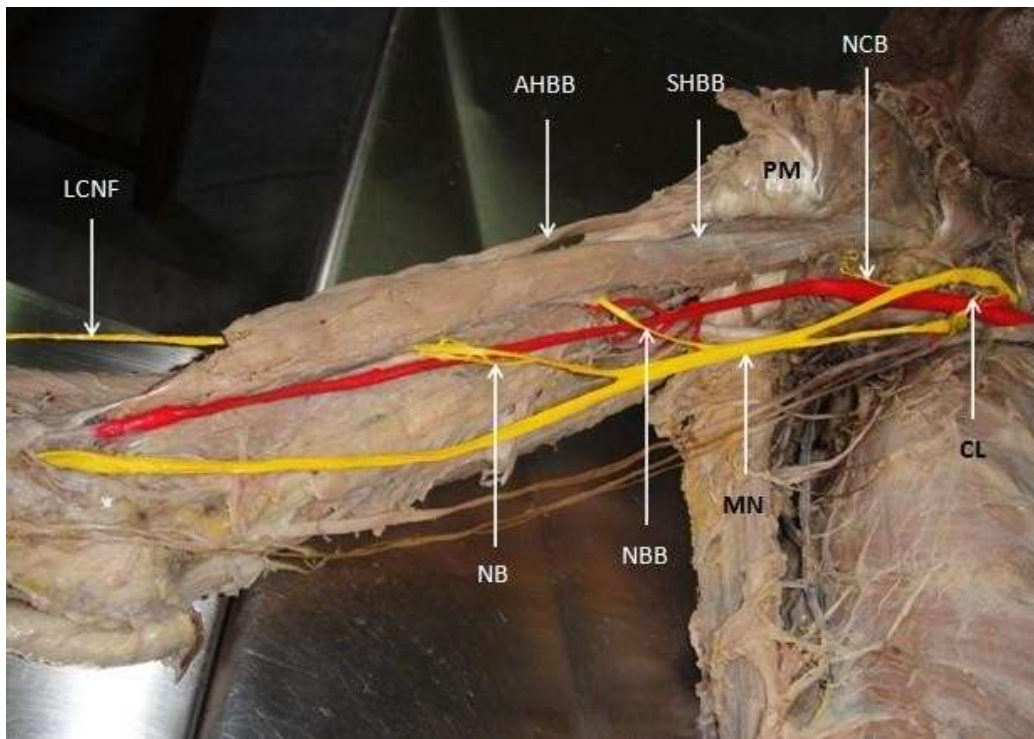


Figure 2: Median nerve with unusual muscular branches in right arm of the same cadaver

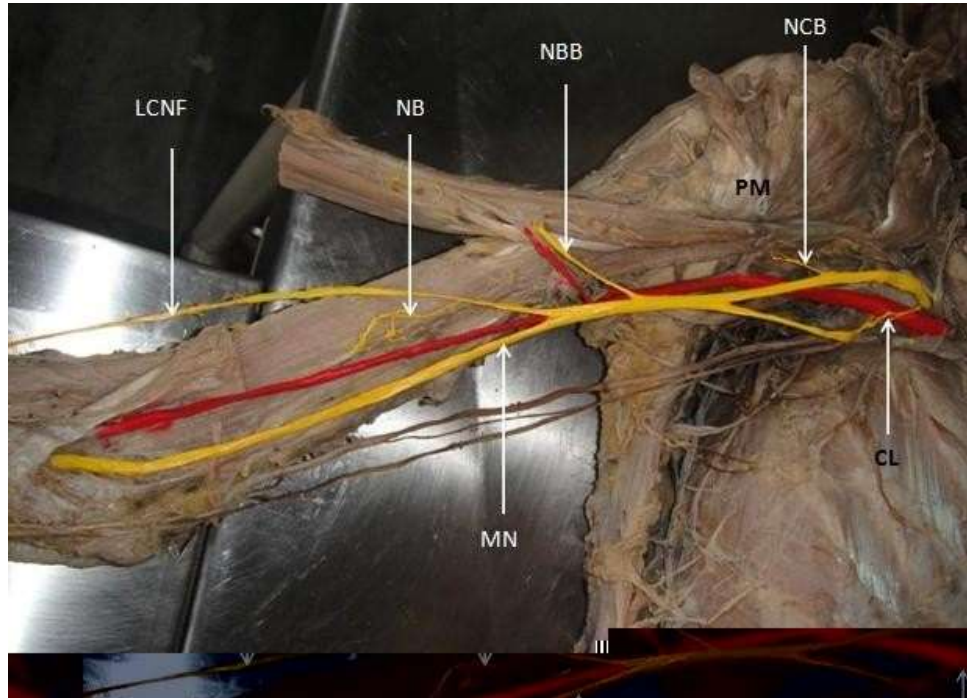


Figure 3: Nerve to brachialis continues as lateral cutaneous nerve of forearm between biceps brachii and brachialis

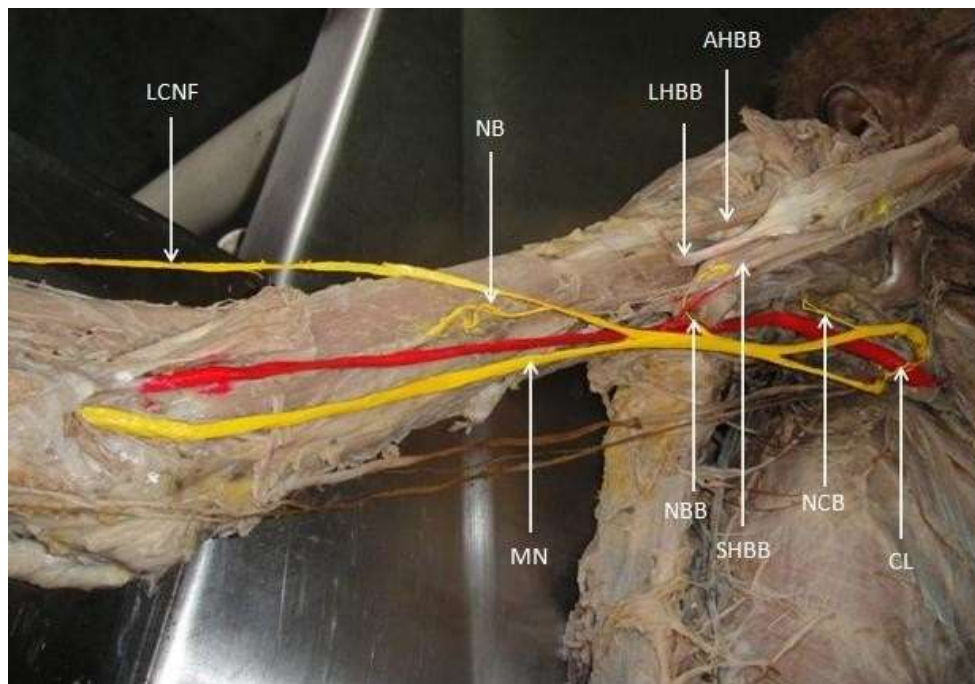


Figure 4: Reflected biceps brachii muscle with three heads (Long, Short & Accessory)

Abbreviations:

MN: Median Nerve

NCB: Nerve to Coracobrachialis

NBB: Nerve to Biceps Brachii

NB: Nerve to Brachialis

LCNF: Lateral Cutaneous Nerve of Forearm

CL: Communicating Loop between medial and lateral cord over axillary artery

LHBB: Long Head of Biceps Brachii

SHBB: Short Head of Biceps Brachii

AHBB: Accessory Head of Biceps Brachii

PM: Pectoralis Major
BA: Brachial Artery

Discussion:

Anomalies of the brachial plexus formation and its terminal branches are not uncommon and Buch-Han-sen (1955)¹ observed these variations in 65.3% of cases. The musculocutaneous nerve is a motor and sensory peripheral nerve arising from lateral cord of brachial plexus. The musculocutaneous nerve has frequent variations (Gray's Anatomy)². It may run behind coracobrachialis or adhere for some distance to the median nerve and pass behind biceps. Some fibers of median nerve may run in musculocutaneous nerve, leaving it to join their trunk; less frequently the reverse occurs, and median nerve sends a branch to musculocutaneous nerve. Occasionally it supplies pronator teres and replace radial branches to the dorsal surface of thumb. The musculocutaneous nerve was reported to be absent or not separating from median nerve. (Holinshed³, Prasad rao⁴, Beheiry⁵, Arora and Dhingra R.⁶, Satheesha Nayak⁷, Rajendrakumar virupakshi⁸,) but its real prevalence is unknown. It fails to get separate from Median nerve, and the latter therefore gives off the muscular branches that should arise from the musculocutaneous nerve. In present case also the same finding was observed. Median nerve supplied to coracobrachialis, brachialis and biceps brachii. Also there was accessory head of bicep brachii was seen attached to the fascia of pectoralis major. Many of authors mentioned about this variations of biceps, that presence of third head or accessory head. It arose from bicipital groove, middle of shaft of humerus (most common type), pectoralis major. Sometimes long head of biceps get doubled. (Holinshed)⁹.

Conclusion:

Above mentioned findings of median nerve innervating the flexors of arm should be considered when a high median nerve paralysis takes place in the axilla or proximal arm in a patient presenting with weakness of forearm

flexion and supination. Similarly, this variation gives explanation for weakness of arm flexors in patients with thoracic outlet syndrome and median nerve affection. Further medical concerns related with these variations include, anaesthetic blocks, surgical approaches, interpreting tumour or traumatic nerve compressions having unexplained clinical symptoms. There is also possibility of injury to the muscular branches of median nerve in arm by surgeon as usually median nerve does not give branches in arm.

Acknowledgment:

Author is like to thanks Head of department, senior teachers, colleagues and all staff members.

References:

- [1] Buch-Han-sen (1955)¹ Buch-Hansen K. Uber varietaten des nervus medianus und des nervus musculocutaneous und deren beziehungen. *Anat Anz* 102:187–203, 1955.
- [2] Susan Standring. Gray's anatomy. In: Neil RB, Jeremiah CH, Patricia C, David J, Alan RC, Vishy M, Michael AG, Richard LMN, Caroline BW, The anatomical basis of clinical practice. 40th Ed., London, Churchill Livingstone Elsevier. 828-829, 2008.
- [3] W. Henry Holinshed. *Anatomy for surgeons: vol.3 (The Back And Limbs)*. 3rd Ed., Philadelphia, Harper & Row. 366, 1982.
- [4] Prasada Rao PV, Chaudhary SC. Communication of the musculocutaneous nerve with the median nerve. *East Afr. Med. J.* 77: 498–503, 2000.
- [5] Beheiry. Anatomical variations of the median nerve distribution and communication in the arm. *Folia Morphol.* 63, 3: 313-318, 2004.
- [6] Arora and Dhingra R. Absence of musculocutaneous nerve and accessory head of biceps brachii: a case report. *Indian Journal of Plastic Surgery.* 38, 2: 144-146, 2005.
- [7] Satheesha Nayak. Absence of musculocutaneous nerve associated with clinically important variations in the formation, course and distribution of the median nerve – a case report. *Neuroanatomy.* 6: 49-50, 2007.
- [8] Rajendrakumar virupakshi. Absence of musculocutaneous nerve in the left axilla. *International Journal of Anatomical Variations.* 2: 140–142, 2009.
- [9] W. Henry Holinshed. *Anatomy for surgeons: vol.3 (The Back And Limbs)*. 3rd Ed., Philadelphia, Harper & Row. 354, 1982.