

Limberg Transposition Flap in the Treatment of Pilonidal Sinus – Our Experience

K. Senthil Kumar*, R. Anantharamakrishnan**

*Assistant Professor, **Associate Professor, Department of General Surgery, Chettinad Hospital and Research Institute, Kelambakkam, Kanchipuram District, Tamilnadu-603103, INDIA.

*Corresponding Address:

drsenthil_psg@yahoo.co.in, rasm2003@yahoo.com

Research Article

Abstract: Introduction: Pilonidal sinus disease is a common surgical condition usually seen in young adults. Although several techniques have been described each one has its own merits and demerits. This study was carried out to evaluate the advantages of primary excision and Limberg flap reconstruction in the management of pilonidal sinus disease. **Materials and Method:** This study was done in a surgical unit at a tertiary care hospital, Chettinad Hospital and Research Institute from June 2009 to June 2012. During the study period 25 patients were enrolled and the duration of operation, postoperative pain, duration of hospital stay, postoperative complications, time until to return to work and recurrence rate were noted. **Results:** In our study the mean age of presentation was 23 years with male predominance. Average operating time was 81 minutes with postoperative hospital stay of 6 days. Of all the complications, flap necrosis and seroma formation were common with no recurrence in any of our patients during the one year follow up period. **Conclusion:** When compared with the available data Limberg flap is very effective for pilonidal disease with short hospital stay, earlier healing and shorter time off-work, low complication rates, low recurrence rates. The surgery can be mastered easily. The results of this study favour rhomboid excision and Limberg flap reconstruction for pilonidal disease over excision with primary closure.

Keyword: Karydakias flap, Limberg rhomboid flap, Marsupialization, Modified Bascom procedure

Introduction

Pilonidal sinus in latin means “nest of hairs”. It is a common condition usually seen in young adults in the gluteal cleft. The incidence of the disease is 26 per 100000¹ people. The disease is more common in middle east countries. Men are more commonly affected. The pathogenesis of the disease is the frictional forces generated in the natal cleft tend to drive hairs subcutaneously and they generate foreign body reaction. Multiple subcutaneous sinuses and abscess formation occurs following secondary infection. The management of pilonidal sinus disease remains controversial and gold standard treatment modality has yet to be established. Recurrence of the disease is the main problem. The techniques developed to avoid recurrence generally involves a flap procedure that achieves primary closure away from midline and obliterates the natal cleft.

Treatment options available are Excision of the sinus tracts with primary closure or secondary healing, Modified Bascom procedure, Karydakias flap, Limberg rhomboid flap. In this study, we present our experience with Limberg flap in the management of pilonidal sinus.

Material and Methods

A prospective study was conducted in Department of General Surgery in Chettinad Hospital and Research Institute from June 2009 to June 2012. 25 patients who were treated for pilonidal sinus by Limberg flap was included in the study. Preoperative investigations were done for patients presented with symptoms of pilonidal sinus disease. MRI of gluteal region was done to all patients to see the extent of sinus tract and to look for associated inflammation. Procedure was explained to the patient and consent was obtained and preoperative preparation was done.

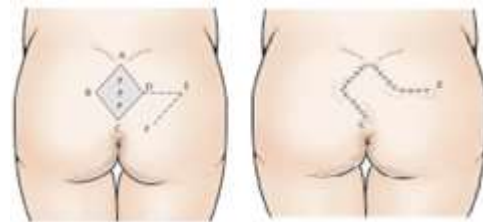


Figure 1, Figure 2: Schematic Representation of Limberg Flap surgery

Patients were placed in prone position with pillows under the chest and lower abdomen and rhombus shaped area of excision including all sinus openings along with flap was mapped with a skin marker. The line A–C is drawn and its length measured. C should be adjacent to the perianal skin and A is placed so that all diseased tissue can be included in the excision. The line B–D transects the midpoint of A–C at right-angles and is 60 per cent of its length. The flap is planned so that D–E is a direct continuation of the line B–D and is of equal length to the incision B–A, to which it will be sutured after rotation. E–F is parallel to D–C, and of equal length. After

rotation, it will be sutured to A–D (Fig 1 and Fig 2). All the sinus tracts were excised en block deep till the pre-sacral fascia in the midline and gluteal muscles laterally (Fig 3 and Fig 4). Dissection should be restricted to presacral fascia to avoid bleeding.

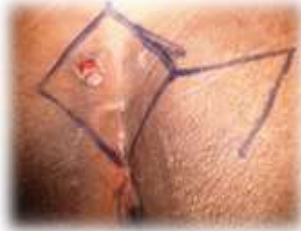

Figure 3: Preoperative marking of flap

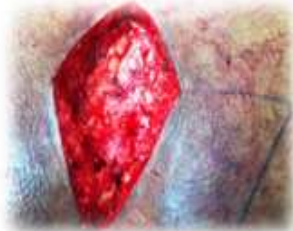

Figure 4: Excision of Rhomboid area including sinus

A flap was then fashioned from gluteal region incorporating the skin, subcutaneous fat and gluteal fascia (Fig 5 and Fig 6) and stitched in place with 2-0 vicryl in two layers after vacuum drain was placed down to the presacral fascia. The skin was closed with interrupted 2-0 polypropylene sutures (Fig:7).

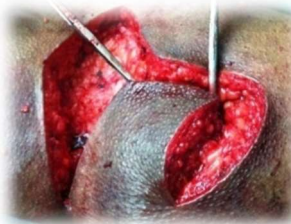

Figure 5: Gluteal Flap Fashioned

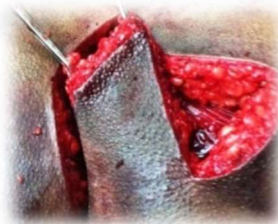

Figure 6: Flap rotated to fill the midline defect

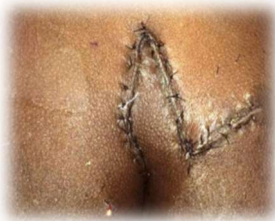

Figure 7: Limberg Flap sutured..

Patient was nursed in lateral/prone position for 24 hours. Patients received i.v. antibiotics cefaperazone with sulbactam and metrogyl postoperatively for 5-6 days. Wound was inspected daily from 3rd postoperative day. Drains were removed on the 6-7th postoperative day and patient was discharged at 7th postoperative day. Patients were advised to come for follow up on 15th postoperative day and sutures were removed on that visit. Patients were advised to maintain hygiene and keep the area clean. Follow up done in outpatient clinic at one, six and twelve months post surgery. The operative time, post operative pain, wound complications, hospital stay and recurrence rate were recorded.

Result

Table 1: Demographic Characteristics, Operative Time, Pain Score and Duration of Hospital Stay in all patients

Characeristics	Total(N=25)
Age	23.3 Years
Male	17 (68%)
Female	8 (32%)
Operative Time	81.4 Mins
Pain Score (Vas)	4.08
Postoperative Hospital Stay	6 Days
Suture Removed On	15 th Pod

In our study the mean age of presentation was 23 years and 68% of the study population were male. Average operating time taken for the procedure was around 80 minutes. Patients were kept in the hospital for six days and sutures of the wound were removed on 1 5th postoperative day during the follow up visit.

Table 2: The Distribution of Complications and Recurrence Rate

Complication	Total (N=25)
Haematoma	Nil
Seroma	1
Flap Necrosis At Tip	2
Wound Infection	Nil
Wound Gaping	Nil
Total Flap Necrosis	Nil
Recurrence	Nil

Among the 25 patients in the study only one patient developed seroma and two patients developed flap necrosis at the tip for 1cm which was managed conservatively by intravenous antibiotics and daily dressing.

Discussion

Pilonidal sinus was first described by Hodges. It is a chronic, inflammatory disease with intractable symptoms. Though, many surgical options like Excision and packing, Excision and primary closure, Marsupialization, and Flap techniques are available, no technique fulfils all of the following criteria. Less financial cost, simple to perform, short hospital stay, minimal pain, rapid healing, short term wound care and a low recurrence rate. Since the source of the disease is natal cleft and deep intergluteal sulcus, flap techniques were developed which flattened the natal cleft, lateralized and fulfilled the defect without tension whereas in primary excision it is impossible. Urhan *et al*¹ and Bozkurt and Tezel² reported that in primary closure technique, operating time was short but had significant postoperative morbidity like wound infection rate - 32.7%, dehiscence rate - 50% and recurrence rate - 12%. In our study, the hospital stay for patients treated with Limberg flap was 5 days, which was similar to 5.5 days as reported by Rossi *et al*³ and 5.7 days as reported by Singh *et al*³. Healing period was 15 days which was also similar to results achieved by

Eryilmaz *et al*⁴. Wound infection rate was 0% in our study whereas in literature an infection rate range of 1.5–6%⁵ with Limberg flap was reported. Recurrence is the main problem associated with all surgeries which ranged from 21.4% to 100% for incision and drainage, 5.5%–33% for excision and open packing, 8% for marsupialisation, 3.3%–11% for Z plasty⁶. Literature has documented a recurrence rate of 4%, 3.1% and 2.91%, associated with Limberg flap, in different series of Katsoulis *et al*⁹, Mentis *et al*⁷ and Akin *et al*⁸ respectively. But the main disadvantage of the limberg flap procedure is the unfavourable cosmetic appearance post operatively due to flattening of the natal cleft.

Conclusion

The advantages of Limberg flap reconstruction are:

1. Flattens the natal cleft with a large well-vascularised pedicle that can be sutured without tension.
2. Midline dead space and scar is avoided.
3. Useful in complex sinuses with multiple pits where radical excision leaves large defect.
4. Easy to perform, learn and design.
5. Useful in recurrent pilonidal disease.
6. Reduces hospital stay and time to resume normal activities.
7. Low complications and recurrence rates.

Hence the results of this study favour rhomboid excision - Limberg flap reconstruction for pilonidal disease over excision and primary closure.

Acknowledgement

We acknowledge the help extended by the faculty and technicians of the departments of General

Surgery, Pathology and Radiology in conducting the study. The study is a self funded study.

References

1. Urhan MK, Kucukel F, Topgul K, Ozer I, Sari S. Rhomboid excision and Limberg flap for managing pilonidal sinus: results of 102 cases. *Dis Colon Rectum*. 2002;45: 656–9.
2. Bozkurt MK, Tezel E. Management of pilonidal sinus with the Limberg flap. *Dis Colon Rectum*. 1998;41:775–7. Marks J, Harding KG, Hughes LE, Riberio CD. Pilonidal sinus excision-healing by open granulation. *Br J Surg*. 1985;72:637–40
3. McLaren CA. Partial closure and other techniques in pilonidal surgery: an assessment of 157 cases. *Br J Surg*. 1984;71:561–2.
4. Eryilmaz R, Sahin M, Alimoglu, O, Dasiran, F. Surgical treatment of sacrococcygeal pilonidal sinus with the Limberg transposition flap. *Surgery*. 2003;134:745–9.
5. Hodgson WJ, Greenstein RJ. A comparative study between Z-plasty and incision and drainage or excision with marsupialisation for pilonidal sinuses. *Surg Gynecol Obstet*. 1981;153:842–4.
6. Ersoy E, Onder Devay A, Aktimur R, Doganay B, Ozdogan M, Gundogdu RH. Comparison of the short-term results after Limberg and Karydakis procedures for pilonidal disease: Randomized prospective analysis of 100 patients. *Colorectal Dis*. 2008;11:705–10.
7. Mentis O, Bagci M, Bilgin T, Ozgul O, Ozdemir M. Limberg flap procedure for pilonidal sinus disease: results of 353 patients. *Langenbecks Arch Surg*. 2008 Mar;393(2):185–9. Epub 2007 Sep 22.
8. Akin M, Gokbayir H, Kilic K, Topgul K, Ozdemir E, Ferahkose Z. Rhomboid excision and Limberg flap for managing pilonidal sinus: long-term results in 411 patients. *Colorectal Dis* 2008 Nov;10(9):945–8. doi: 10.1111/j.1463-1318.2008.01563.. Epub 2008 May 3.
9. Katsoulis IE, Hibberts F, and Carapeti EA. Outcome of treatment of primary and recurrent pilonidal sinuses with the Limberg flap. *Surgeon*. 2006 Feb;4(1):7–10, 62.