

# Cryptorchidism - A Case Report

Sadiqali Abbasali Syed<sup>1\*</sup>, N. G. Herekar<sup>2</sup>

{<sup>1</sup>Assistant Professor, <sup>2</sup>Professor and Head} Department of Anatomy, Government Medical College, Miraj, Sangli (MS) INDIA.

\*Corresponding Address:

[sadiqalisyed3@gmail.com](mailto:sadiqalisyed3@gmail.com)

## Case Report

**Abstract:** Cryptorchidism is a condition in which one or both the testes have not passed down the scrotal sac. It may be unilateral or bilateral. It is categorized as true undescended testes in which testes are present in the normal path of descent, and ectopic testes in which testes are present at abnormal site. Common complications of Cryptorchidism are testicular cancer, sub fertility, testicular torsion, and inguinal hernia. In a male cadaver, the right testis was found in the inguinal region. It was dissected properly and the scrotal ligament was observed to be attached to the pubic region. The left testis was descended normally. On doing pathological examination of both testes only senile degenerative changes were observed. Patient had lived a life for 78 years without complication and was died of acute peritonitis.

**Keywords:** cryptorchidism, testicular cancer, cadaver, scrotal ligament, acute peritonitis.

### 1. Case Report

During dissection of inguinal region, in Department of Anatomy, Government Medical College Miraj, in a male cadaver, the right testis was found in inguinal region. (Figure 1)

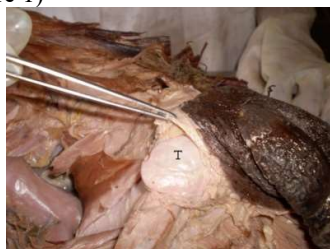

Figure 1: Right testis in inguinal region T- Right Testis

The position of testis was in the inguinal canal, obliquely placed above pubic crest and lower pole of testis had descended through superficial inguinal ring. The testis was compressed anteroposteriorly, with epididymis seen on lateral side of testis. We dissected the region to see scrotal ligament.

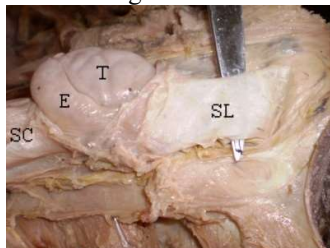


Figure 2: Right testis and its scrotal ligament T-Testis, E- Epididymis, SC- Spermatic cord, SL- Scrotal ligament

It was seen as a large band extending from lower pole of testis and was attached to pubic region. The

scrotal sac was opened and was found empty, containing only loose connective tissue.

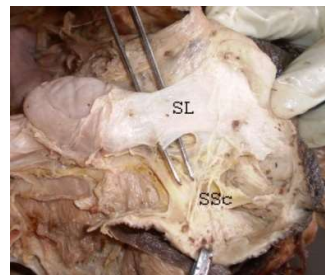


Figure 3: Right Scrotal Sac, SL- Scrotal ligament, SSC - Scrotal Sac

Careful dissection of opposite inguinal region was carried out. The left testis was found to be descended normally and present within scrotal sac.

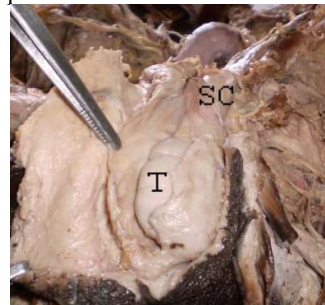


Figure 4: Left testis and Scrotal sac, Sc- Spermatic cord, T- Testis

Both testes along with spermatic cords were removed and measurements were taken.

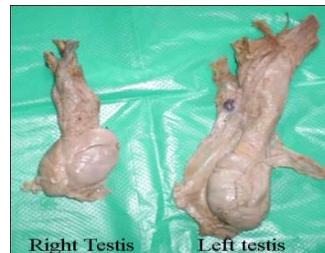


Figure 5: Right and left testis with spermatic cord after removal from body

The measurements were as follows-

#### **Right side-**

Length of spermatic cord- 4.5 cms, weight of testis- 7.1 gms. Dimensions of the testis- Length 2.7 cms, breadth- 1.6 cms, anteroposterior thickness – 2.2 cms

#### **Left side-**

Length of spermatic cord- 7.5 cms, weight of testis- 9.6 gms. Dimensions of the testis- Length 2.2 cms, breadth- 0.7 cms, anteroposterior thickness – 1.8 cms.

Both testes were sent for histopathological examination. According to the report in both testes, senile degenerative changes were seen.

## **2. Discussion**

The testis develops in relation to the lumbar region of posterior abdominal wall. During fetal life they gradually descend into scrotum. During descent; they reach the iliac fossa in third month and at deep inguinal ring in seventh month of intra uterine life. They pass through the inguinal canal during seventh month and are in scrotum by end of eight month. The descent of testis occurs in two phases and both phases are under control of somewhat different factors [2], first phase - Movement across the abdomen to the entrance of inguinal canal i.e deep inguinal ring. This phase is influenced by anti Mullarian hormone secreted by Sertoli cells. Second phase in which testis move through the inguinal canal in the scrotum. During this phase normal attachment of gubernaculum plays important role in complete descent of testes in scrotal sac. In present case, the scrotal ligament, which is remnant of gubernaculum, on right side is attached to the pubic region. So this might be the cause for undescended testis on right side. The incidence of undescended testis among men is approximately one in 1,000 to one in 2,500 [5]. It has been well documented that men with the history of undescended testis have 10 times higher chance of development of testicular cancer than the normal and the incidence goes on increasing with advance in age [4]. To prevent testicular cancer, prophylactic orchidectomy is done in early age. It is also reported that 20 % of testicular tumor with unilateral cryptorchidism occurs on the side which is normally descended [3]. In present case patient had a life for 78 years and according to histopathological

report, there were only senile degenerative changes and no carcinomatous change seen in both testes. So the role of prophylactic orchidectomy done to prevent testicular cancer in adults is questionable. Torsion of testis and inguinal hernia are common complications of undescended testis. From medical history of patient obtained from hospital data and also from findings of dissection of abdomen, patient had not suffered from any of such disease and had not undergone any previous surgery. Men with undescended testis have lower sperm count, poorer quality of sperms and lower fertility rates than men with normal testis [1]. In present case we don't get any family history as the patient was a beggar and was sent to our department by police as an unclaimed body. The cause of death of the patient obtained from hospital record was acute pneumonitis.

## **3. Conclusions**

1. Gubernaculum plays important role in descent of testis. Abnormal attachment of gubernaculum will cause undescended testis.
2. Men with unilateral cryptorchidism can live normal life with full development of secondary sexual characters without malignant transformation in undescended testis.
3. Further research should be done on the role of prophylactic orchidectomy in adult cryptorchid in prevention of testicular cancer.

## **Bibliography**

1. Bailey and love's, short practice of surgery, 24<sup>th</sup> edition, page no. 1404.
2. Kolon TF, Patel RP, Huff DS (2004). "Cryptorchidism: diagnosis, treatment, and long-term prognosis". *Urol. Clin. North Am.* 31(3):469–80, viii– ix. doi:10.1016/j.ucl.2004.04.009. PMID 15313056.
3. Martin DC. Malignancy in the cryptorchid testis. *Urol Clin North Am.* 1982;9:371–6.
4. Moller H, Cortes D, Engholm G, Thorup J (1998). "Risk of testicular cancer with cryptorchidism and with testicular bio. PMC: 28664. psy: cohort study". *BMJ* 317 (7160): 729. PMID 9732342.
5. Pinczowski D, McLaughlin JK, Lackgren G, Adami HO, Persson I. Occurrence of testicular cancer in patients operated on for cryptorchidism and inguinal hernia. *J Urol.* 1991;146:1291–4.